



UNIVERSITÀ
DEGLI STUDI
DI PADOVA

Master I livello Unipd in Tecniche di RM cardiaca

Masse cardiache

Dott. Stefano da Pozzo



- ✓ When cardiac MRI is indicated?
- ✓ How can I perform a cardiac MRI?
- ✓ What are the main cardiac masses?
- ✓ What information should I write in a report?
- ✓ Clinical cases



When cardiac MRI is indicated?

Current cardiac imaging techniques in the detection of cardiac masses:



When cardiac MRI is indicated?

Current cardiac imaging techniques in the detection of cardiac masses:

- ✓ First level: - Transthoracic echocardiography



When cardiac MRI is indicated?

Current cardiac imaging techniques in the detection of cardiac masses:

- ✓ First level: - Transthoracic echocardiography

- ✓ Second level: - Transthoracic echocardiography with echo contrast
 - Transesophageal echocardiography

- ✓ Third level: - Computed Tomography
 - Magnetic Resonance Imaging
 - PET



When cardiac MRI is indicated?

Current cardiac imaging techniques in the detection of cardiac masses:

- ✓ First level: - Transthoracic echocardiography

- ✓ Second level: - Transthoracic echocardiography with echo contrast
 - Transesophageal echocardiography

- ✓ Third level: - Computed Tomography
 - Magnetic Resonance Imaging
 - PET

	Advantages	Limitations
TTE	<ul style="list-style-type: none"> • Widely available/portable • Accurate/real-time imaging • Tumor size/shape/mobility/location 	<ul style="list-style-type: none"> • Poor echogenicity in 30% of patients • No tissue characterization • Poor evaluation of pericardium/extracardiac structures
TEE	<p>Advantages = those of TTE; Better than TTE in:</p> <ul style="list-style-type: none"> • Defining tumor attachment and tumor extension • Detecting cardiac thrombi • Evaluation of pericardium and extracardiac structures 	<ul style="list-style-type: none"> • Semi-invasive procedure • Evaluation of pericardium/extracardiac structures may be insufficient • No tissue characterization
CT	<ul style="list-style-type: none"> • Non-invasive • High-spatial resolution • Possibility of multiplanar reconstruction • Tumor size/shape/location • Accurate information on tumor extent and vascularity • Tissue characterization to a limited extent 	<ul style="list-style-type: none"> • Radiation exposure • Iodinated contrast material required
MRI	<ul style="list-style-type: none"> • Non-invasive • High-spatial and temporal resolution • Multiplanar imaging capability • Large field of view • Tumor size/shape/mobility/location • Accurate information on tumor extent and vascularity • Tissue characterization to a certain extent 	<ul style="list-style-type: none"> • Absolute and relative contraindications (pacemaker, intracranial vascular clips) • Claustrophobia



When cardiac MRI is indicated?

TTE-TEE

Localization, Size, Mobility,
Evaluation of infiltration
by malignant tumors,
Hemodynamic consequences

Differential diagnosis
(mimics, artifacts)

Tissue characterization:
edema, fibrous tissue,
fatty tissue, calcium
deposits



When cardiac MRI is indicated?

CT

Localization, Size, Mobility,

Evaluation of infiltration

by malignant tumors,

Hemodynamic consequences

Differential diagnosis

(mimics, artifacts)

Tissue characterization:

vascularization, edema,

fibrous tissue, fatty tissue,

calcium deposits

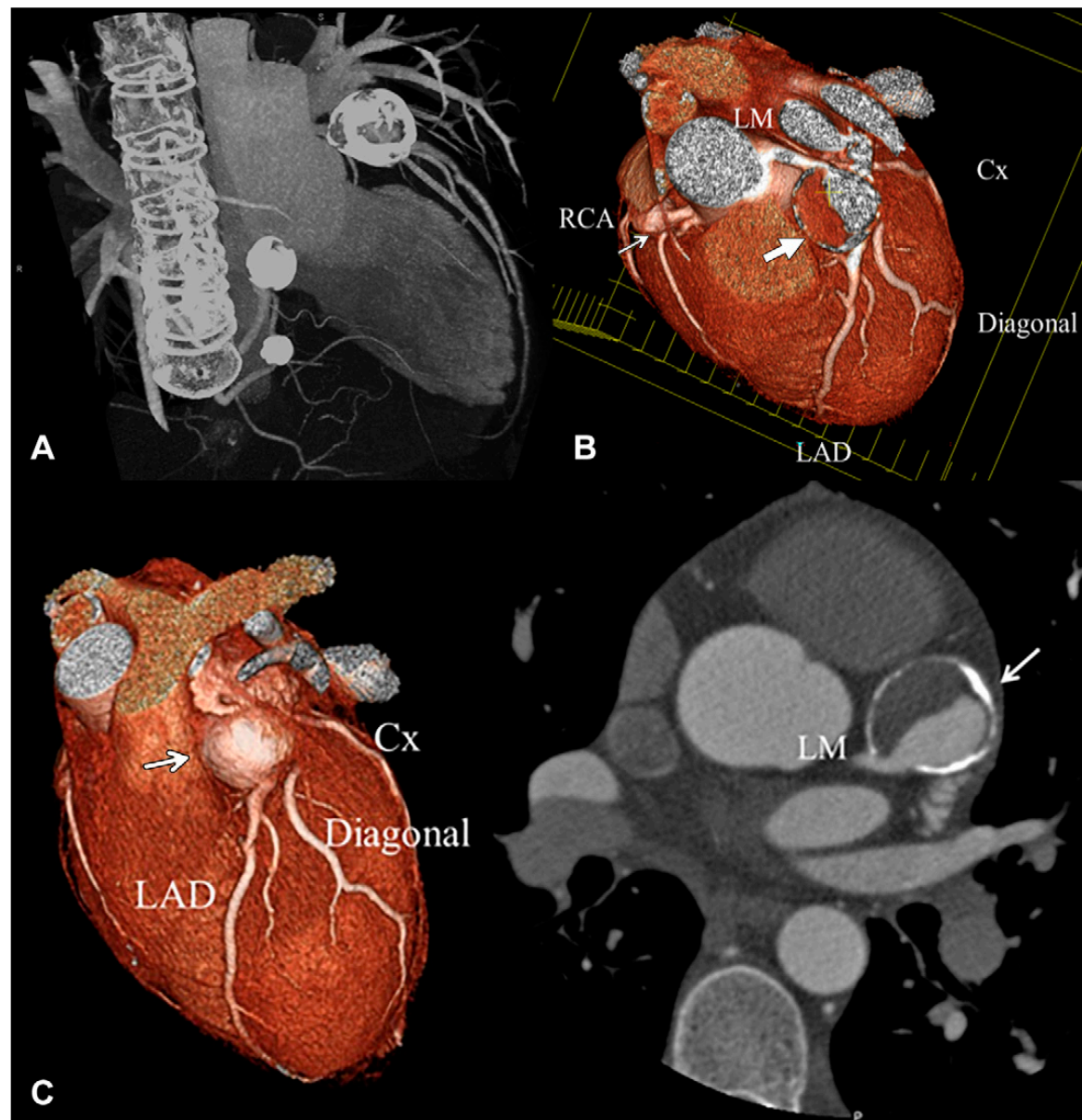
Why CT?

Image size: 700 x 700
View size: 1400 x 1400
S 50605606 (41 y, 40 y)
Cardiac Cardio_Retrospettico (Adult)
Cardio_Retrospettico
1099




Uncompressed
Thickness: 5.10 mm Location: -152.63 mm

22/11/22, 11:01:29
Made In Horos



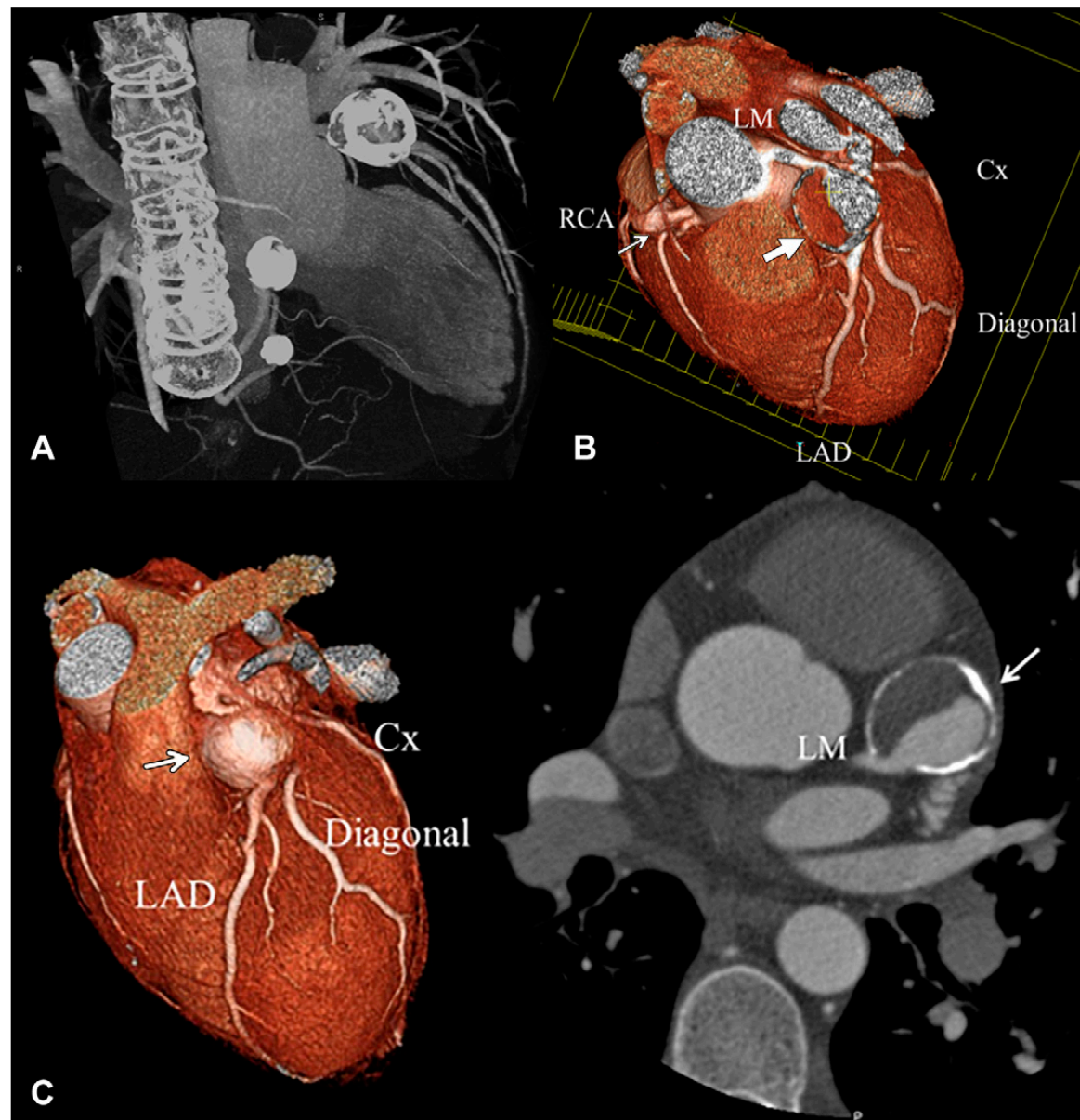
Why CT?

Image size: 700 x 700
View size: 1400 x 1400
S 50605606 (41 y, 40 y)
Cardiac Cardio_Retrospettico (Adult)
Cardio_Retrospettico
1099



Uncompressed
Thickness: 5.10 mm Location: -152.63 mm

22/11/22, 11:01:29
Made In Horos





When cardiac MRI is indicated?

MRI

Localization, Size Mobility,
Evaluation of infiltration
by malignant tumors,
Hemodynamic consequences

Differential diagnosis
(mimics, artifacts)

Tissue characterization:
vascularization, edema,
fibrous tissue, fatty tissue,
calcium deposits

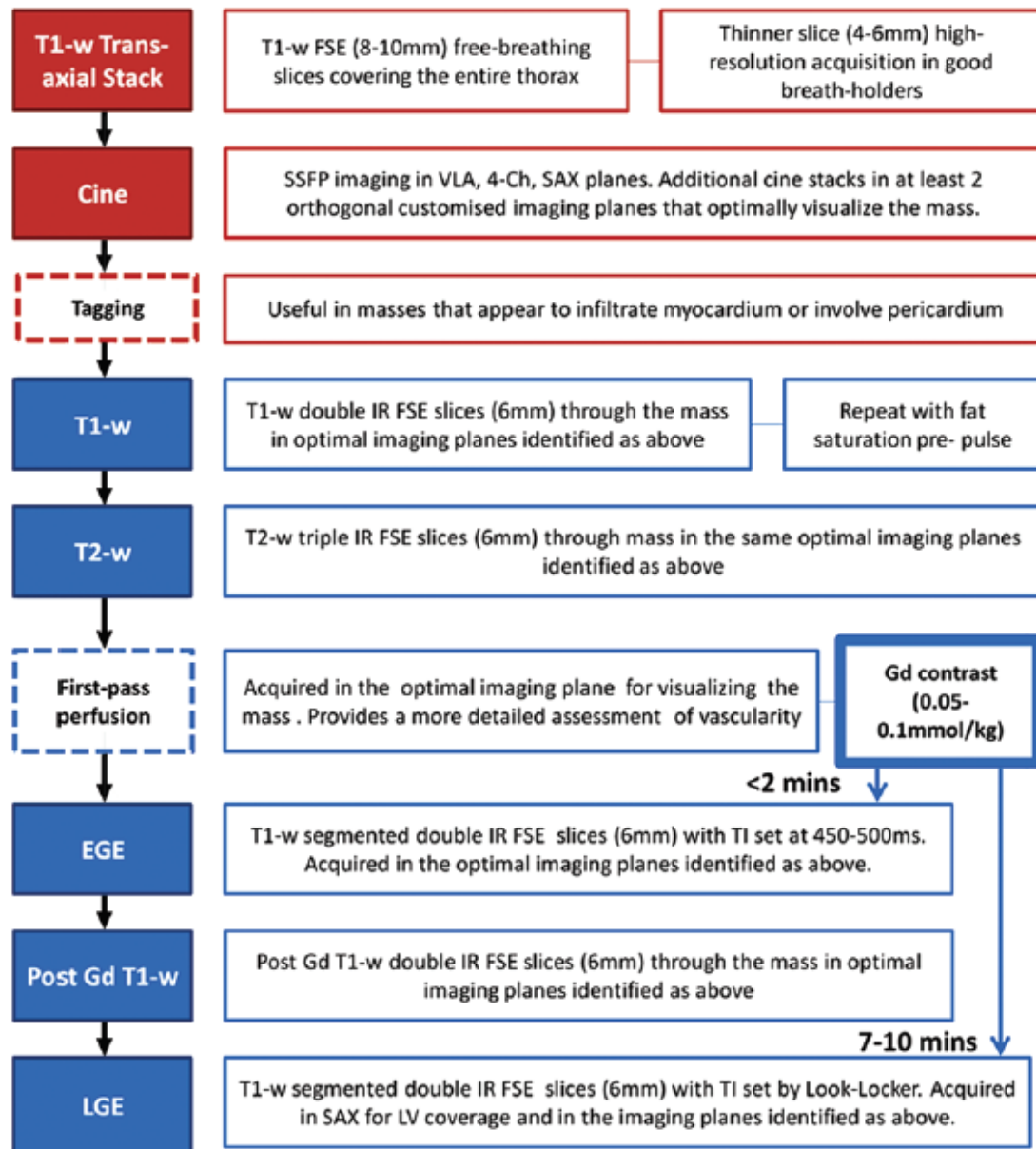


**Mass
localization**

**Tissue
characterization**



How can I perform a cardiac MRI?





What is missing???

CMR pulse sequence	Cine bSSFP	Cine bSSFP	T1FSE	T2FSE	First pass perfusion	Examples	CMR pulse sequence	EGE	LGE	T1 mapping	T2 mapping	T2* mapping				
Image <i>Case example MAC</i>						Myxoma 	Image <i>Case example MAC</i>						 			
Assessment and reporting	<ul style="list-style-type: none"> - Presence and number - Size - Localization - Hemodynamic consequences - Invasive growth - Pericardial effusion - SI of the mass 	<ul style="list-style-type: none"> - SI of the mass - Hypointense - Isointense - Hyperintense Fat-containing lesions bright	<ul style="list-style-type: none"> - SI of the mass - Hypointense - Isointense - Hyperintense Fluid-containing lesions bright	<ul style="list-style-type: none"> - Contrast enhancement of the mass Highly-vascularized lesions bright			Assessment and reporting	<ul style="list-style-type: none"> - Contrast enhancement of the mass Highly-vascularized lesions bright	<ul style="list-style-type: none"> - Contrast enhancement of the mass and pattern - Homogeneous - Heterogeneous 	T1 relaxation time (ms) of the mass	T2 relaxation time (ms) of the mass	T2* relaxation time (ms) of the mass	Sarcoma 			
Discriminating features	(More often) malignant: Poorly defined Intramyocardial Multiple lesions Inhomogeneous, central necrosis Pericardial effusion Invasive growth (More often) benign: Well defined Intracavitary Mobile Stalk	Hyperintense: Lipoma Recent hemorrhage Melanoma Isointense: Myxoma Fibroelastoma Hamartoma Paraganglioma Rhabdomyoma Fibroma Lymphoma Sarcoma	Hyperintense: Myxoma Lipoma Hamartoma Paraganglioma Angiosarcoma Rhabdomyosarcoma Isointense: Fibroelastoma Lymphoma	Hyperintense: Hemangioma Hamartoma Paraganglioma Angiosarcoma Rhabdomyosarcoma Isointense: Fibroma Thrombus Calcification Melanoma	Hyperintense: Hemangioma Hamartoma Paraganglioma Angiosarcoma Rhabdomyosarcoma Isointense: Fibroma Thrombus Calcification Melanoma	Lipoma 	Discriminating features	Hypointense: Thrombus is black with long inversion time (>350 ms)	Intense: Fibroma Heterogeneous: Myxoma Hamartoma Paraganglioma Most malignant masses	Benign mass: Myxoma: ↑ Fibroelastoma: ↑ ↑ Lipoma: ↓ ↓ Rhabdomyoma: = ↑ Fibroma: = Hamartoma: ↑ Paraganglioma: ↑	Benign mass: Myxoma: ↑ Fibroelastoma: ↑ ↑ Lipoma: ↑ ↑ Rhabdomyoma: ↑ Fibroma: = Hamartoma: ↑ Paraganglioma: ↑	Benign mass: Thrombus: ↓ ↓	Malignant mass: Sarcoma: ↑ Liposarcoma: ↓ ↓ Lymphoma: ↑ Metastases: ↑ Melanoma*: ↓	Malignant mass: Sarcoma: ↑ Lymphoma: ↑ Metastases: ↑ Melanoma: ↑	Tumor-like mass: Old thrombus: ↑ New thrombus: ↑ Cyst: ↑ ↑ Caseous calcification: ↓ ↓	
Example <i>Different cases</i>																



T1 AND T2 MAPPING

CMR pulse sequence	Cine bSSFP	Cine bSSFP	T1FSE	T2FSE	First pass perfusion	Examples	CMR pulse sequence	EGE	LGE	T1 mapping	T2 mapping	T2* mapping	
Image <i>Case example MAC</i>						Myxoma 	Image <i>Case example MAC</i>						
Assessment and reporting	<ul style="list-style-type: none"> - Presence and number - Size - Localization - Hemodynamic consequences - Invasive growth - Pericardial effusion - SI of the mass 	<ul style="list-style-type: none"> - SI of the mass - Hypointense - Isointense - Hyperintense Fat-containing lesions bright	<ul style="list-style-type: none"> - SI of the mass - Hypointense - Isointense - Hyperintense Fluid-containing lesions bright	<ul style="list-style-type: none"> - Contrast enhancement of the mass Highly-vascularized lesions bright			Assessment and reporting	<ul style="list-style-type: none"> - Contrast enhancement of the mass Highly-vascularized lesions bright	<ul style="list-style-type: none"> - Contrast enhancement of the mass and pattern - Homogeneous - Heterogeneous 	T1 relaxation time (ms) of the mass	T2 relaxation time (ms) of the mass	T2* relaxation time (ms) of the mass	
Discriminating features	(More often) malignant: Poorly defined Intramyocardial Multiple lesions Inhomogeneous, central necrosis Pericardial effusion Invasive growth (More often) benign: Well defined Intracavitary Mobile Stalk	Hyperintense: Lipoma Recent hemorrhage Melanoma Isointense: Myxoma Fibroelastoma Hamartoma Paraganglioma Rhabdomyoma Fibroma Lymphoma Sarcoma	Hyperintense: Myxoma Lipoma Hamartoma Paraganglioma Rhabdomyoma Recent hemorrhage Cyst Sarcoma Metastases Isointense: Fibroelastoma Lymphoma	Hyperintense: Hemangioma Hamartoma Paraganglioma Angiosarcoma Rhabdomyosarcoma			Discriminating features	Hypointense: Thrombus is black with long inversion time (>350 ms)	Intense: Fibroma Heterogeneous: Myxoma Hamartoma Paraganglioma Most malignant masses	Benign mass: Myxoma: ↑ Fibroelastoma: ↑ ↑ Lipoma: ↓ ↓ Rhabdomyoma: = ↑ Fibroma: = Hamartoma: ↑ Paraganglioma: ↑	Benign mass: Myxoma: ↑ Fibroelastoma: ↑ ↑ Lipoma: ↑ ↑ Rhabdomyoma: ↑ Fibroma: = Hamartoma: ↑ Paraganglioma: ↑	Benign mass: Thrombus: ↓ ↓	Sarcoma
Example <i>Different cases</i>			Hypointense: Thrombus Cyst Calcification Metastases	Hypointense: Fibroma Thrombus Calcification Melanoma	Hemangioma 	Lipoma 	Example <i>Different cases</i>			Tumor-like mass: Old thrombus: ↑ New thrombus: ↑ Cyst: ↑ ↑ Caseous calcification: ↓ ↓			



Il T1 mapping basso permette al cardiologo e al radiologo di:

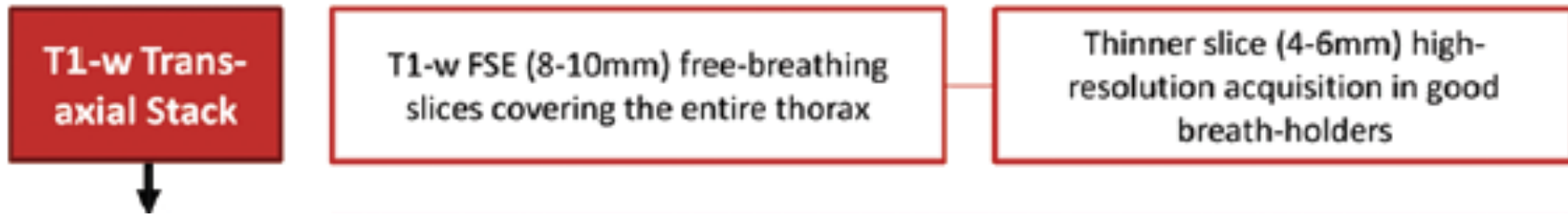
- **Confermare la natura lipidica:** differenzia in modo assoluto il lipoma da altre masse cardiache non adipose.
- **Escludere fibromi o tumori fibrotici:** le lesioni fibrose presentano valori di T1 nativo spiccatamente elevati (opposti al lipoma).
- **Escludere trombi o metastasi:** i trombi mostrano generalmente valori di T1 intermedi o alti, a seconda della loro datazione.
- **Superare i limiti anatomici:** permette di identificare piccoli lipomi infiltrati in strutture complesse (come i muscoli papillari) dove le classiche sequenze di soppressione del grasso possono fallire a causa di artefatti da volume parziale.



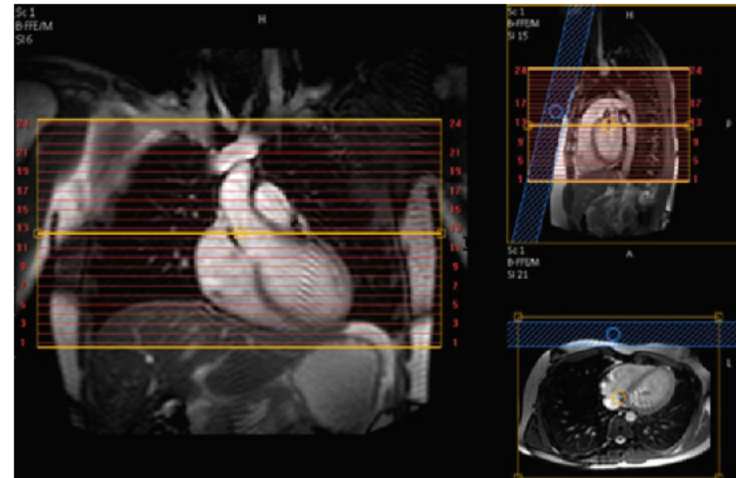
Il tempo di rilassamento T_2 è direttamente correlato al contenuto di acqua libera nei tessuti. I suoi valori sono utili per:

- **Differenziazione tra tumore e trombo:** I trombi recenti hanno in genere tempi di T_2 ridotti rispetto al miocardio normale, mentre la maggior parte dei tumori presenta valori di T_2 marcatamente più elevati.
- **Caratterizzazione dei tumori:** Lesioni ricche di fluidi (es. cisti) o tessuti edematosi/infiammatori mostrano tempi di T_2 prolungati. Inoltre, valori estremamente bassi aiutano a identificare le componenti lipidiche (es. lipomi).
- **Distinzione tra benigno e maligno:** Sebbene i valori di T_2 varino ampiamente per i diversi tipi istologici, la loro combinazione con il mapping T_1 e il Late Gadolinium Enhancement (LGE) fornisce informazioni decisive.
- **Follow-up terapeutico:** Permette di monitorare l'evoluzione di una massa nel tempo o l'eventuale risposta a trattamenti antinfiammatori e chemioterapici.

How can I perform a cardiac MRI?



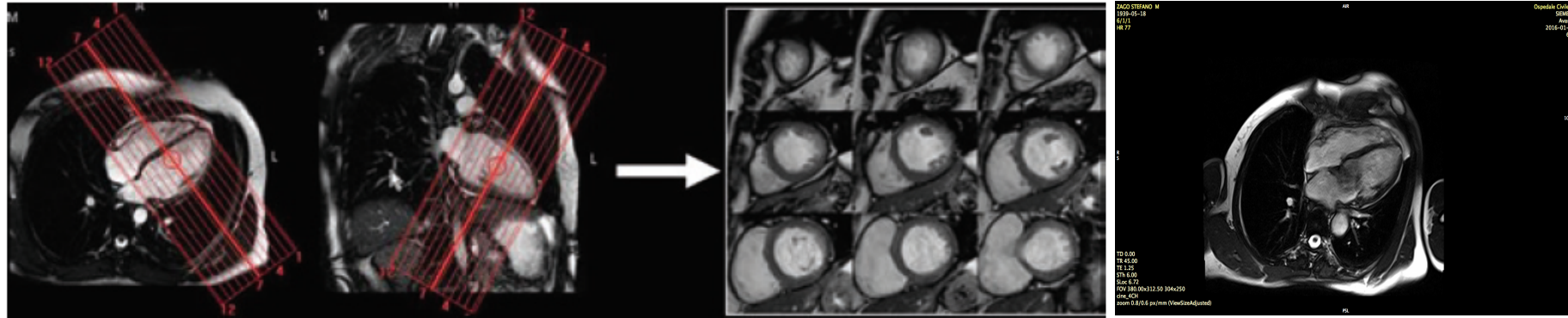
- Transaxial stack of T1-weighted images, covering the entire thorax.
- Rapid overview of the anatomy and tumor localization for the subsequent planning of targeted imaging planes.
- Free-breathing single-shot fast spin-echo (FSE) method (pulse sequence parameters: repetition time msec/echo time msec, 2000/20; flip angle, 90° ; section thickness, 8–10 mm, no gap; typically 16–20 sections; field of view, 320–400 mm; matrix, 256 x 256).



How can I perform a cardiac MRI?

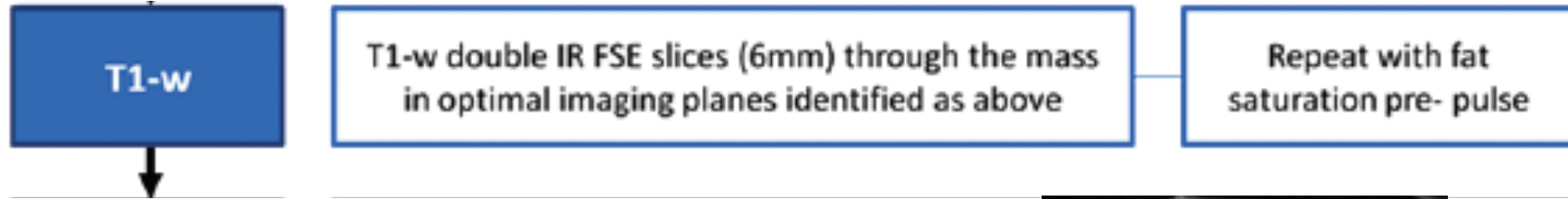
Cine

SSFP imaging in VLA, 4-Ch, SAX planes. Additional cine stacks in at least 2 orthogonal customised imaging planes that optimally visualize the mass.

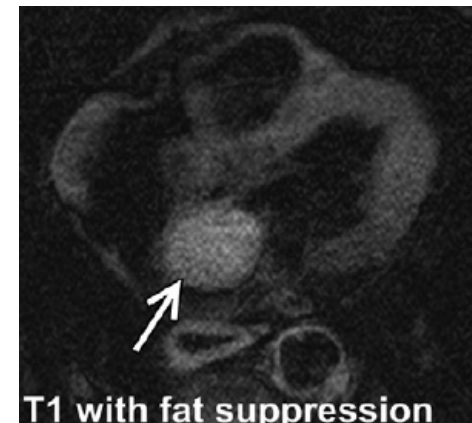
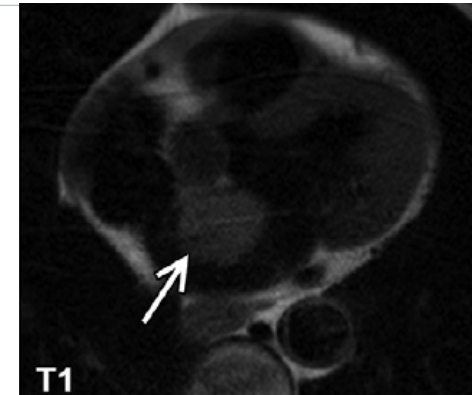


- To confirm location, morphology, mobility, functional consequences of a cardiac mass.
- Standard long axes and a short axis stack to provide full coverage of both ventricles with contiguous sections of 8 mm thickness.
- In addition, non-standard imaging planes to visualize the anatomy and extent of a tumor.
- Steady-state free-precession (SSFP) sequence (pulse sequence parameters: 3.2/1.6; flip angle, 60; section thickness, 8 mm, no gap; sensitivity encoding factor 31.7—2.0; 30—50 phases per cardiac cycle; field of view, 320—400 mm; matrix, 192 x 192).

How can I perform a cardiac MRI?



- With and without a fat saturation pre-pulse.
- T1-weighted images after the intravenous injection of gadolinium-based contrast agent for further tissue characterization: strong contrast enhancement on postcontrast T1-weighted images is more suggestive of a malignant, highly vascular lesion.
- Targeted black-blood T1-weighted FSE images (example pulse sequence parameters: 1000/40; flip angle, 90; section thickness, 6—8 mm, no gap; matrix, 512 x 512).

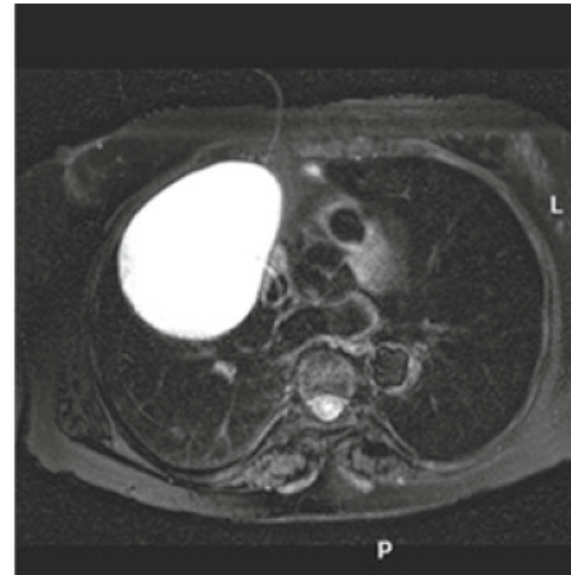


How can I perform a cardiac MRI?

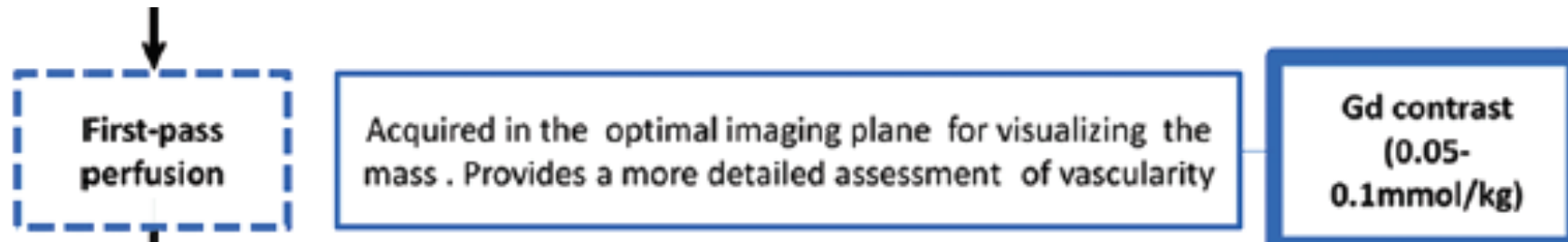
T2-w

T2-w triple IR FSE slices (6mm) through mass in the same optimal imaging planes identified as above

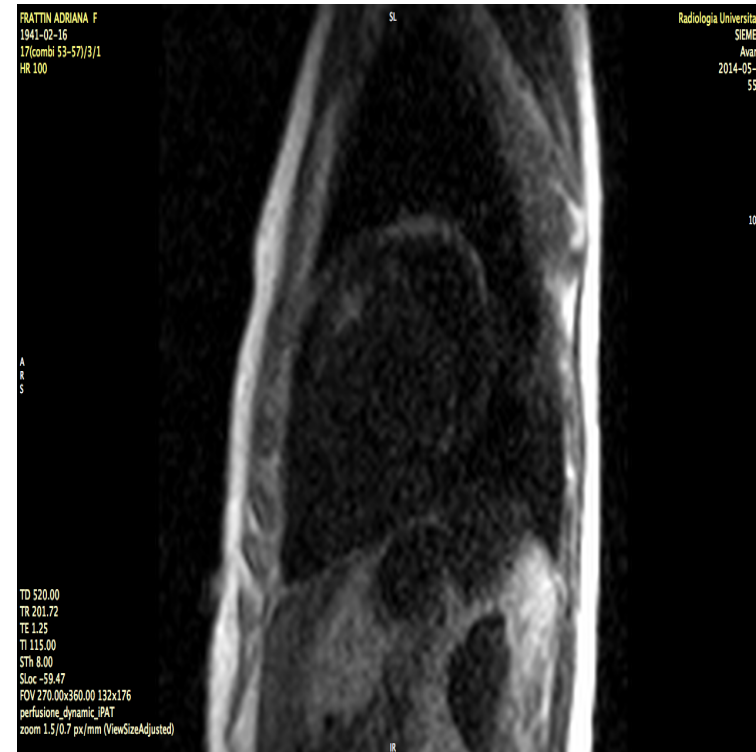- Prior to the administration of contrast material, T2- weighted images should be acquired.
- To detect regions of edema or liquefactive necrosis, which have high signal intensity, or regions of coagulative necrosis, which have low signal intensity.
- Breath hold T2-weighted FSE images, preferably triple inversion recovery with blood and fat suppression (example pulse sequence parameters: 2000/100; flip angle, 90° ; inversion time, 160 msec; section thickness, 6—8 mm, no gap; matrix, 192 x 192)



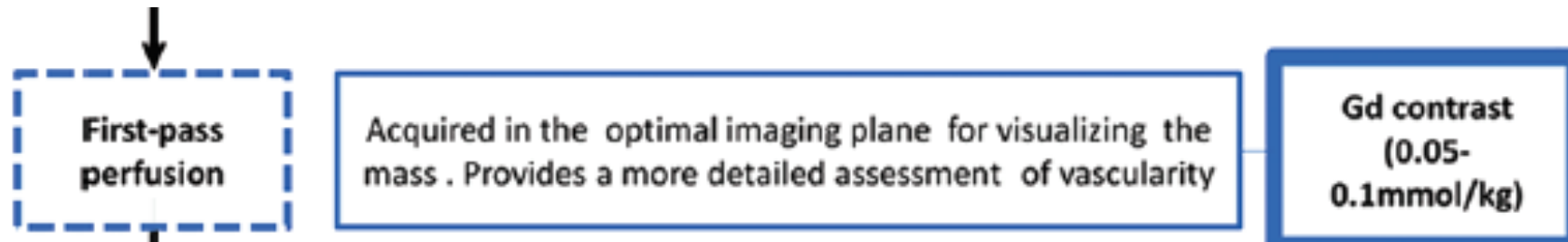
How can I perform a cardiac MRI?



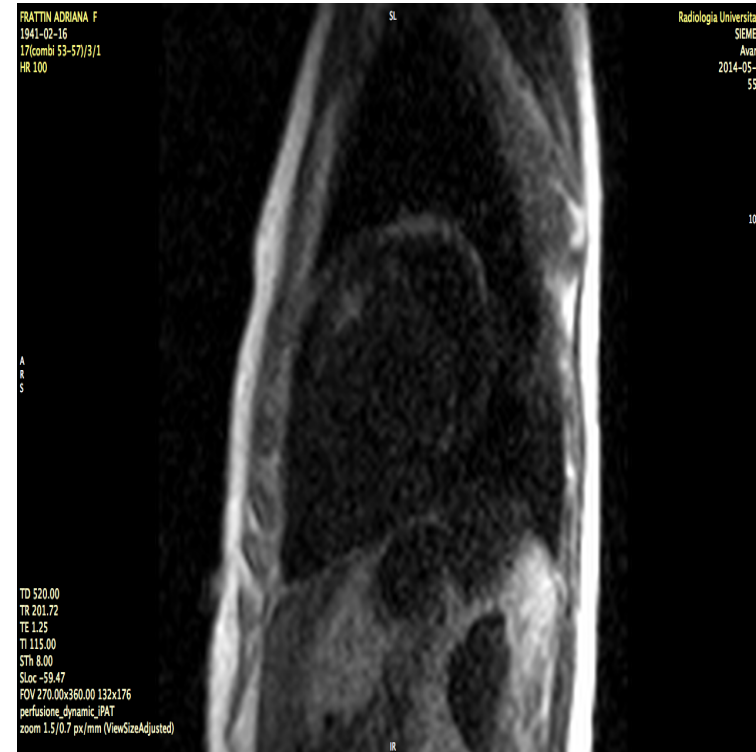- A standard rest perfusion sequence with 0.05—0.1 mmol/kg of gadolinium-based contrast agent can help determine the vascularity of a suspected cardiac mass.
- Vascular tumors will show signal intensity enhancement during the arterial phase, as opposed to nonvascular structures, such as thrombus.



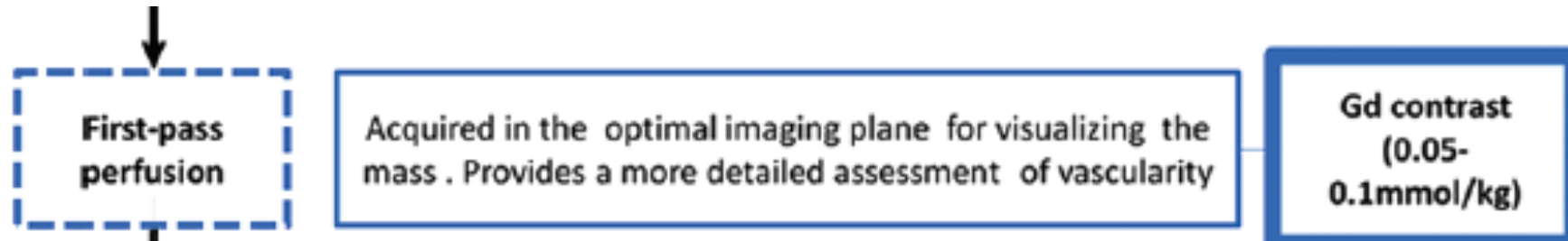
How can I perform a cardiac MRI?



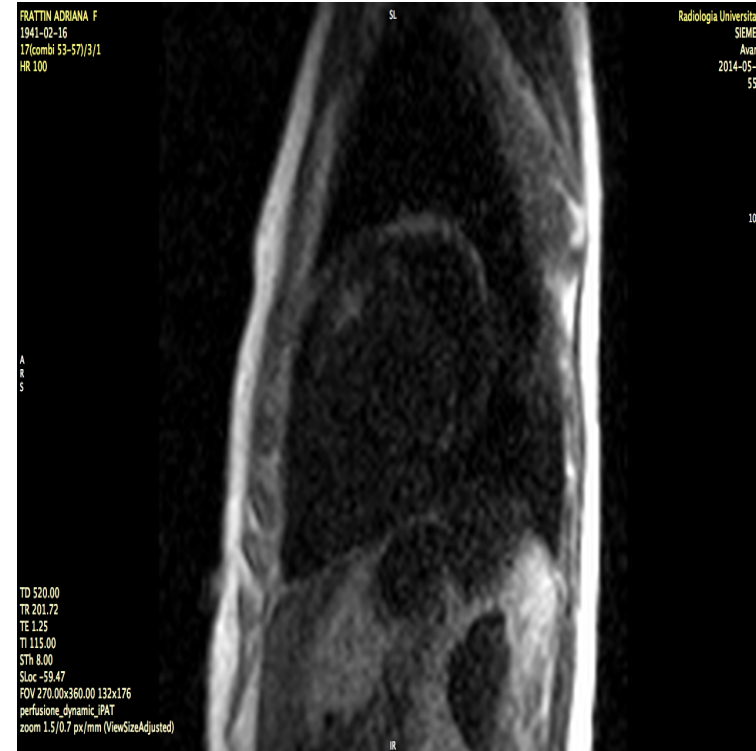- A standard rest perfusion sequence with 0.05—0.1 mmol/kg of gadolinium-based contrast agent can help determine the vascularity of a suspected cardiac mass.
- Vascular tumors will show signal intensity enhancement during the arterial phase, as opposed to nonvascular structures, such as thrombus.



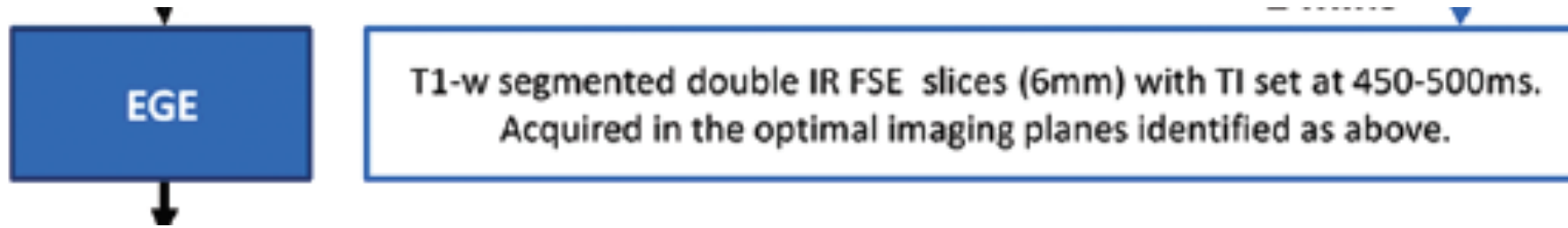
How can I perform a cardiac MRI?



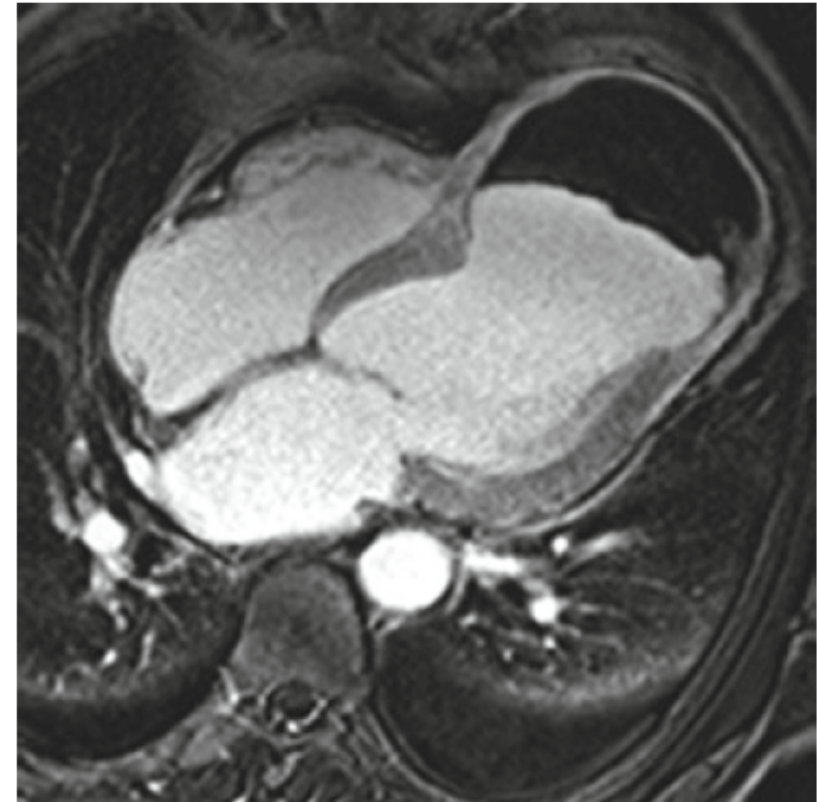
- A standard rest perfusion sequence with 0.05—0.1 mmol/kg of gadolinium-based contrast agent can help determine the vascularity of a suspected cardiac mass.
- Vascular tumors will show signal intensity enhancement during the arterial phase, as opposed to nonvascular structures, such as thrombus.



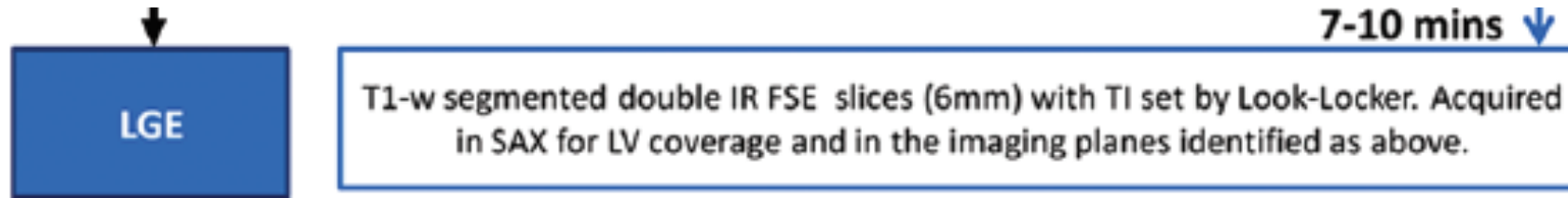
How can I perform a cardiac MRI?



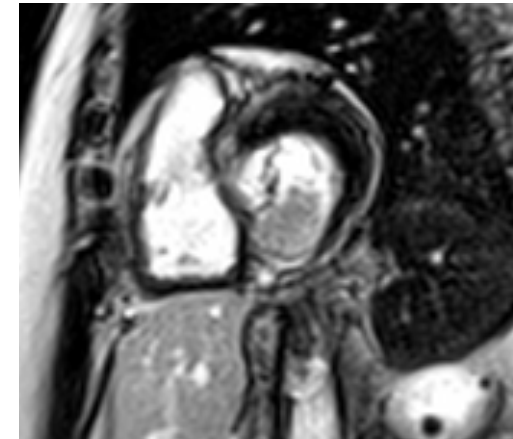
- EGE and LGE acquisitions following a dose of 0.1–0.2 mmol/kg of gadolinium-based contrast agent.
- EGE imaging optimal technique for identifying thrombus.
- Within the first 2 minutes of contrast agent administration, with the same segmented double-inversion-recovery FSE but with a long inversion time of 450–500 msec (example pulse sequence parameters: 4.5/1.8; flip angle, 15; section thickness, 8 mm, no gap; matrix, 240 x 240).



How can I perform a cardiac MRI?



- LGE images are acquired 7—10 minutes after the contrast agent injection.
- Complete short-axis stack and one to three sections in both long axes to ensure complete myocardial coverage for the detection of myocardial scarring or infiltration which may relate to coexisting disease or be part of a neoplastic process.
- Imaging planes that best demonstrate the mass.
- Segmented double-inversion-recovery FSE sequence (pulse sequence parameters: 4.5/1.8; flip angle, 15; section thickness, 8 mm, no gap; matrix, 240 x 240).





How can I perform a cardiac MRI?

Signal intensity

Low T1

High T2



Liquid; tumors

(hydration,
cellularity)

High T1

Variable T2



Fatty and protein content; T1 agents;

glycoprotein; methaemoglobin

Low T1

Low T2



Air; calcium, fibrosis,

hemosiderin



How can I perform a cardiac MRI?

EGE	LGE
<ul style="list-style-type: none">• Vascularized tumors have a fast contrast uptake even at an early stage• Thrombus has no contrast agent uptake and therefore appears almost black	<ul style="list-style-type: none">• Important uptake persists in tumors with fibrous tissue• Slow wash-out in general (>20 minutes) in all vascularized tumors• Absent in cystic lesions• In long-standing organized thrombi with neovascular phenomena/fibrosis there may be LE



What information should I write in a report?

Essential components:

- Confirmation of the presence or absence of suspected mass
- Presence, number, location, extent, and size;
- Description of location and anatomic relationship of the mass
- Assessment of size of mass in three cross-sectional dimensions
- Description of margins-smooth, irregular, or infiltrating
- Description of motion of the mass at cine imaging and its functional significance
- Mobility and obstruction if present;
- Description of T1w, T2w and contrast enhancement imaging patterns
- Description of tumor-associated complications (eg. Pericardial effusion)
- Assessment of features that may suggest malignancy
- Assessment of likely diagnoses



What information should I write in a report?

Essential components:

- Confirmation of the presence or absence of suspected mass
- Presence, number, location, extent, and size;
- Description of location and anatomic relationship of the mass

CMR allows tissue characterization, but cannot provide histopathologic information

significance

- Mobility and obstruction if present;
- Description of T1w, T2w and contrast enhancement imaging patterns
- Description of tumor-associated complications (eg. Pericardial effusion)
- Assessment of features that may suggest malignancy
- Assessment of likely diagnoses



Systemic illness

Cardiovascular symptoms

- Congestive heart failure
- Thromboembolism
- Arrhythmias/interventricular conduction disturbances

Incidental finding

History of non cardiac malignancy



What are the main cardiac masses?

Primary: 0,0017-0,28%

Tumor	Incidence	
BENIGN		
Myxoma	30%	
Lipoma	10%	
Fibroelastoma	10%	
Rhabdomyoma	8%	} children
Fibroma	4%	
Hemangioma	3%	
Teratoma	3%	
Other	5%	
Total	70-75%	
MALIGNANT		
Angiosarcoma	9%	
Rhabdomyosarcoma	6%	} children
Mesothelioma	4%	
Fibrosarcoma	3%	
Lymphoma	2%	
Other sarcomas	3%	
Other	<1%	
Total	25-30%	

Metastatic: frequency of
30—50 times of primary
malignant cardiac tumors

Non-tumoral cardiac masses and mimics

Thrombus

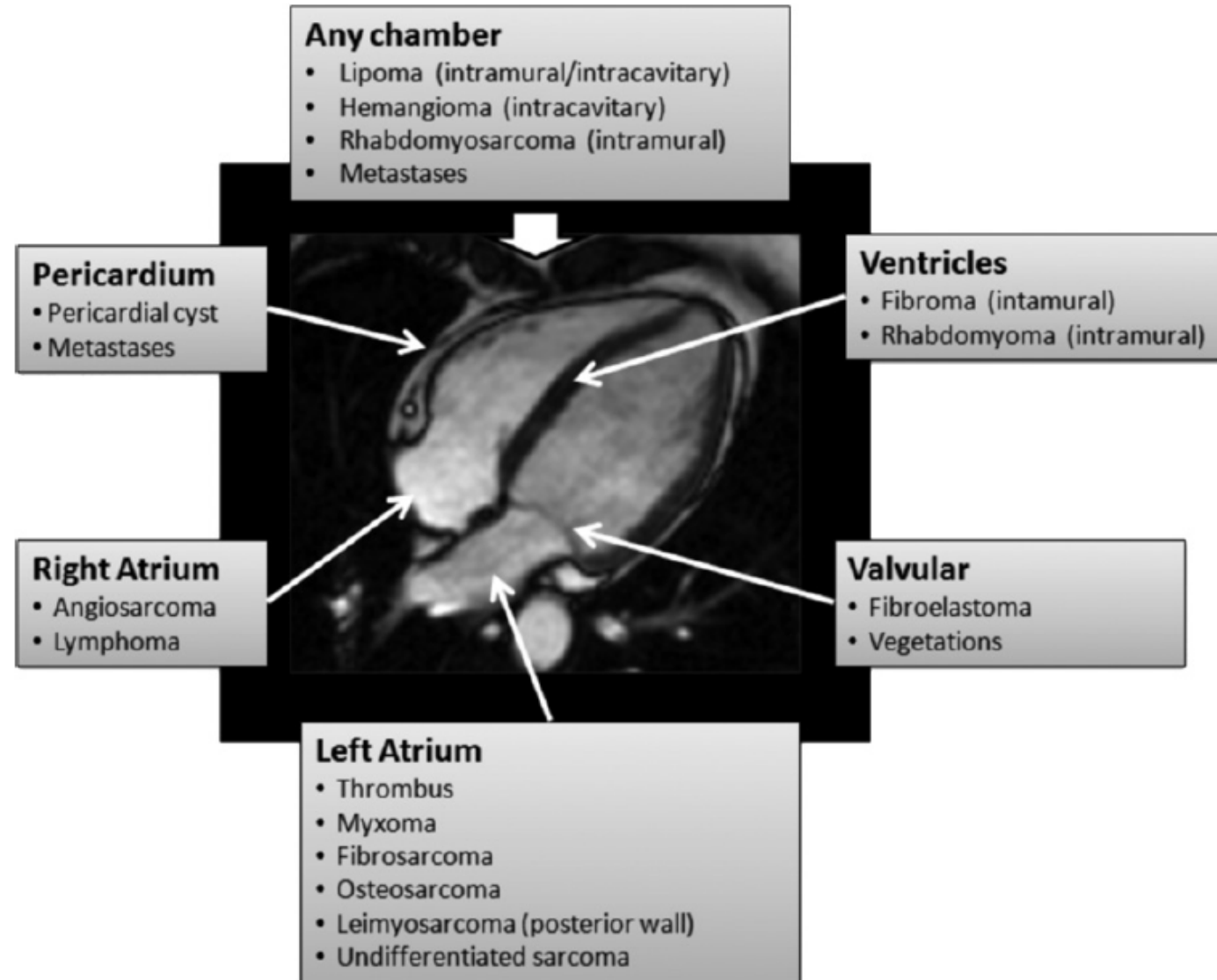
Valvular vegetations

Lipomatous hypertrophy of the IAS

Hydatid cyst

Pleuropericardial cyst


What are the main cardiac masses?





What are the main cardiac masses?

	Preferential location	T1w- imaging	T2w- imaging	Cine MRI	Contrast enhancement	Appearance
<i>Benign cardiac tumors</i>						
Myxoma	Left atrium (IAS)	Variable	Variable	Low	Yes	Heterogeneous sharp border
Lipoma	No	High	High	Medium	No	Homogeneous, sharp border
Papillary fibroelastoma	Cardiac valves	Medium	Medium	Low	?	Small (less than 1 cm)
Rhabdomyoma	Atrium Intramyocardial/ Intracavitary	Medium/ high	Medium	Low	Similar to myocardium	Infants/Multiple Tendency to disappear
Fibroma	Ventricles Intramyocardial	Medium	Medium	Low	Variable	Infants/Single
Pheochromocytoma	Intrapericardial (roof of left atrium)		High		Yes	
Hemangioma	Ventricles Intramyocardial/ Intracavitary	Medium	Very high	Variable	Yes Variable	Heterogeneous



What are the main cardiac masses?

	Preferential location	T1w- imaging	T2w- imaging	Cine MRI	Contrast enhancement	Appearance
<i>Malignant cardiac tumors</i>						
Angiosarcoma	Right atrium Pericardial and Myocardial invasion	Variable (mixed)	Variable (mixed)	Low	Yes	Heterogeneous “Cauliflower” appearance
Rhabdomyosarcoma	No	Medium	High	?	Yes	
Malignant fibrous histiocyoma	Left atrium (posterior wall)	Medium	High	?	?	Slightly heterogeneous
Lymphoma	Pericardial effusion Intracardiac masses	Medium	Medium	Low	Yes	Variable
Malignant pericardial Mesothelioma	Pericardium	Medium	High	Low	Yes	Heterogeneous (no myocardial invasion)
Metastases	Variable, pericardial effusion	Low	High	Low	Yes	Often multiple



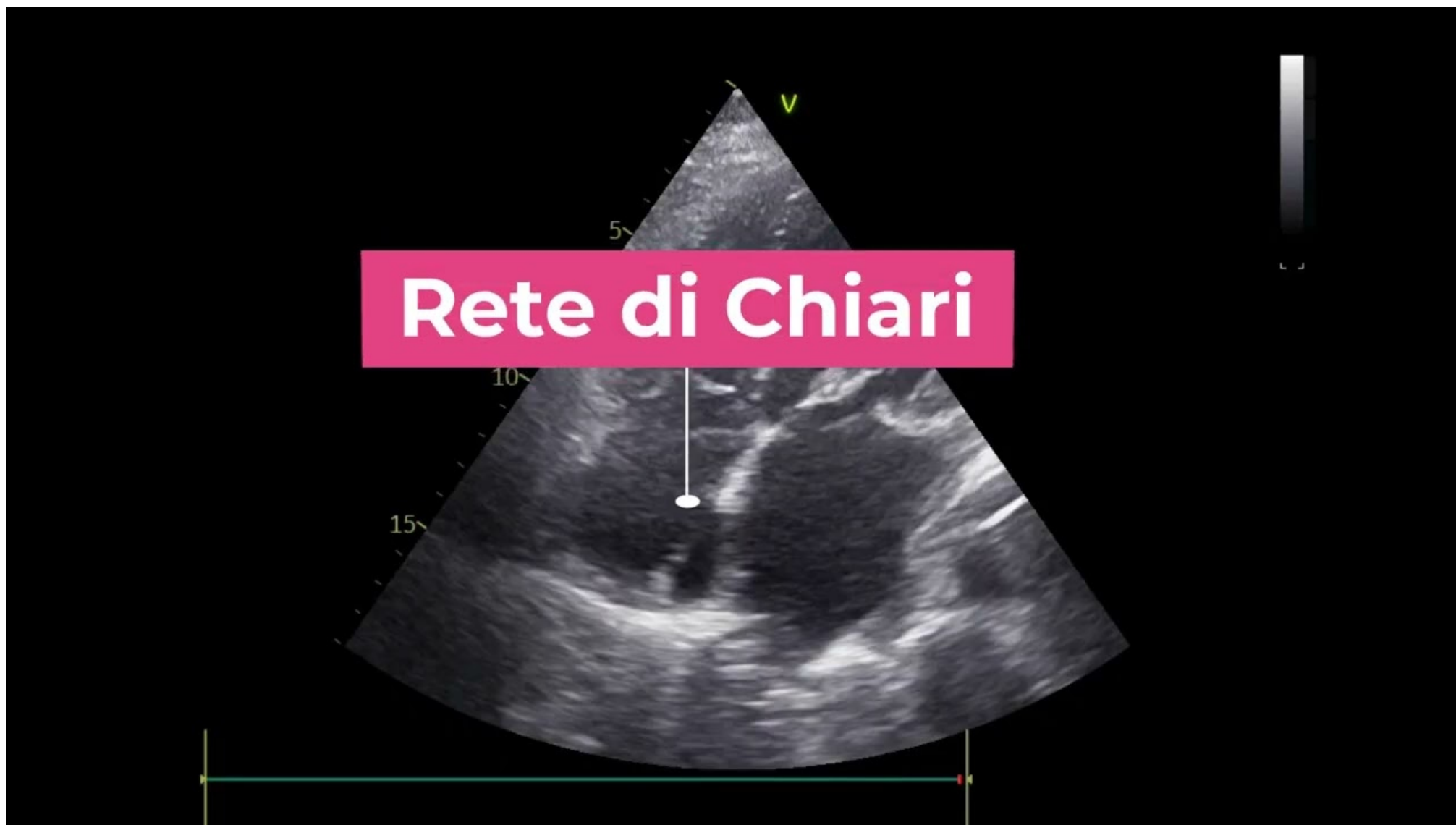
What are the main cardiac masses?

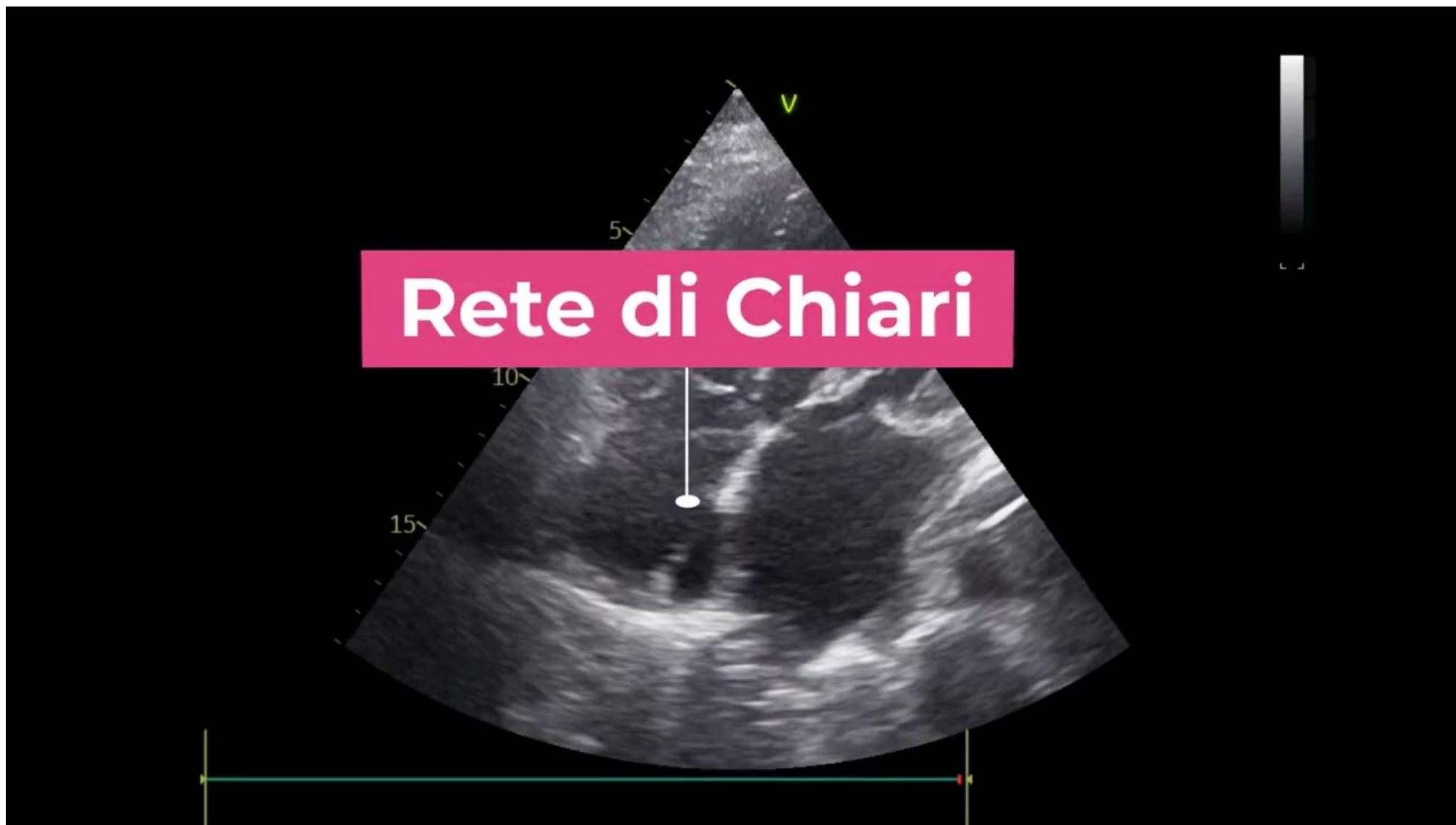
	Preferential location	T1w- imaging	T2w- imaging	Cine MRI	Contrast enhancement	Appearance
<i>Nontumoral cardiac masses and mimics</i>						
Thrombus	Atrium/Appendage (valve disease/AF) Ventricles (if diseased)	Medium to high	Medium to high	Low	No (possible if chronic)	Appearance related to age of thrombus
Valvular vegetations	Cardiac valves	Not visible	Not visible	Low	No	
Lipomatous hypertrophy of the interatrial septum	Interatrial septum	High	High	Medium	Low	“Camel hump” or “dumbbell” shaped, sparing the fossa ovalis
Hydatid cyst	Left ventricle (IVS)	Low	Very high		No	Low-signal intensity peripheral border (pericyst)
Pleuropericardial cyst	Right cardiophrenic angle	Low	Very high		No	Sharply defined



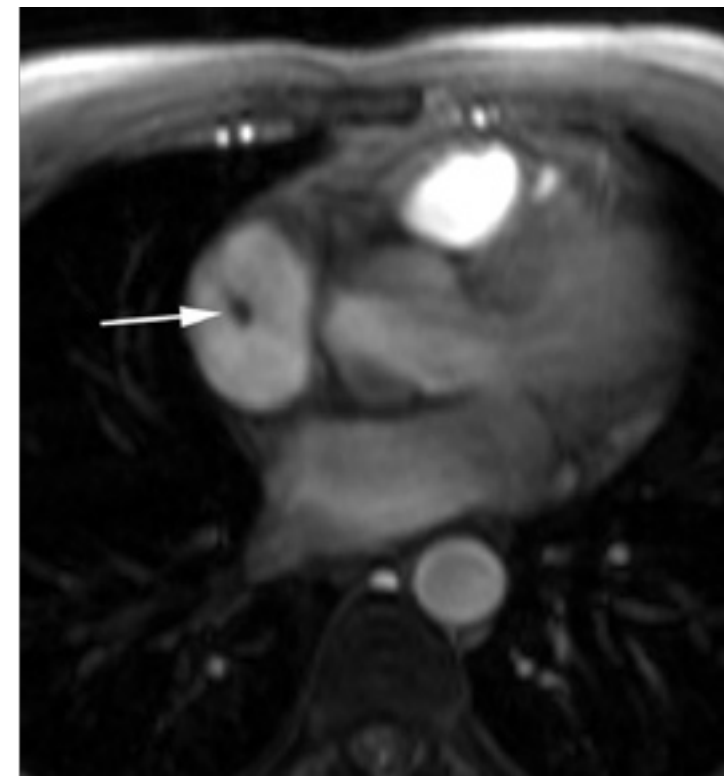
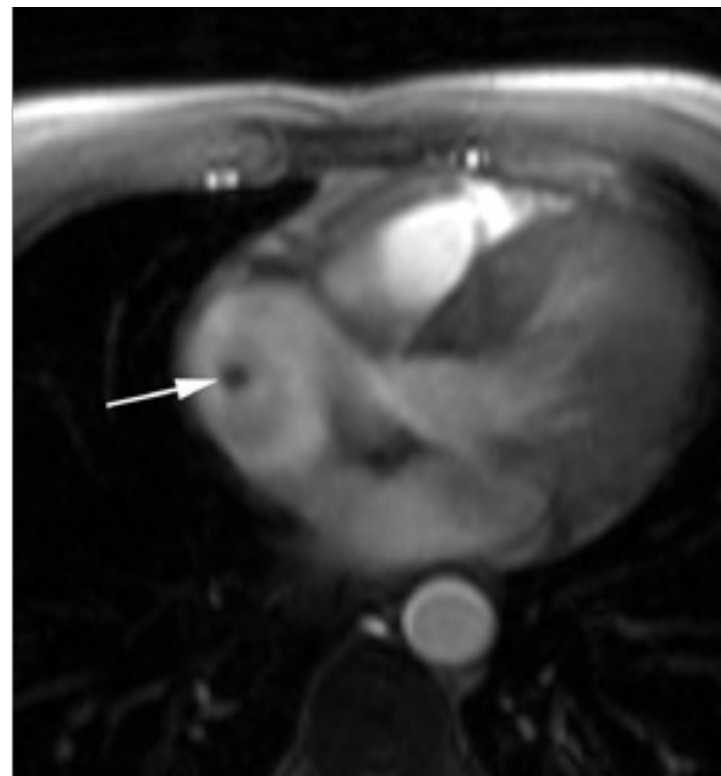
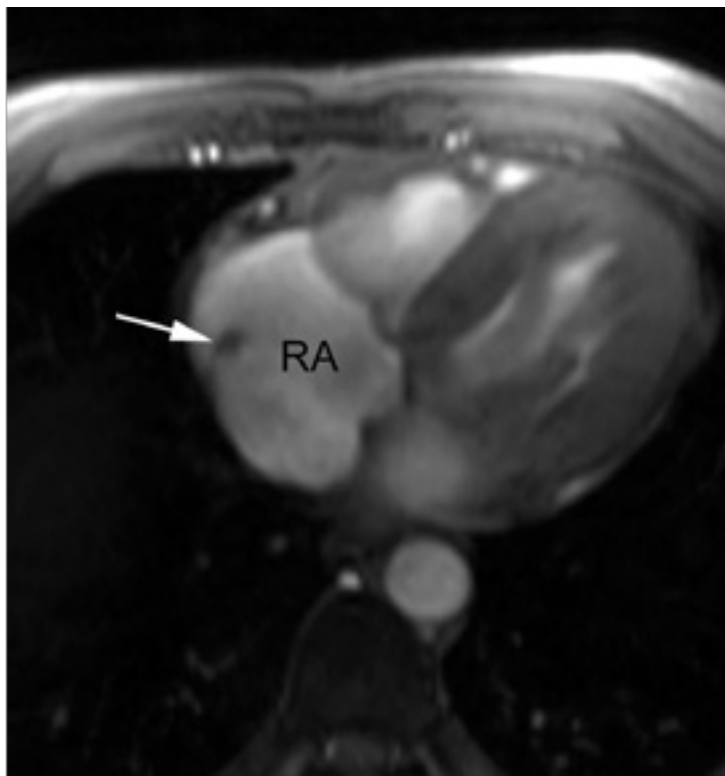
What are the main cardiac masses?

- **Non-tumoral cardiac masses and mimics**
- Metastatic tumors
- Primary tumors

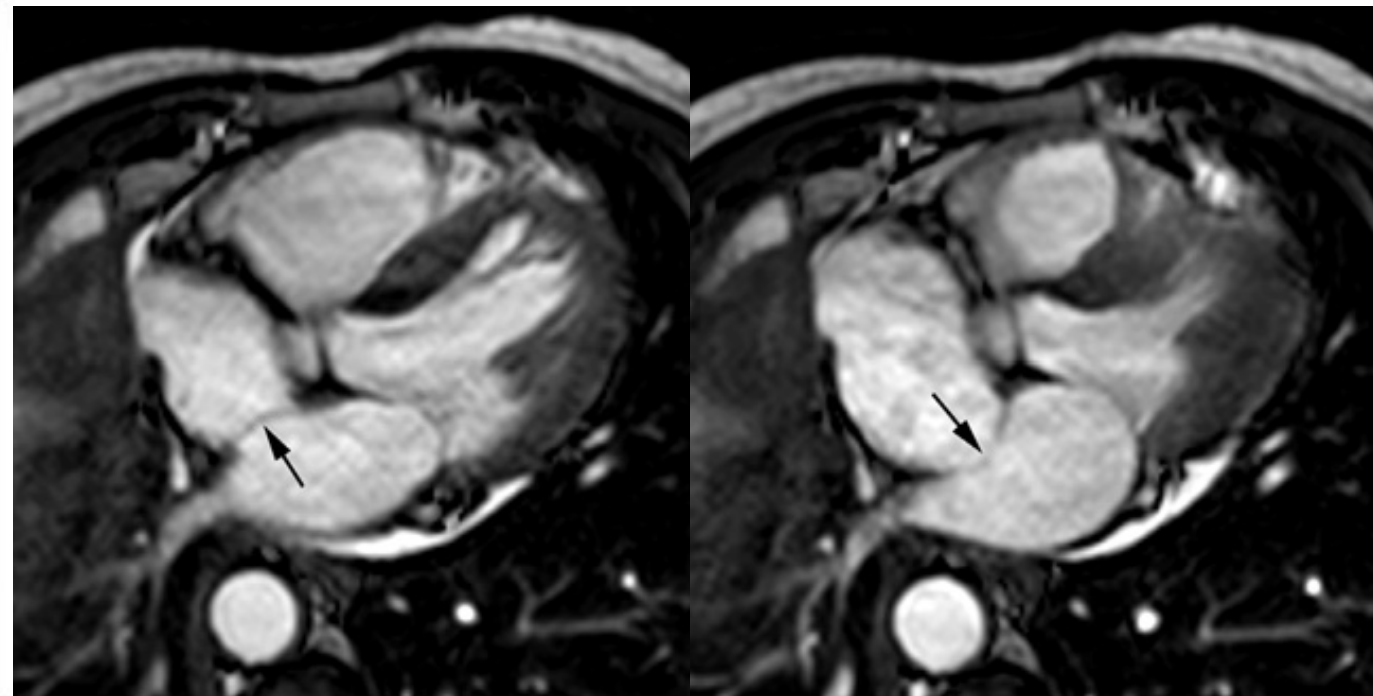
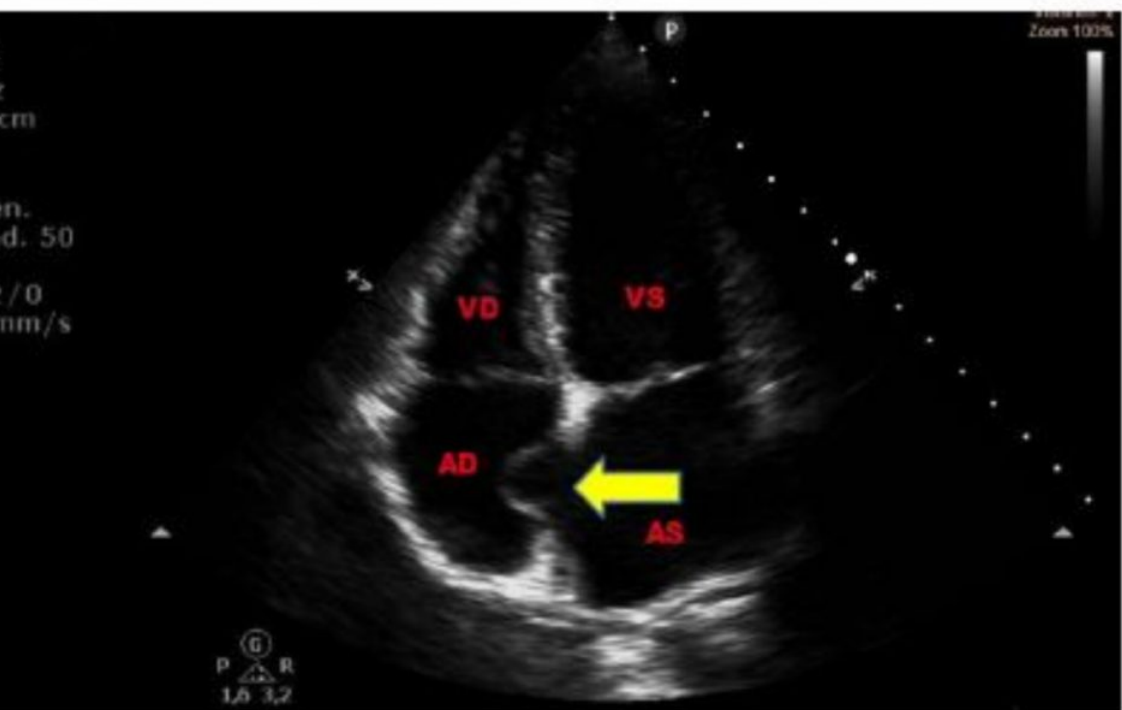




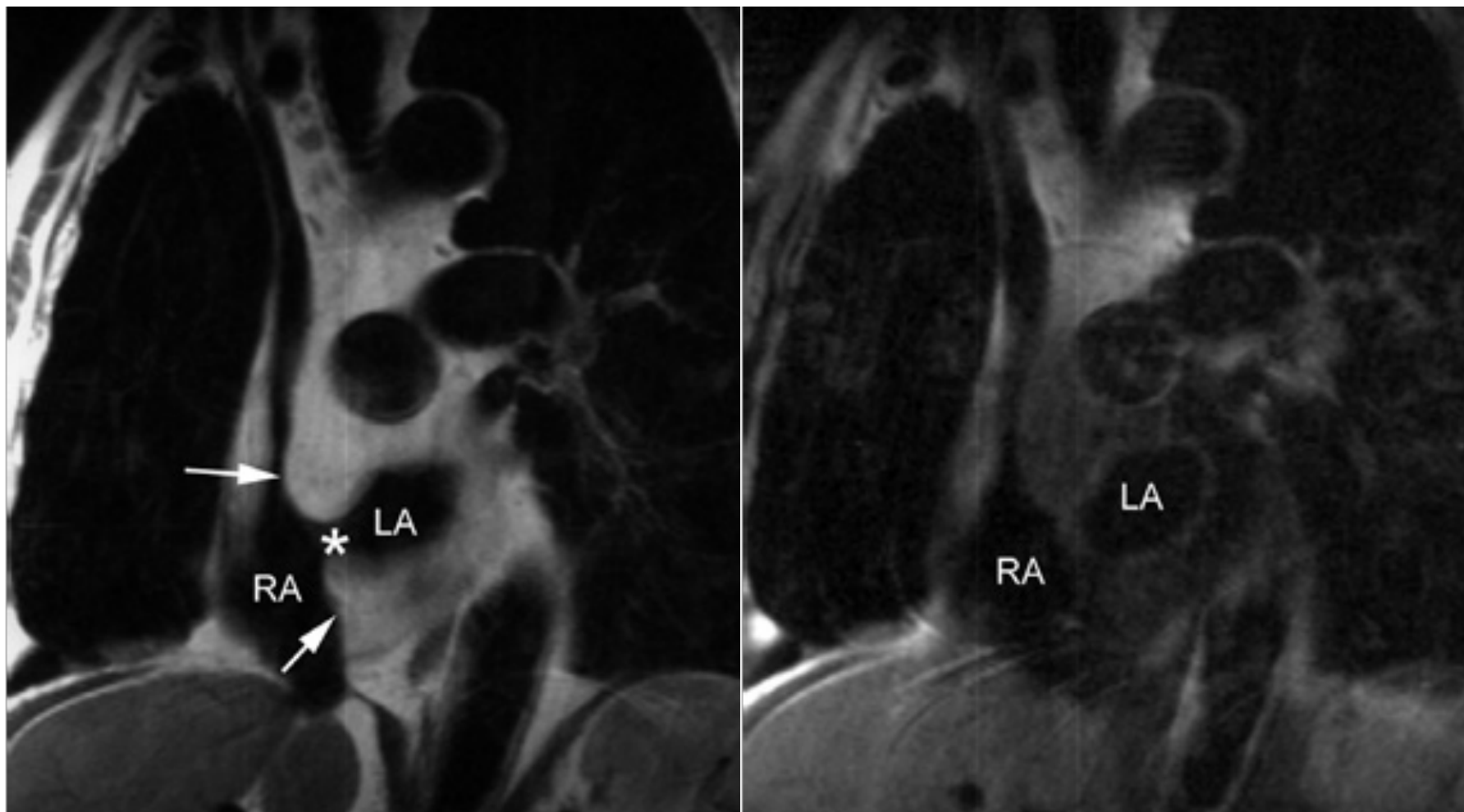
Crista terminalis



Aneurisma del setto interatriale



Lipomatosi del setto interatriale



Thrombus

- Thrombus is one of the most common causes of an intracardiac mass.
- Thrombus is typically found in the left atrium in association with atrial fibrillation or mitral valve disease or in severely dysfunctional LV following myocardial infarction.
- CE- MRI visualizes a substantially higher number of thrombi than TTE/TEE and CINE-MRI.

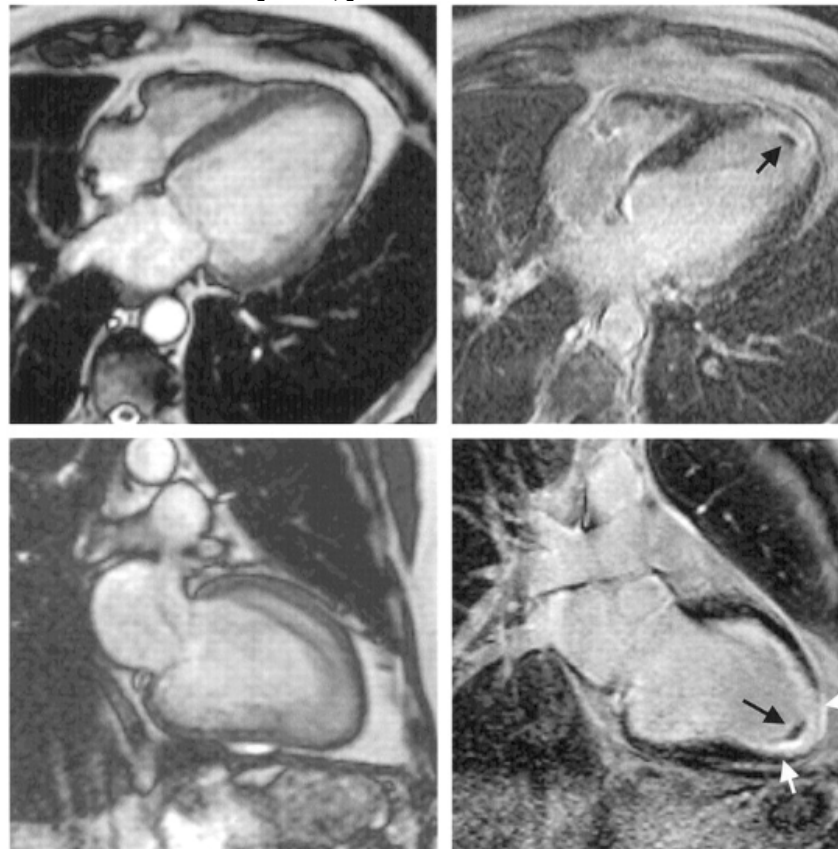
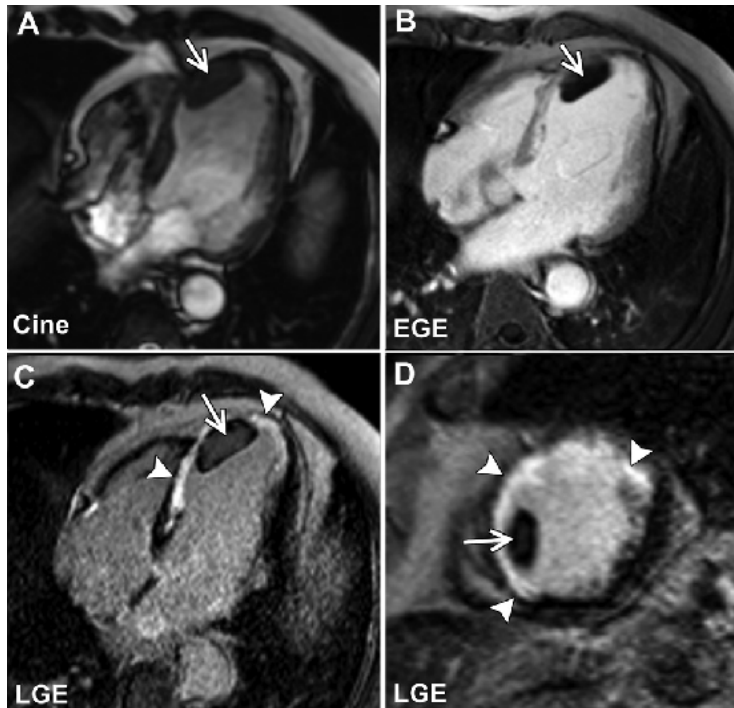


Table III. Sensitivity and specificity for subgroup with all 3 imaging modalities


	Total (n)	MRI	TTE	TEE
Sensitivity	48	88% (79%-97%)	23% (11%-35%)	40% (26%-54%)
Specificity	112	99% (97%-100%)	96% (92%-99.6%)	96% (92%-99.6%)

- ✓ TTE: insufficient image quality and problems assessing the LV apex
- ✓ CINE-MRI: presence of slow and turbulent flow patterns in dysfunctional wall segments and lack of contrast between mural thrombus and adjacent myocardium

Cardiac Mass	T1w*	T1w fat sat*	T2w*	LGE
Pseudotumors				
Thrombus	Low (high if recent)	Low	Low (high if recent)	No uptake†



- LV mass with characteristics consistent with avascular tissue: on DE-CMR low SI mass surrounded by high SI structures such as cavity blood and/or scar.
- With long TI sequence, regions with contrast uptake such as viable myocardium increase an image intensity, thrombus appears homogeneously black and there is improved thrombus delineation.
- Rarely very chronic, organized thrombus may enhance peripherally due to its fibrous content.



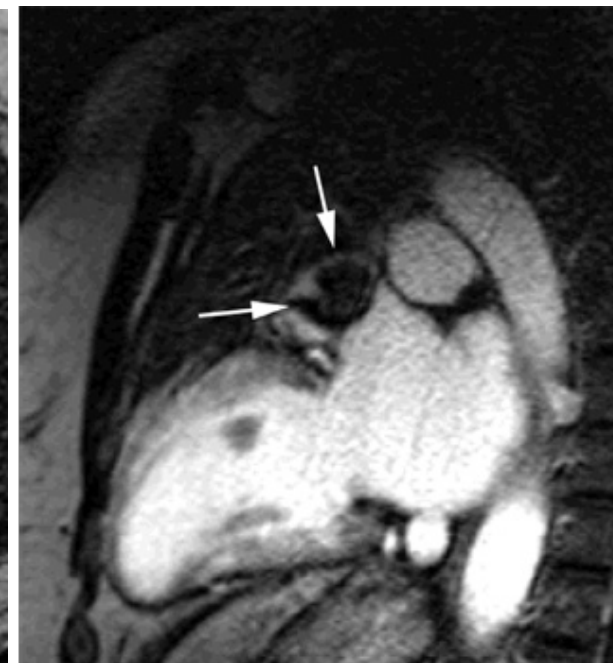
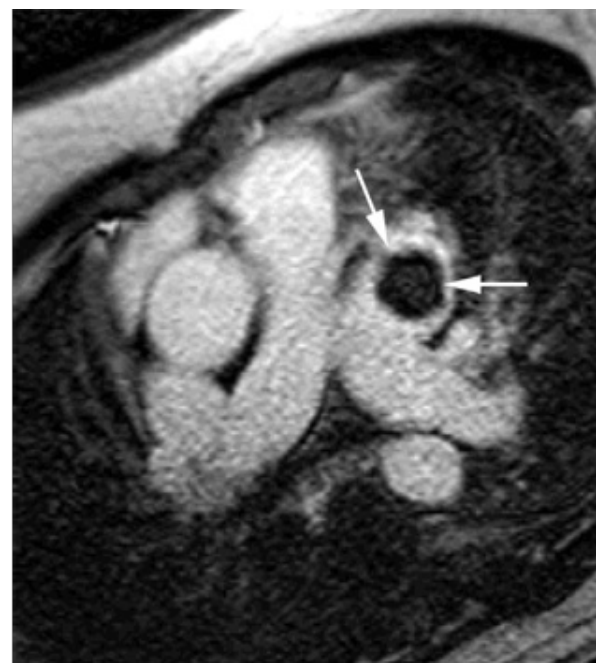
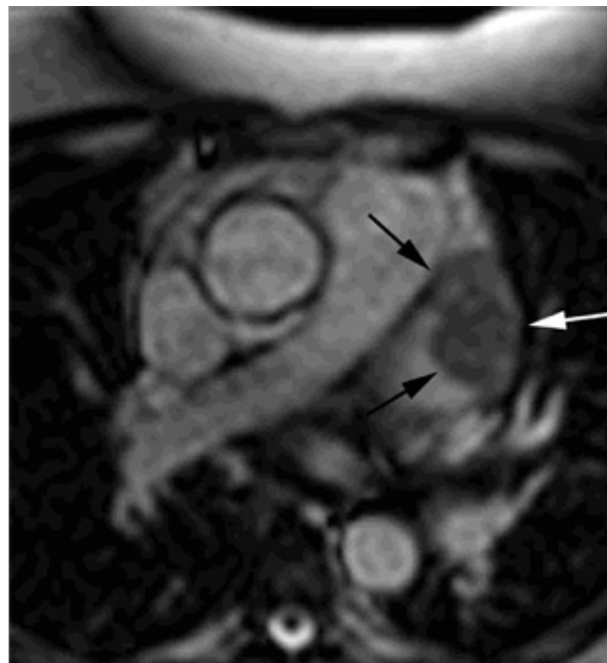
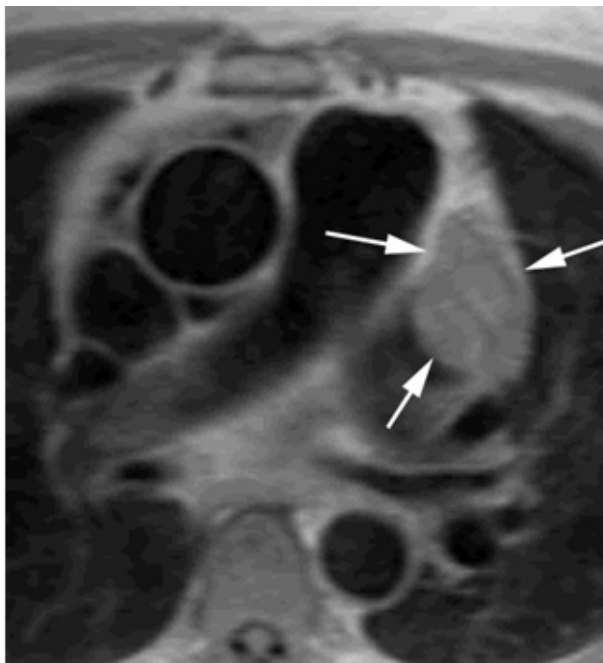
- T1- and T2-weighted signal characteristics vary depending on the age of a thrombus.

Cardiac MR Imaging Signal Intensity Characteristics for Thrombus

Age of Thrombus	T1-weighted Signal Intensity	T2-weighted Signal Intensity	EGE Imaging	LGE Imaging
Acute	High	High	No uptake	No uptake
Subacute	High	Low	No uptake	No uptake
Chronic	Low	Low	No uptake	No uptake*

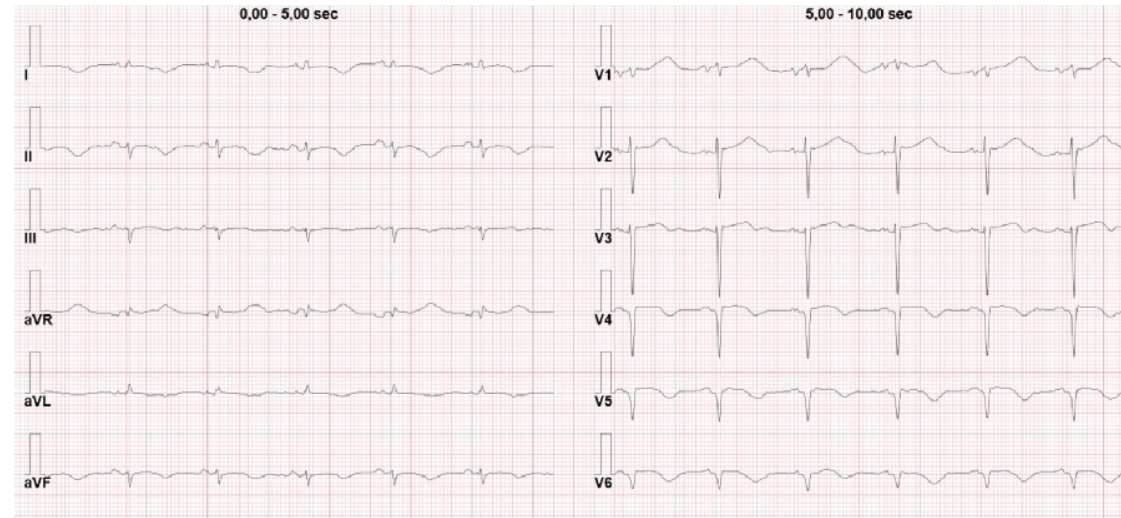
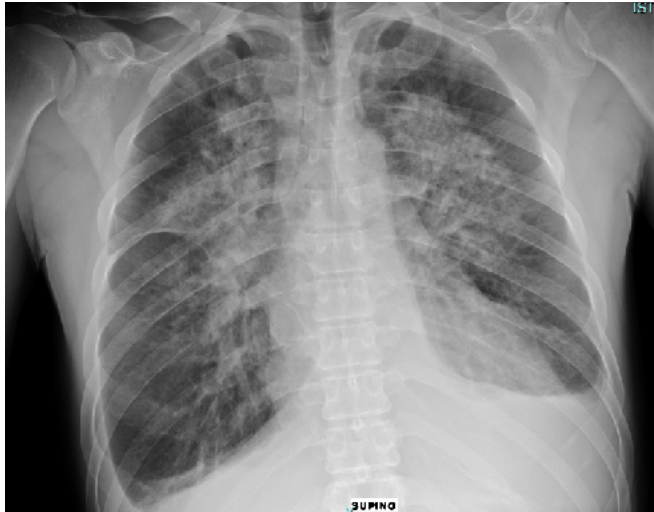
* Organized chronic thrombus may show peripheral enhancement on LGE images owing to fibrous content.

Thrombus in left atrial appendage



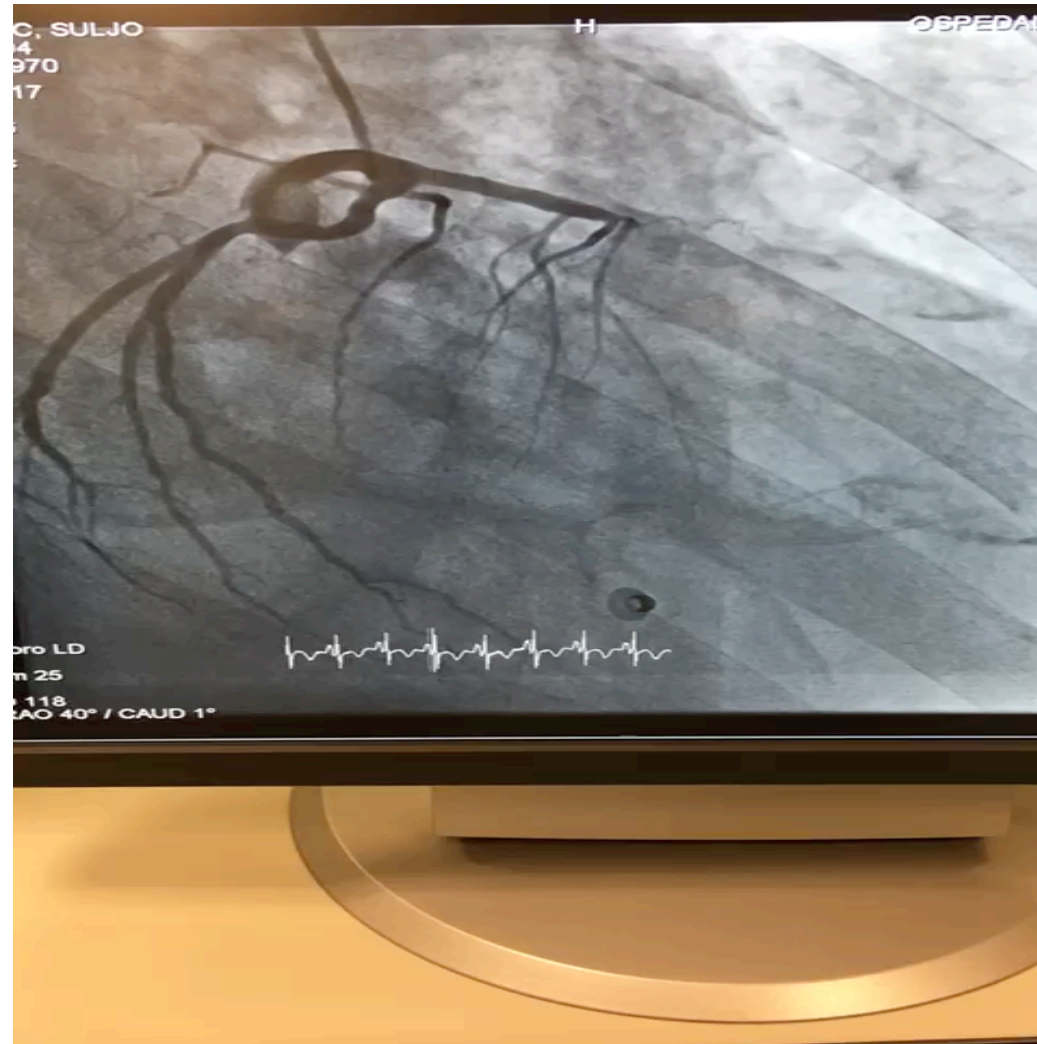
Clinical case: thrombus


- Male, 47 years old, smoker
- Chest pain a week earlier and worsening dyspnoea
- Laboratory tests: CRP 32,73 mg/L, BNP 1022 pg/mL, troponin I 0,08 microg/L






Clinical case: thrombus



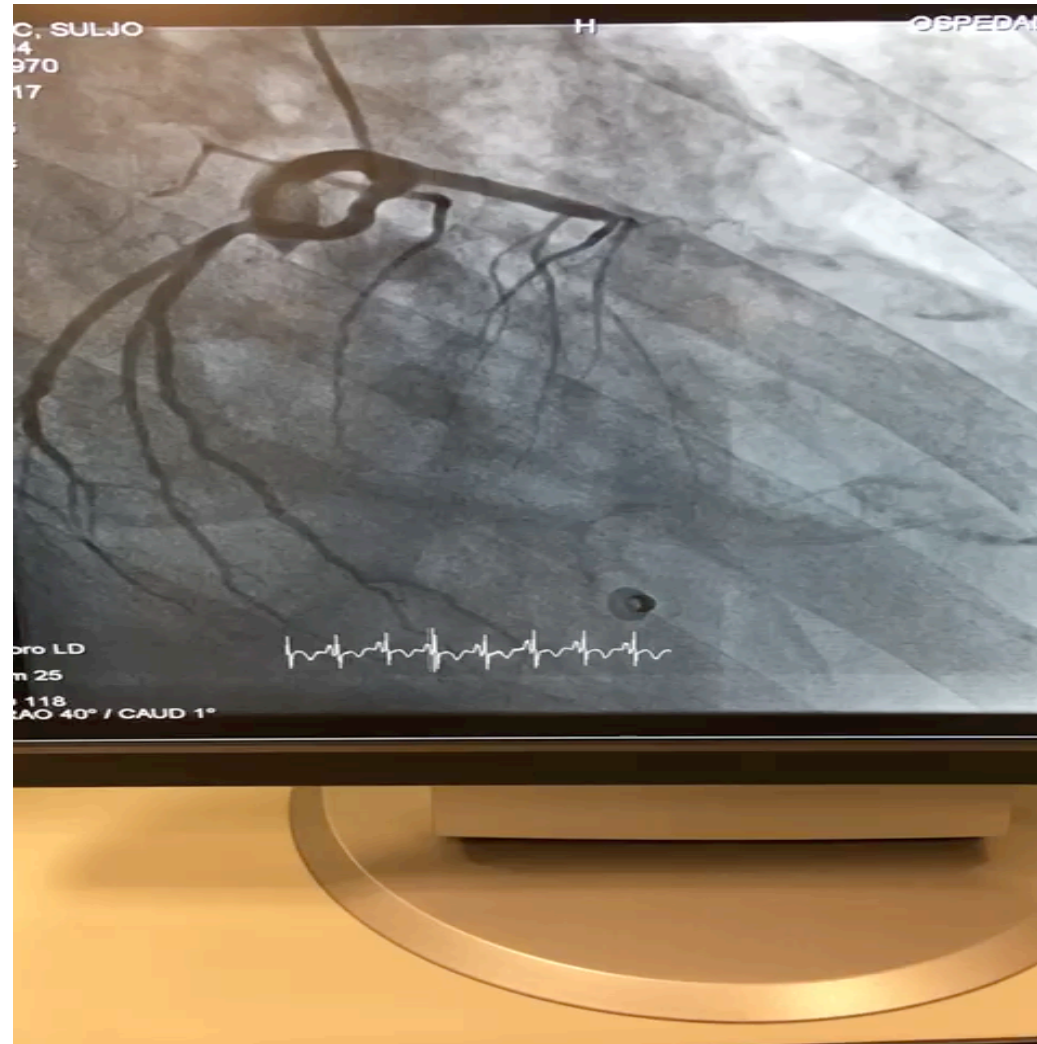


Clinical case: thrombus

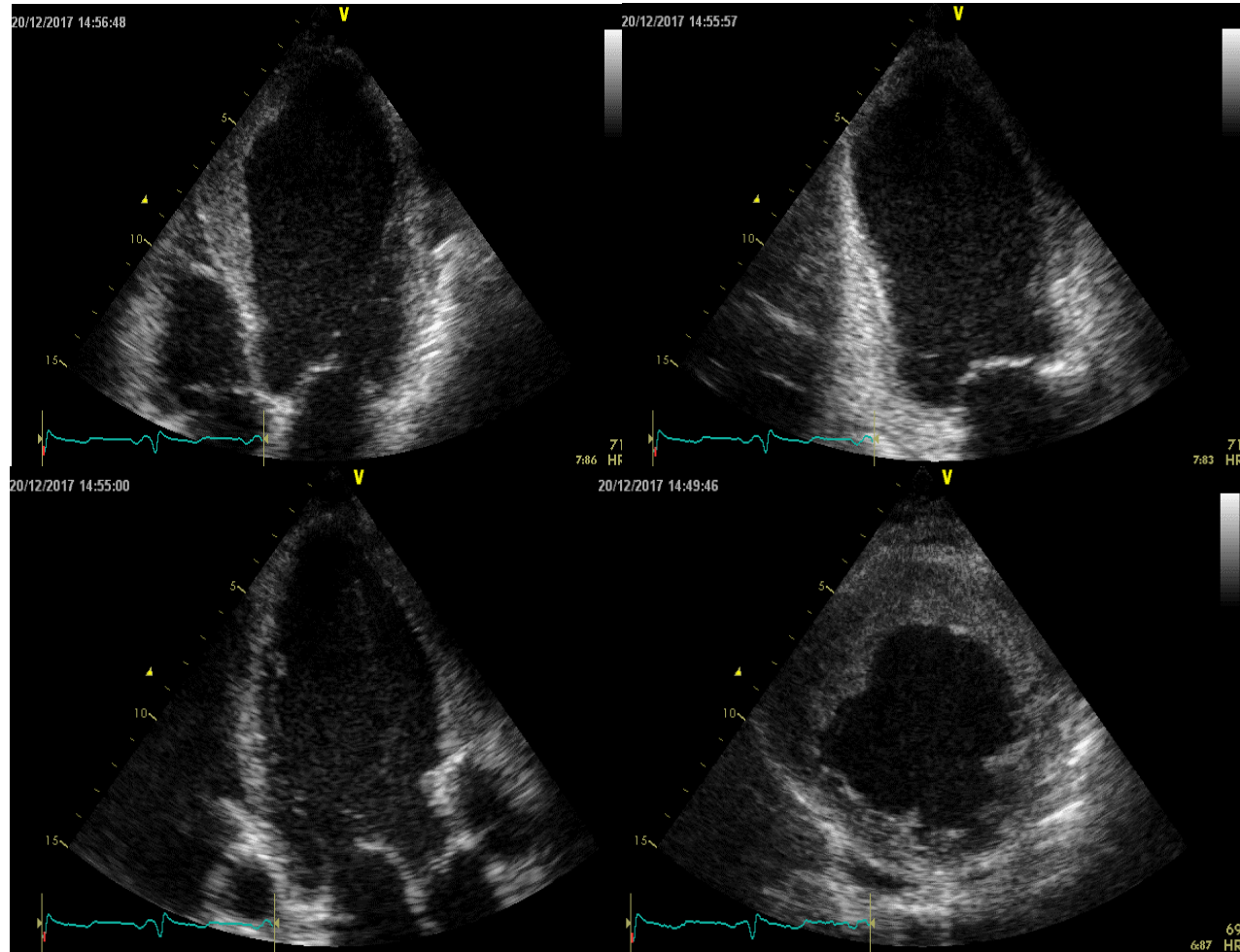




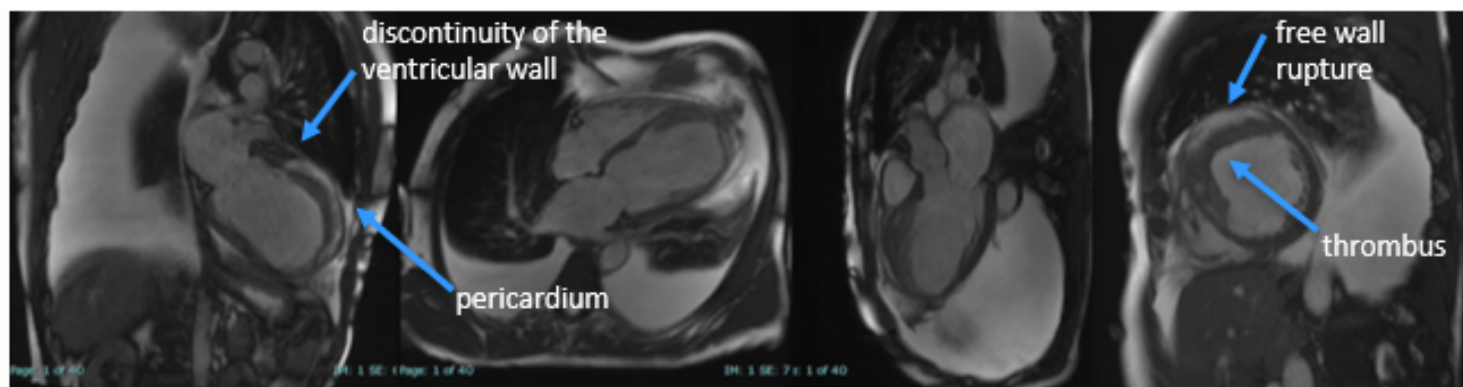
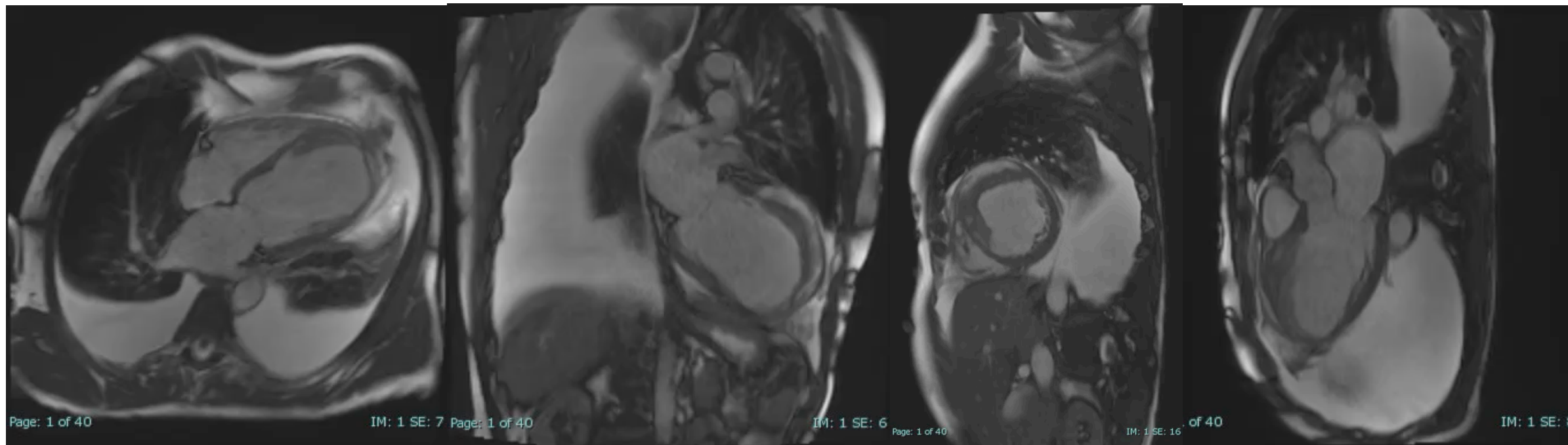
Clinical case: thrombus



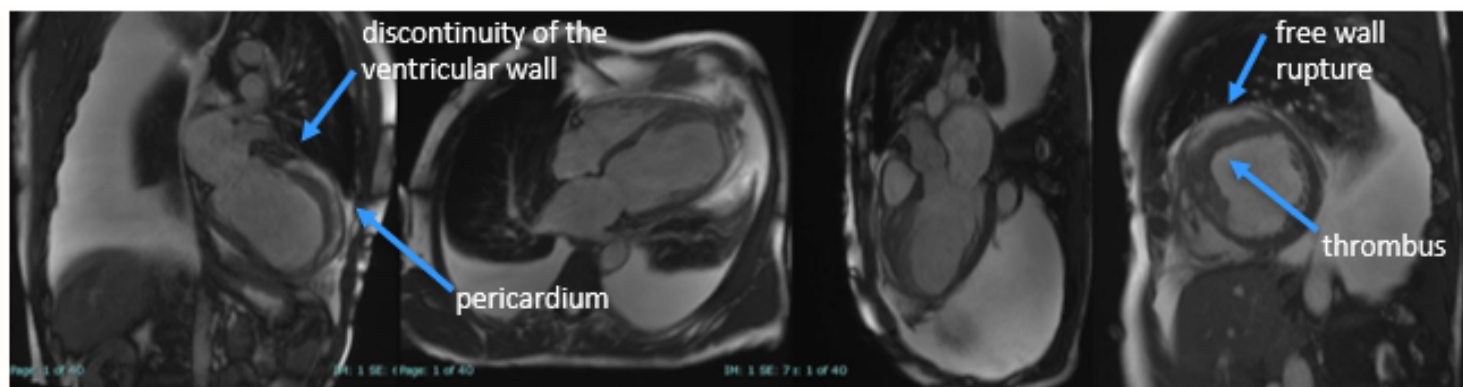
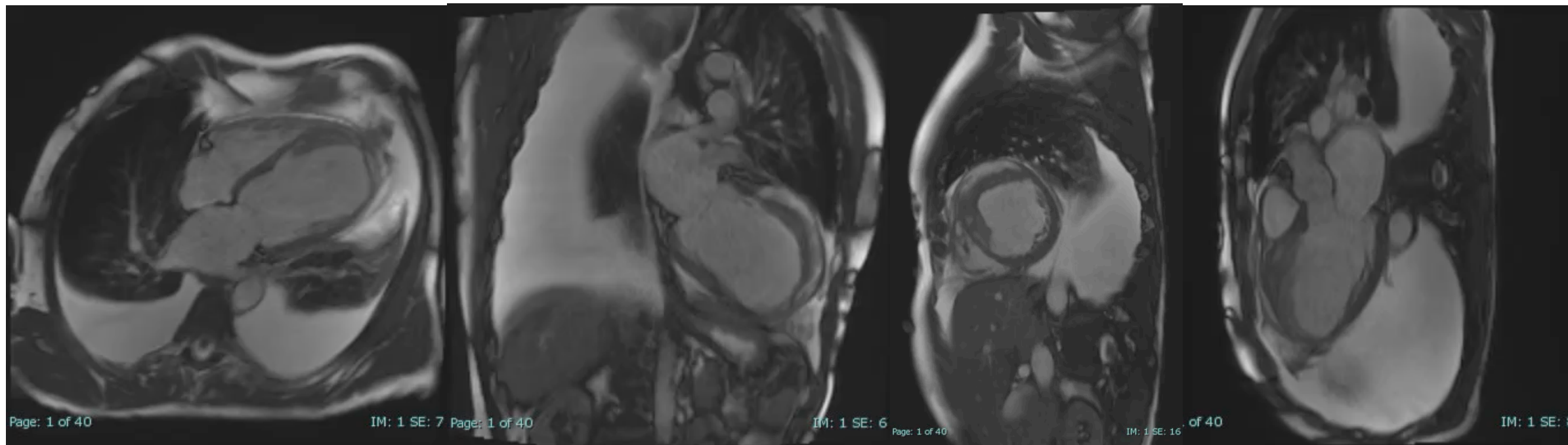
Clinical case: thrombus



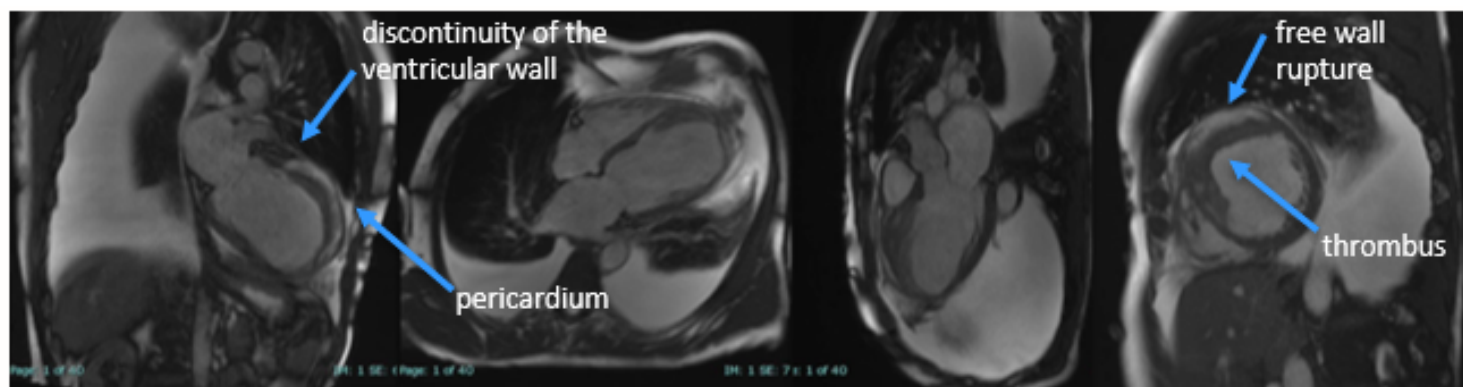
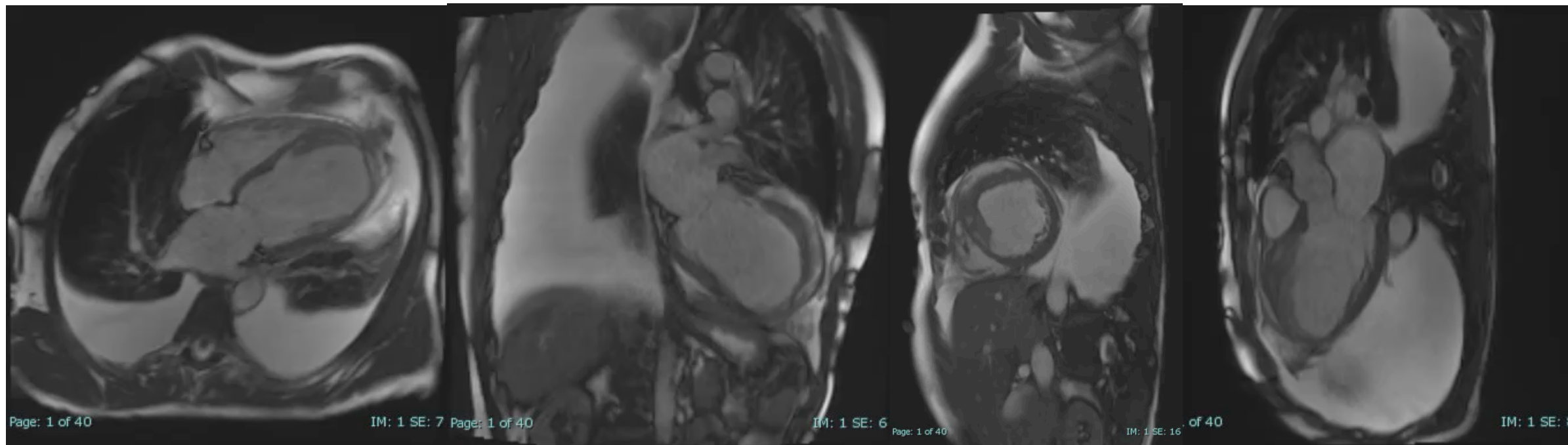
Clinical case: thrombus



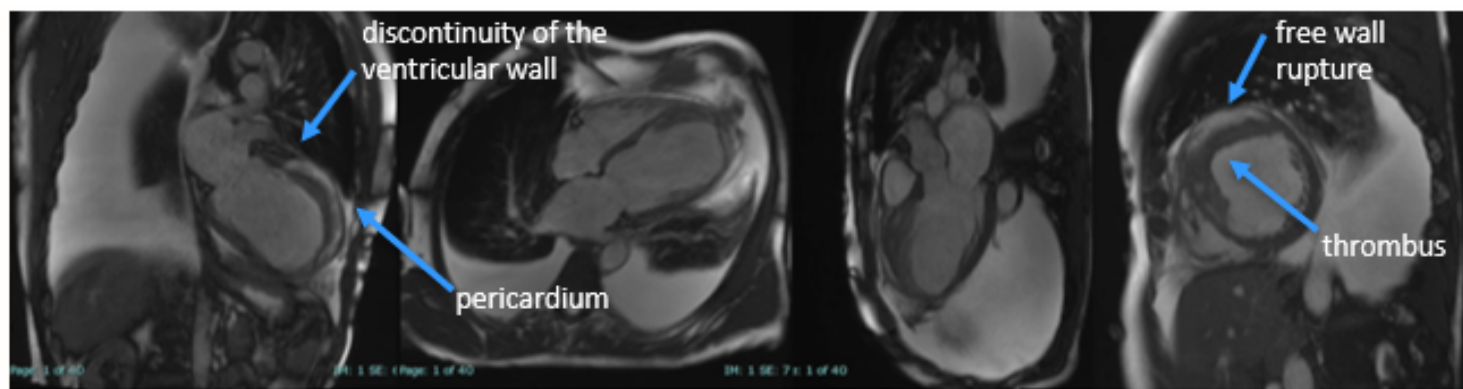
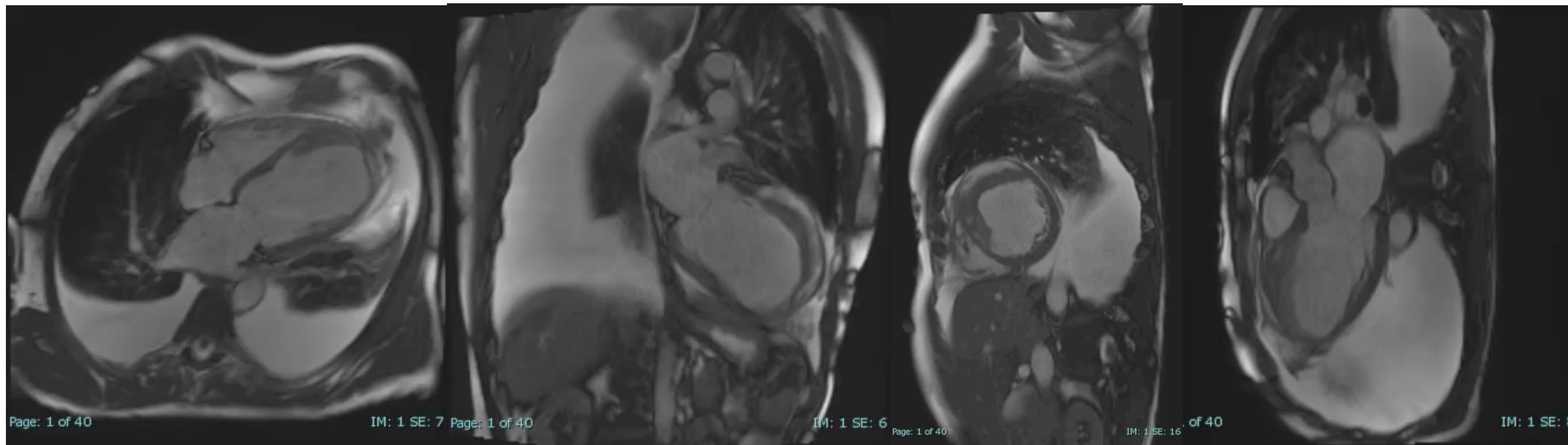
Clinical case: thrombus



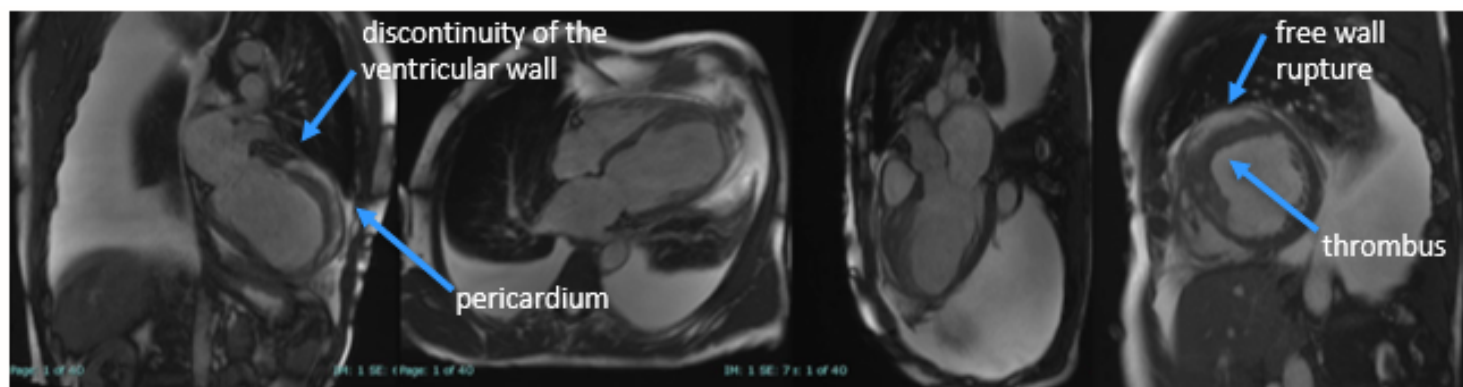
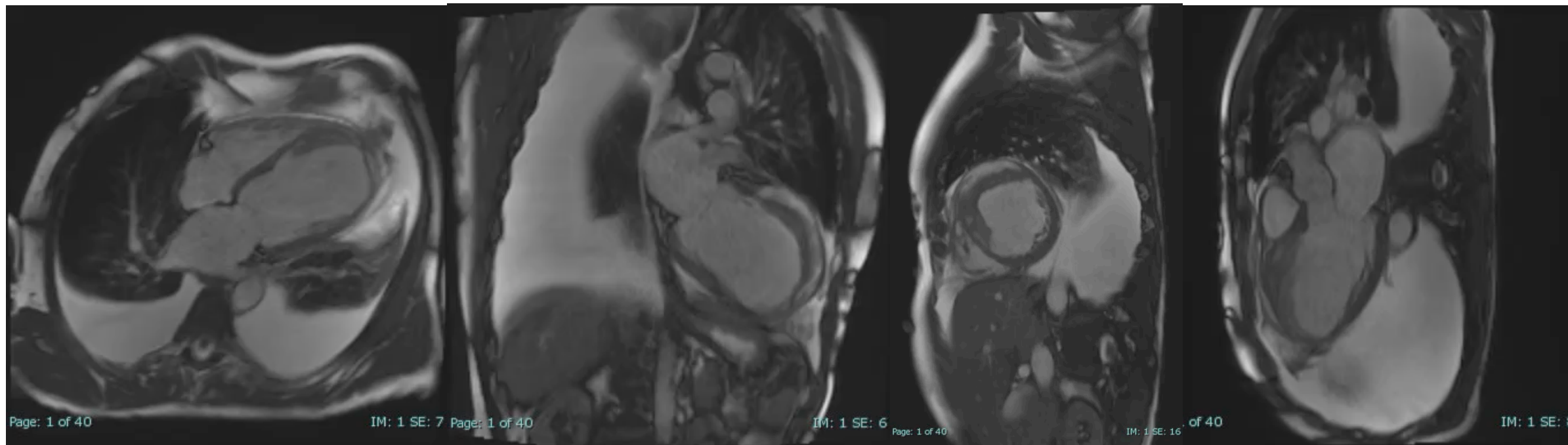
Clinical case: thrombus



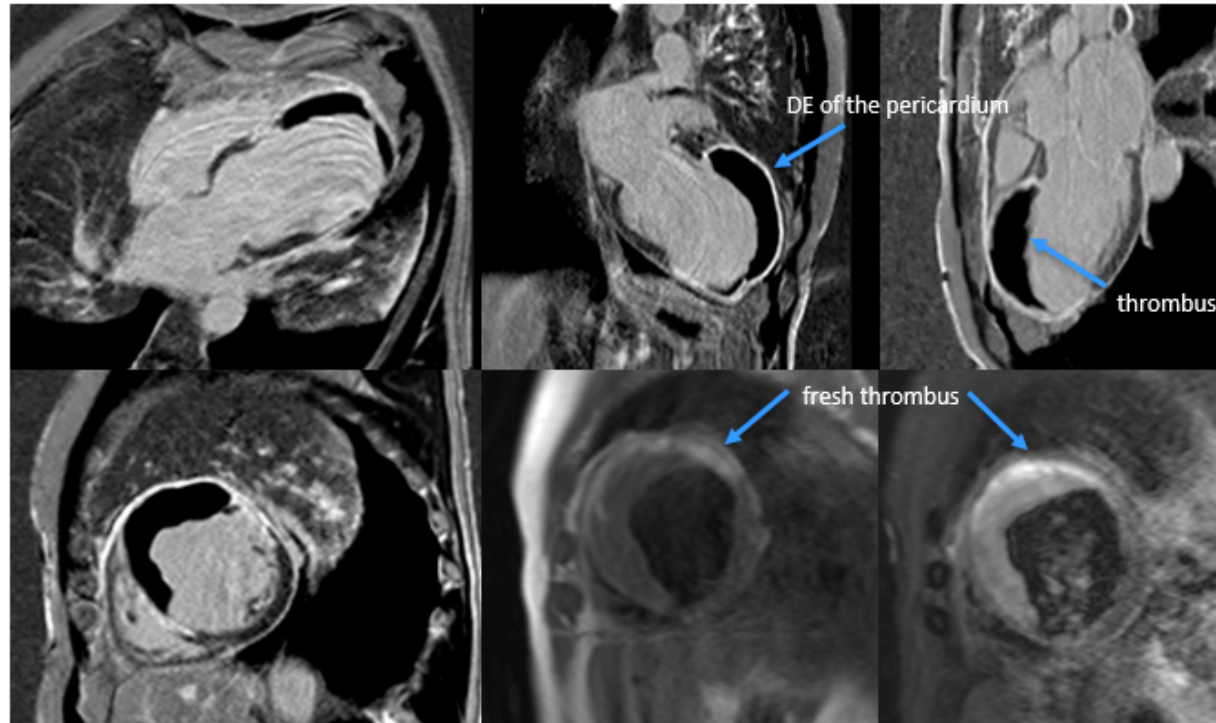
Clinical case: thrombus



Clinical case: thrombus



Clinical case: thrombus



“Voluminosa deposizione trombotica stratificata a parete, con morfologia semilunare, adesa al setto ed alla parete anteriore medio-apicale (massimi spessore di 1,5 cm ed estensione longitudinale di 9 cm), a disomogenea intensità di segnale in relazione all’ evidenza di lacune di iperintensità di segnale nelle sequenze T1w e T2w negli strati in prossimità della parete miocardica, come da componente ematica recente.”



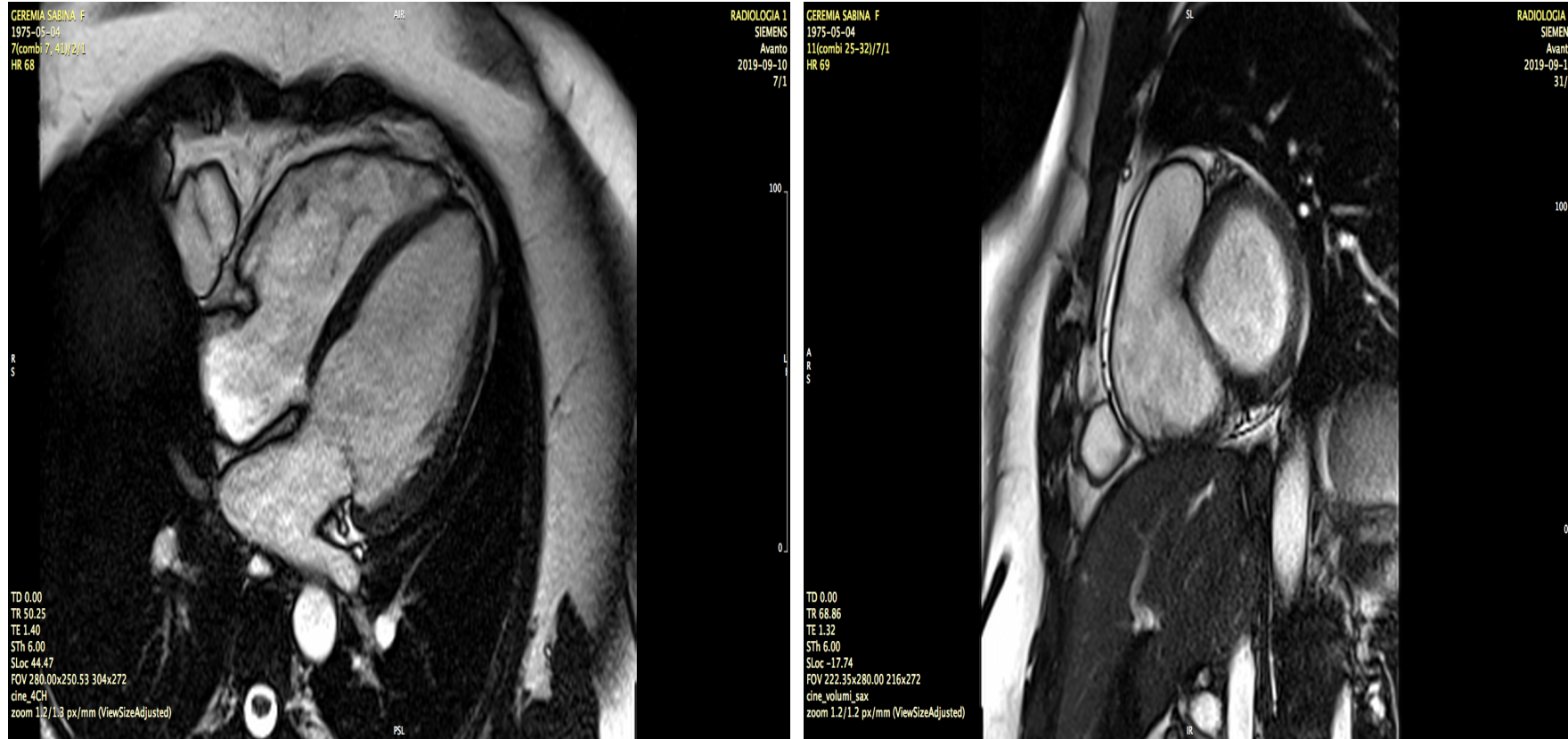
Pleuro-pericardial cyst

- Pericardial cysts are benign congenital fluid-filled structures.
- They are usually located in the right pericardiophrenic angle.
- The cysts have a well-demarcated and homogeneous appearance.
- MRI is also helpful in differentiation from other cystic mediastinal structures such as bronchogenic cyst, cystic teratoma, cystic neurogenic tumor, and thymus cyst.

Cardiac Mass	T1w*	T1w fat sat*	T2w*	LGE
Pseudotumors				
Pericardial cyst	Low	Low	High	No uptake

Clinical case: pericardial cyst

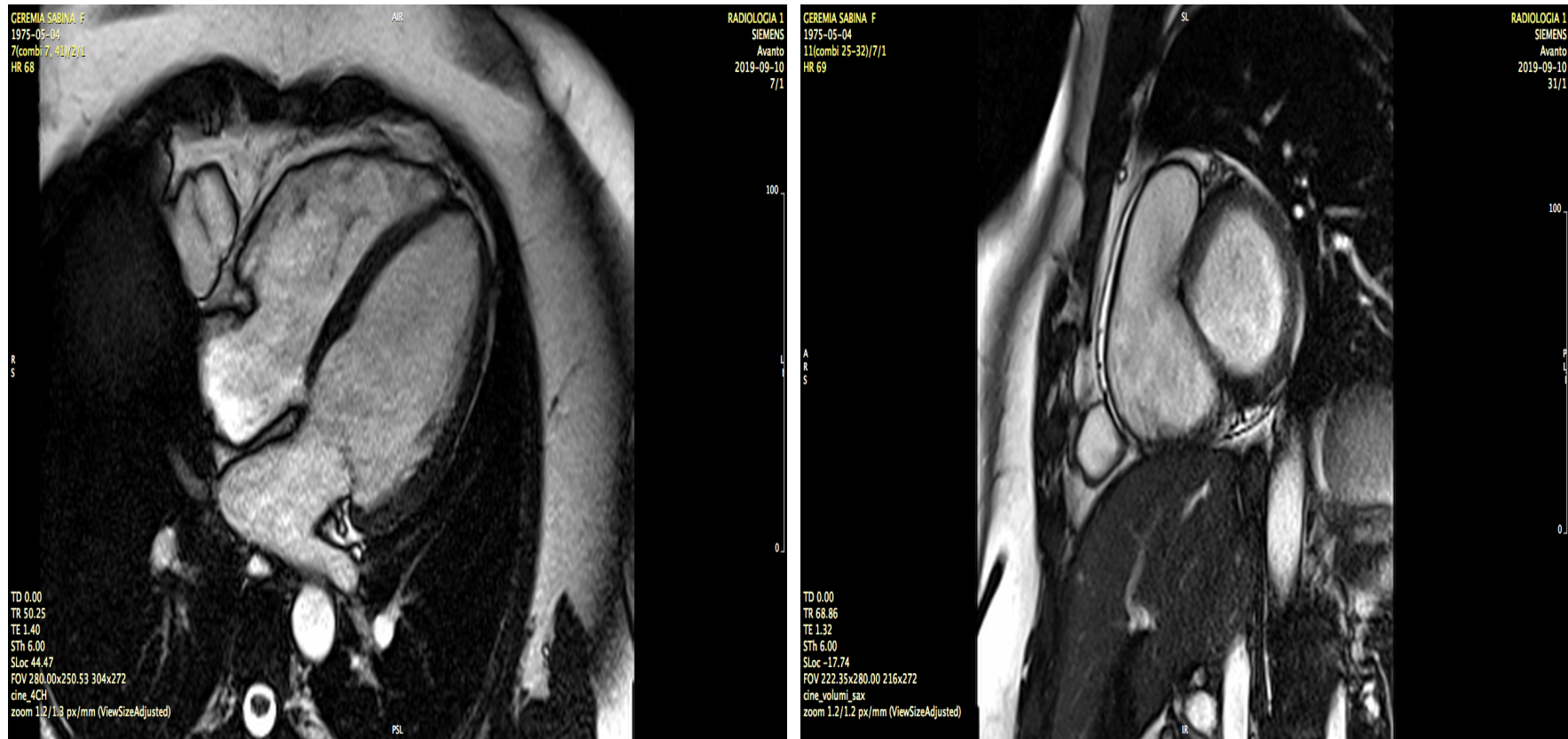
- Female, 45 years old
- Asymptomatic



“Formazione rotondeggiante (39 x 29 mm), sepimentata, paracardiaca destra, in prossimità della parete atriale destra da cui appare ben dissociabile.”

Clinical case: pericardial cyst

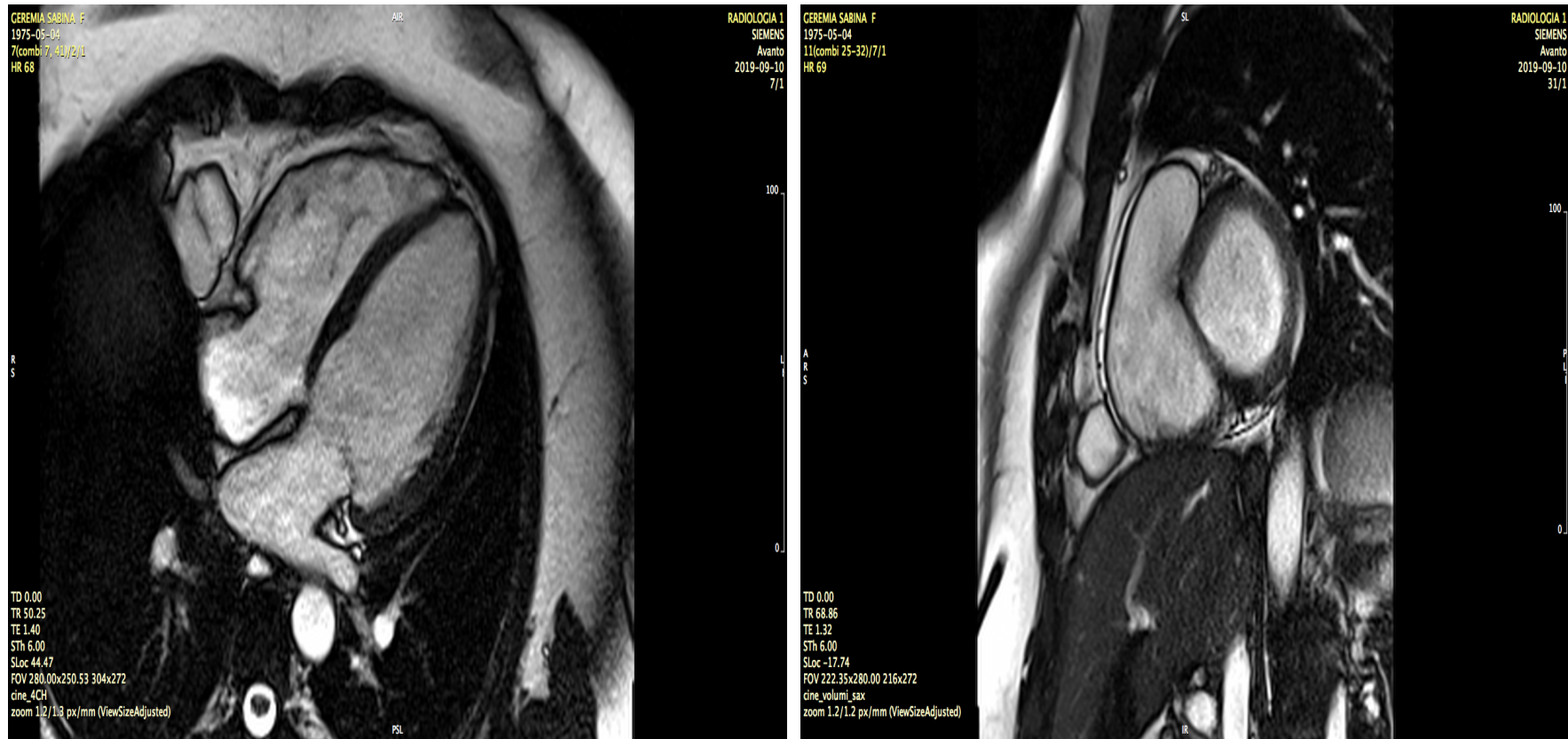
- Female, 45 years old
- Asymptomatic



“Formazione rotondeggiante (39 x 29 mm), sepimentata, paracardiaca destra, in prossimità della parete atriale destra da cui appare ben dissociabile.”

Clinical case: pericardial cyst

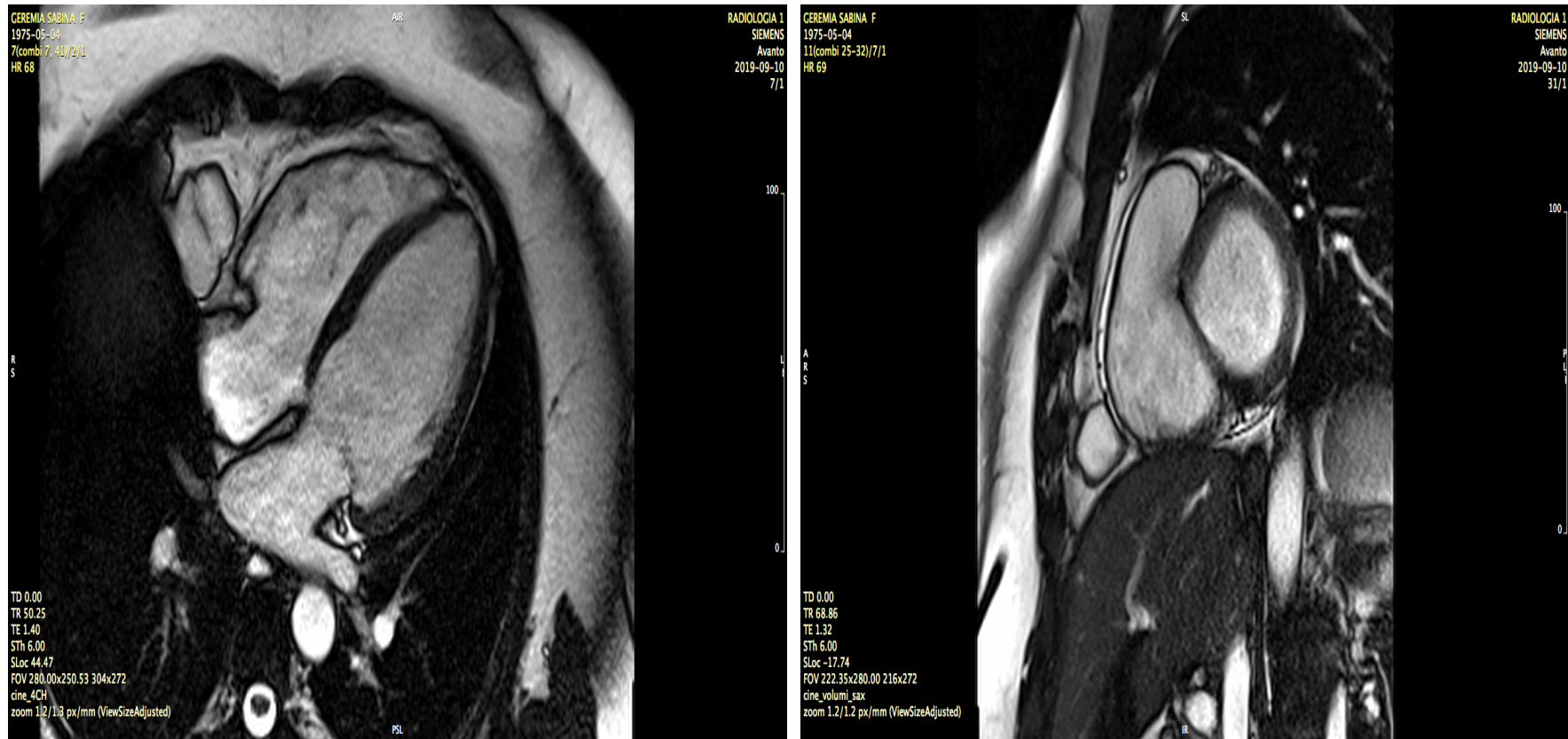
- Female, 45 years old
- Asymptomatic



“Formazione rotondeggiante (39 x 29 mm), sepimentata, paracardiaca destra, in prossimità della parete atriale destra da cui appare ben dissociabile.”

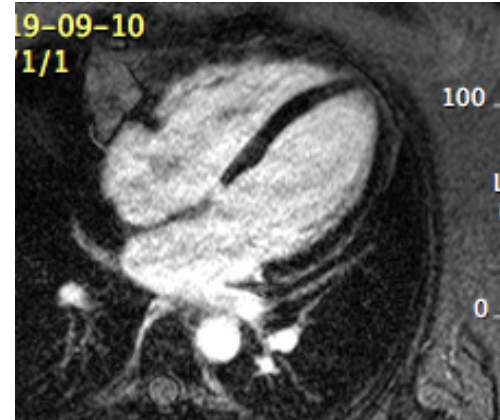
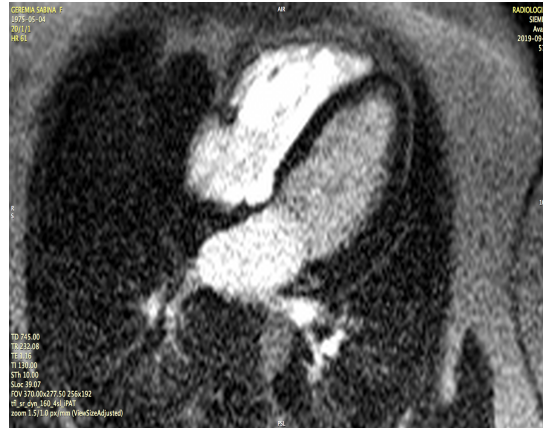
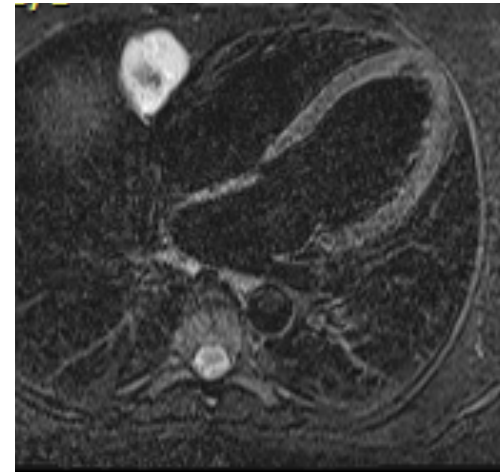
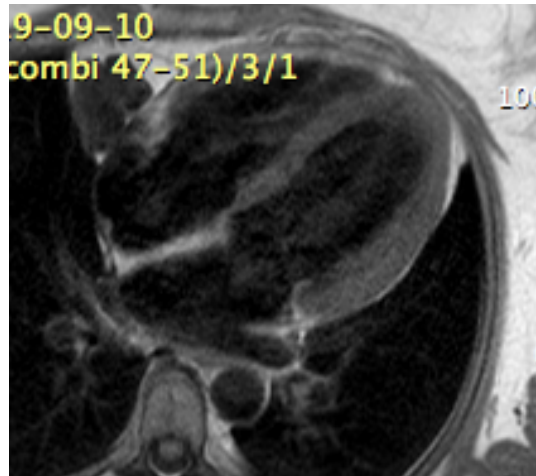
Clinical case: pericardial cyst

- Female, 45 years old
- Asymptomatic



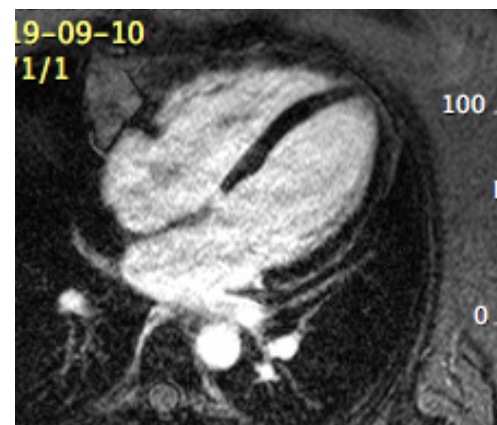
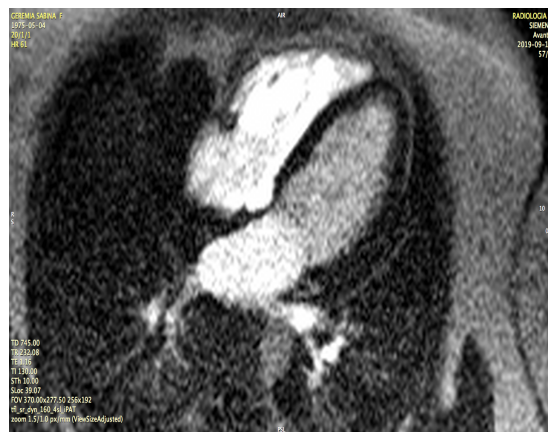
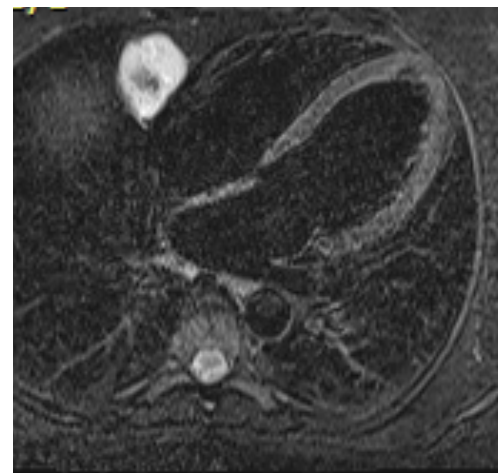
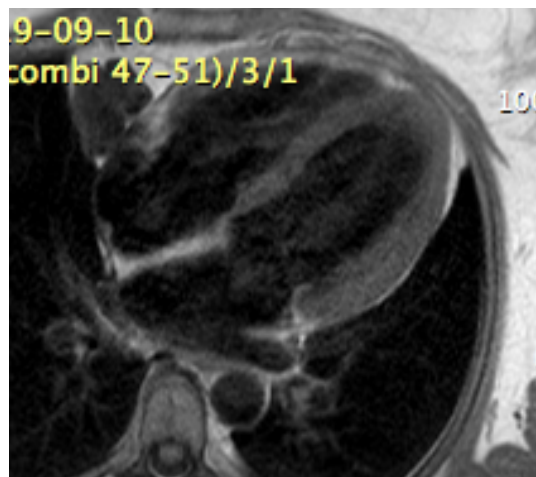
“Formazione rotondeggiante (39 x 29 mm), sepimentata, paracardiaca destra, in prossimità della parete atriale destra da cui appare ben dissociabile.”

Clinical case: pericardial cyst



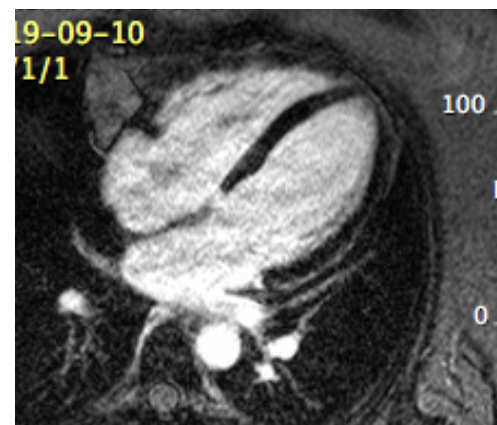
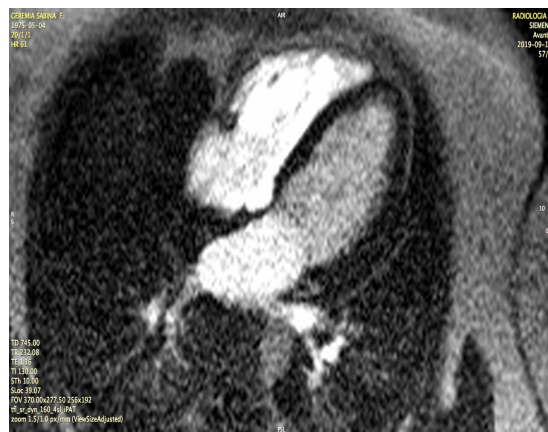
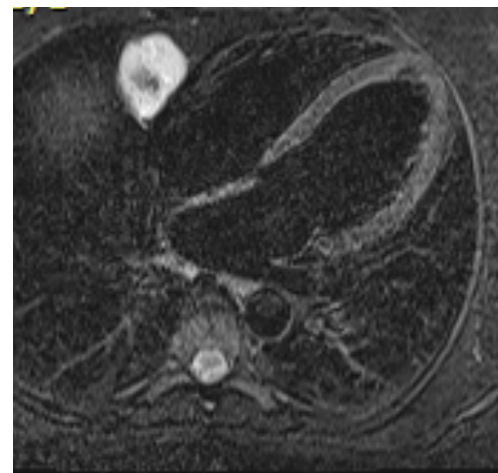
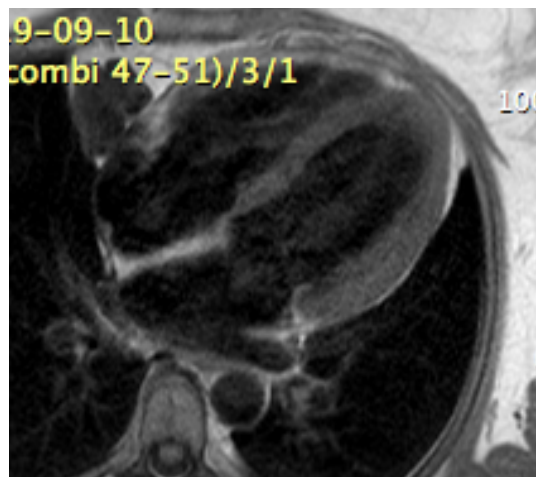
“Formazione ipointensa nelle sequenze T1w, iperintensa nelle sequenze T2w, non perfusa dopo somministrazione precoce di mdc (first pass), di aspetto disomogeneo nelle sequenze post contrastografiche tardive. Conclusioni: formazione compatibile con cisti pericardica.”

Clinical case: pericardial cyst



“Formazione ipointensa nelle sequenze T1w, iperintensa nelle sequenze T2w, non perfusa dopo somministrazione precoce di mdc (first pass), di aspetto disomogeneo nelle sequenze post contrastografiche tardive. Conclusioni: formazione compatibile con cisti pericardica.”

Clinical case: pericardial cyst



“Formazione ipointensa nelle sequenze T1w, iperintensa nelle sequenze T2w, non perfusa dopo somministrazione precoce di mdc (first pass), di aspetto disomogeneo nelle sequenze post contrastografiche tardive. Conclusioni: formazione compatibile con cisti pericardica.”



What are the main cardiac masses?

- Non-tumoral cardiac masses and mimics
- **Metastatic tumors**
- Primary tumors



- Cardiac metastasis are 20—40 times more common than primary cardiac tumors.
- The most common malignancies to spread to the heart are lung and breast cancers, lymphoma, and malignant melanoma.
- Metastatic spread to the heart can occur by direct invasion (lung, breast, esophagus), hematogenous (melanoma, lymphoma, leukemia), transvenous via the great veins (renal cell carcinoma, hepato-carcinoma), or via mediastinal lymphatics.
- The most common site of involvement is the pericardium (usually from direct invasion or lymphatic spread) and malignant pericardial effusions are the most common consequence of cardiac metastasis. Usually, hemorrhagic and exudative pericardial effusions have high signal intensity on T1-w images.
- Intramural myocardial metastases tend to be the result of hematogenous spread from melanoma or lymphoma.
- Transvenous spread leads to intracardiac metastases, such as in the right atrium from renal cell carcinoma via the inferior vena cava.

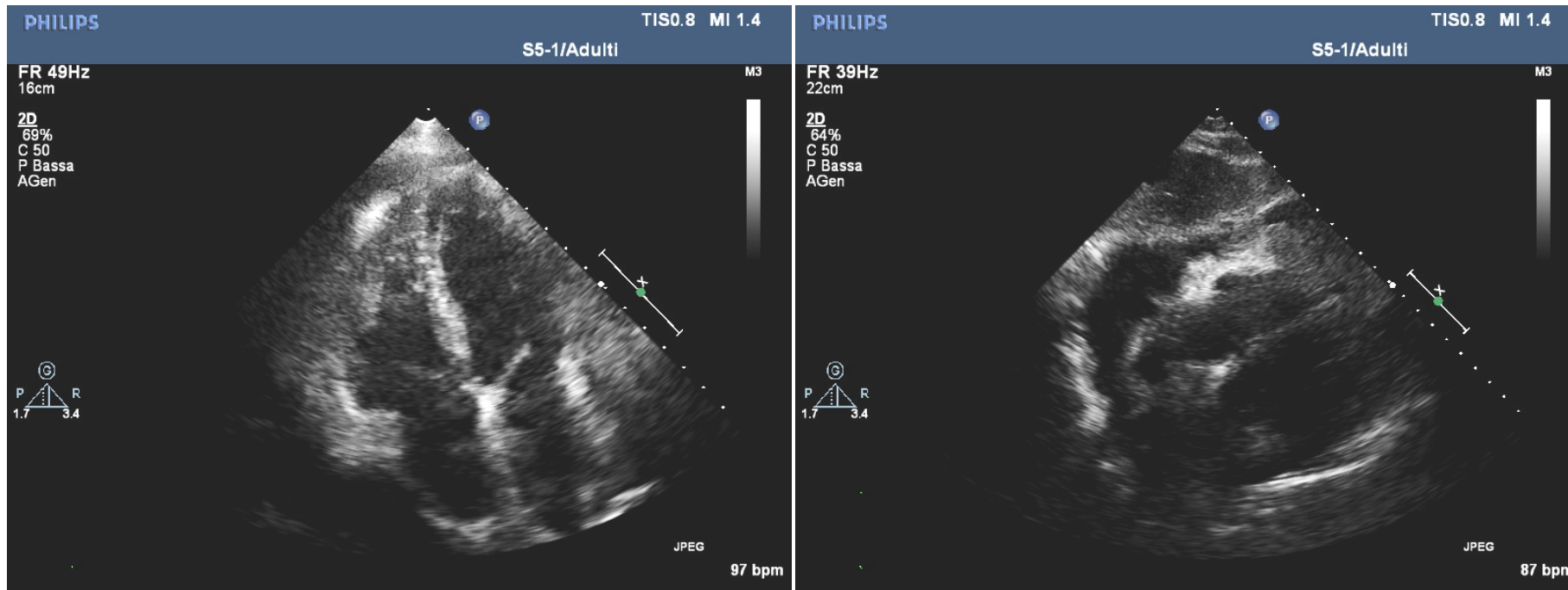


- Although cardiac metastasis do not have any specific appearances, they generally have low signal intensity on T1-w images and high signal intensity on T2-w images —with the exception of melanoma metastases, which may appear bright on T1-weighted images, because the amount of

Malignant				
Cardiac Mass	T1w*	T1w fat sat*	T2w*	LGE
Metastasis §	Low	Low	High	Heterogeneous

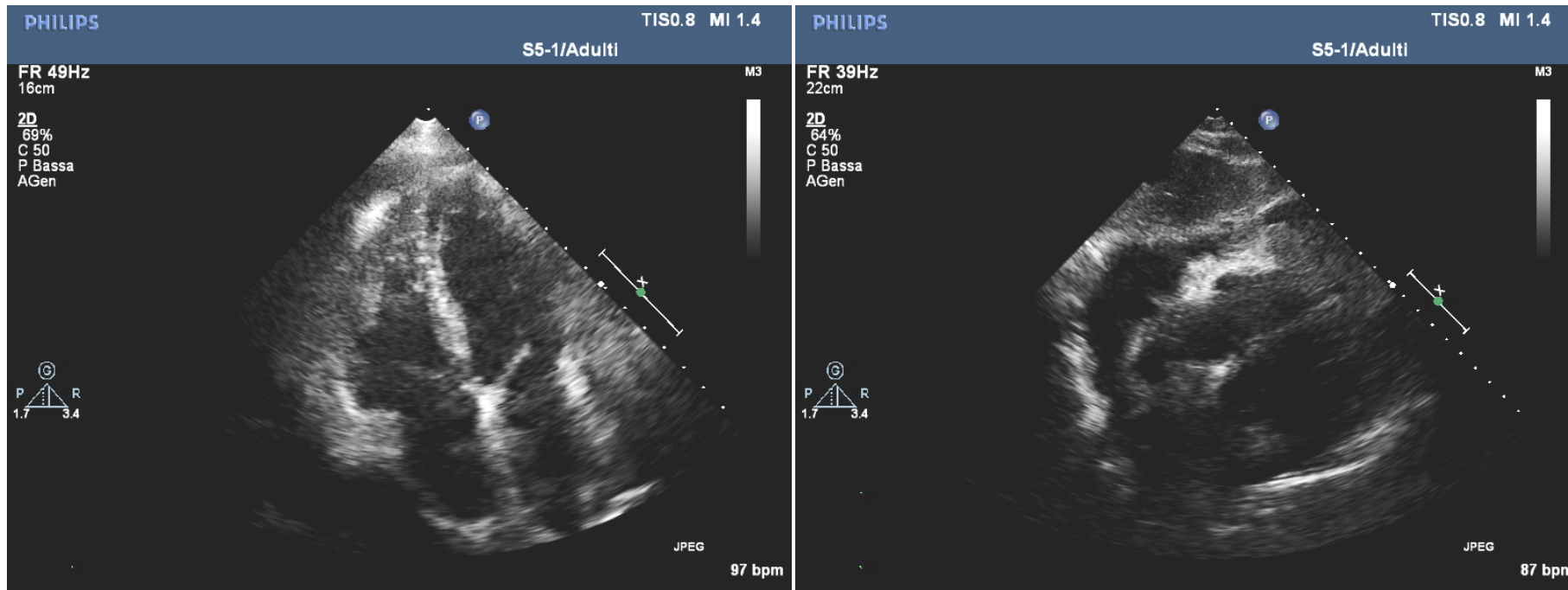
Clinical case: adenocarcinoma metastasis

- Female, 75 years old
- Hypertension and paroxysmal atrial fibrillation
- Previous colon adenocarcinoma
- Previous melanoma



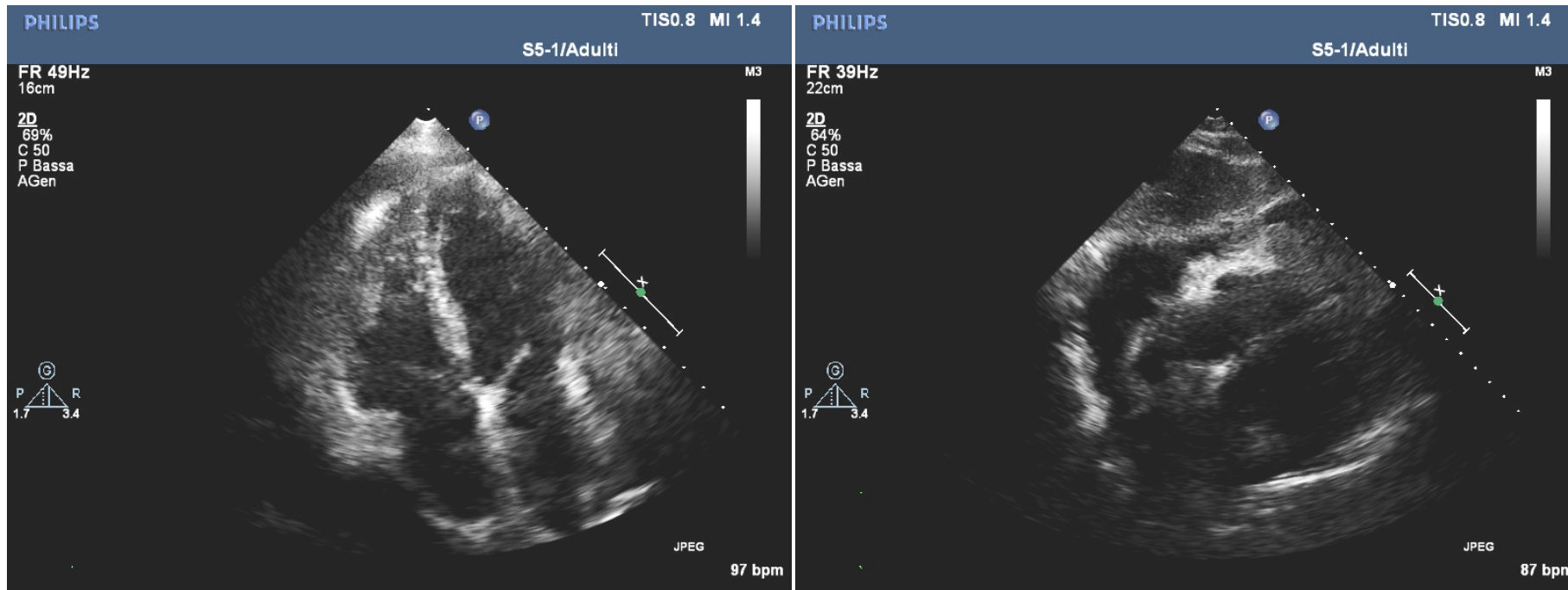
Clinical case: adenocarcinoma metastasis

- Female, 75 years old
- Hypertension and paroxysmal atrial fibrillation
- Previous colon adenocarcinoma
- Previous melanoma

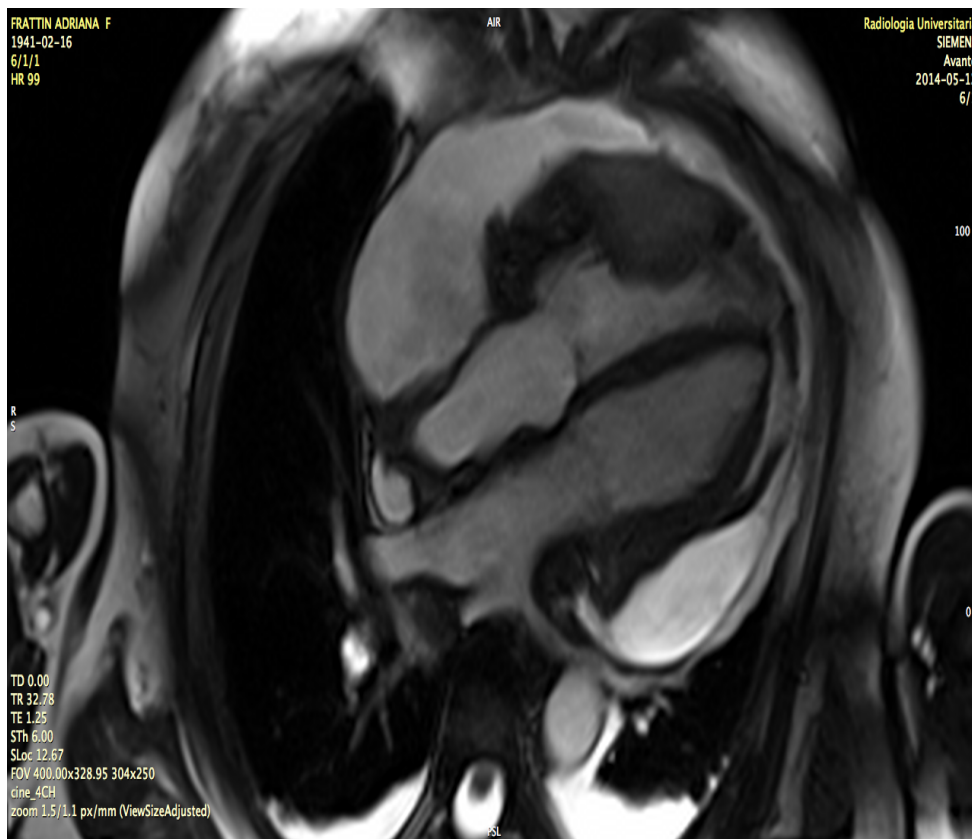


Clinical case: adenocarcinoma metastasis

- Female, 75 years old
- Hypertension and paroxysmal atrial fibrillation
- Previous colon adenocarcinoma
- Previous melanoma

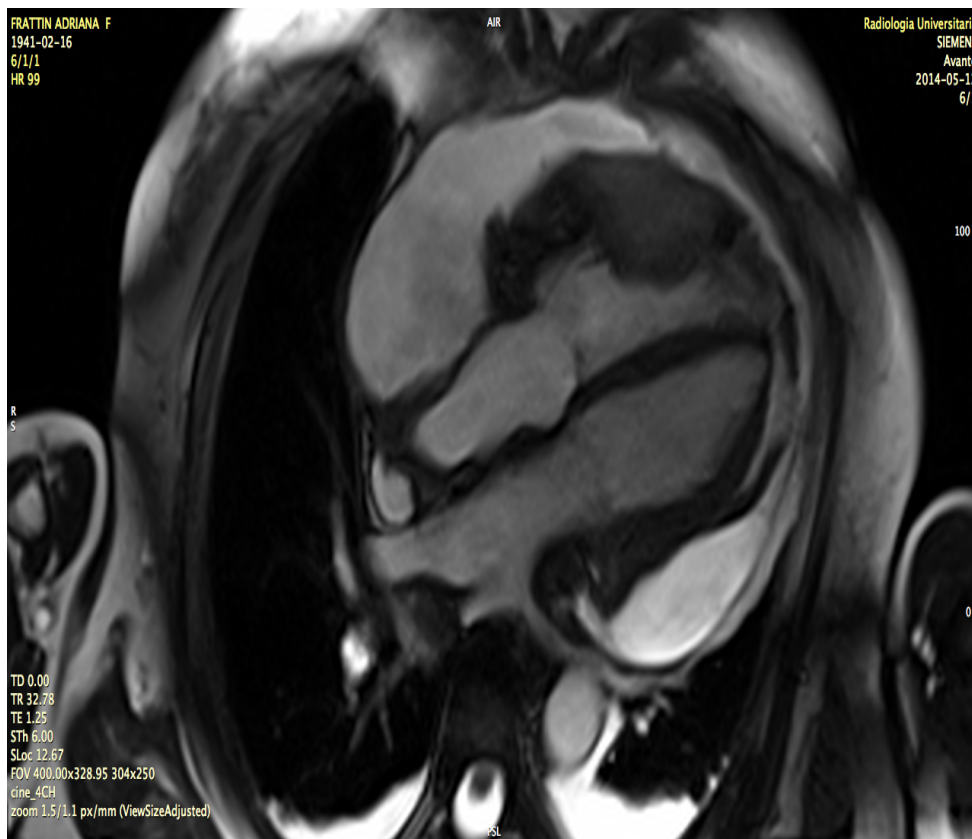


Clinical case: adenocarcinoma metastasis



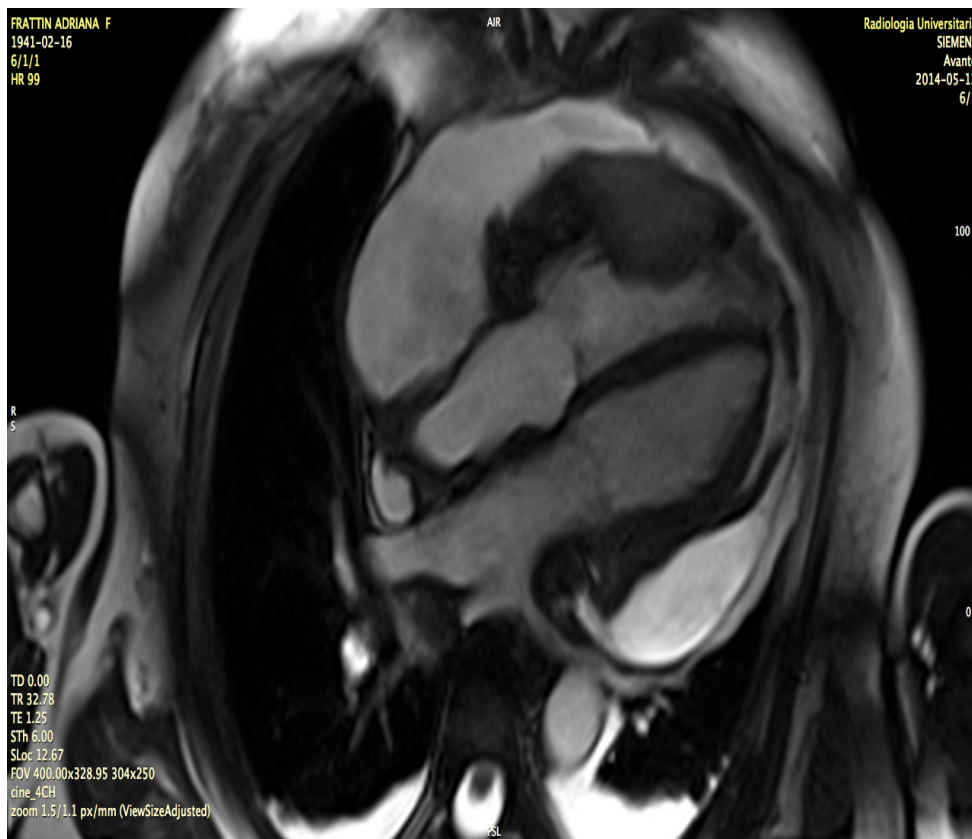
“Formazione espansiva a livello della parete libera del ventricolo destro, non contrattile, di dimensioni massime 6 x 3 x 5 cm, infiltrante la parete stessa. Il pericardio viscerale appare irregolarmente ispessito ed in continuità con la lesione. Versamento pericardico severo. ”

Clinical case: adenocarcinoma metastasis



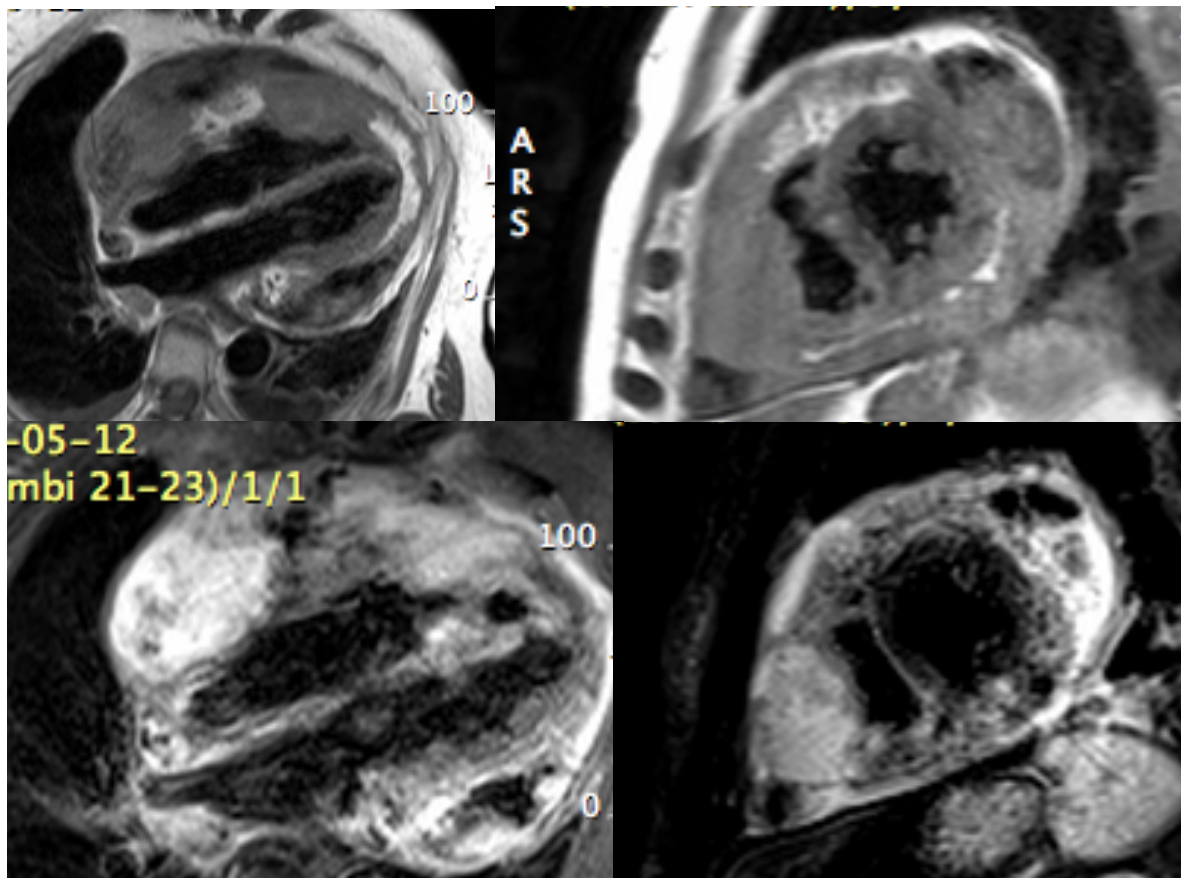
“Formazione espansiva a livello della parete libera del ventricolo destro, non contrattile, di dimensioni massime 6 x 3 x 5 cm, infiltrante la parete stessa. Il pericardio viscerale appare irregolarmente ispessito ed in continuità con la lesione. Versamento pericardico severo. ”

Clinical case: adenocarcinoma metastasis



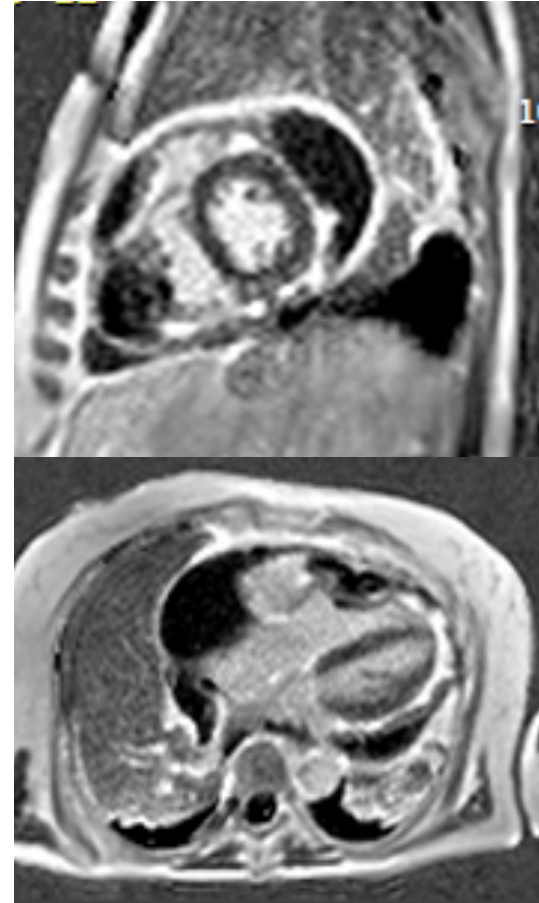
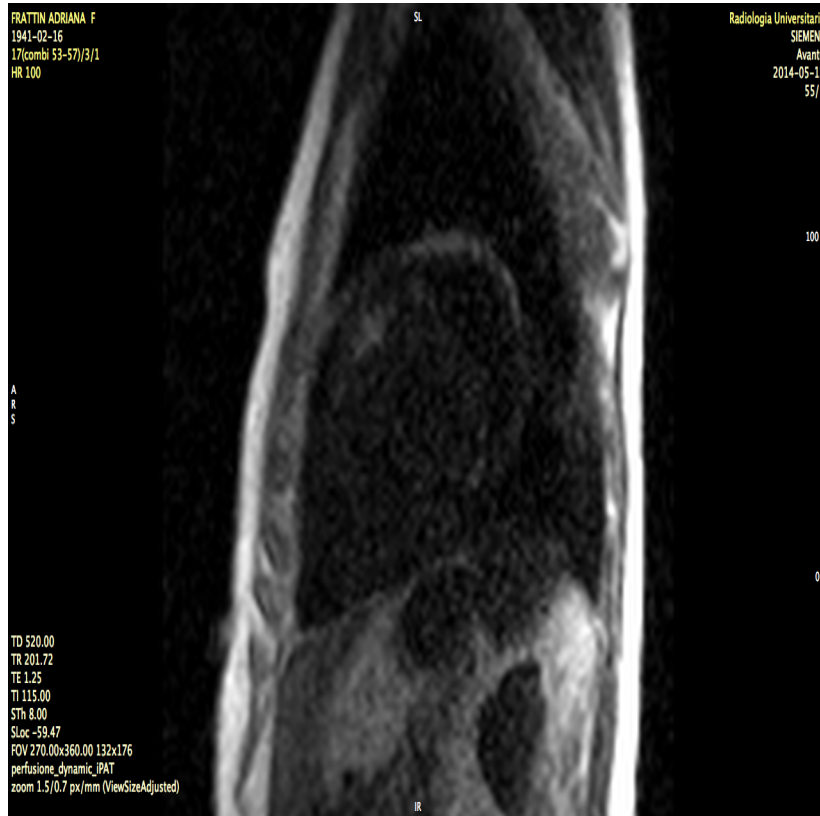“Formazione espansiva a livello della parete libera del ventricolo destro, non contrattile, di dimensioni massime 6 x 3 x 5 cm, infiltrante la parete stessa. Il pericardio viscerale appare irregolarmente ispessito ed in continuità con la lesione. Versamento pericardico severo. ”

Clinical case: adenocarcinoma metastasis



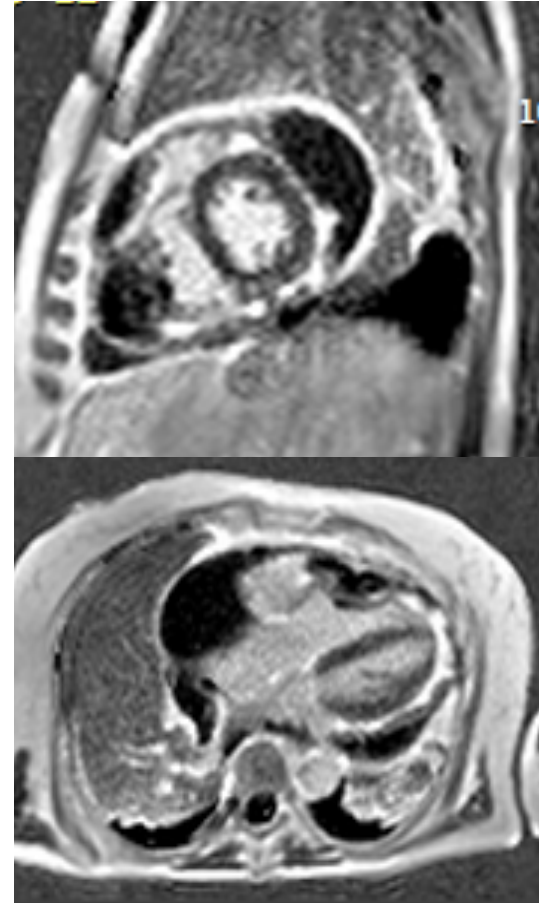
“Nelle sequenze T1-W formazione disomogeneamente isointensa al miocardico, con aree iperintense; nelle sequenze T2w disomogeneamente iperintensa”

Clinical case: adenocarcinoma metastasis



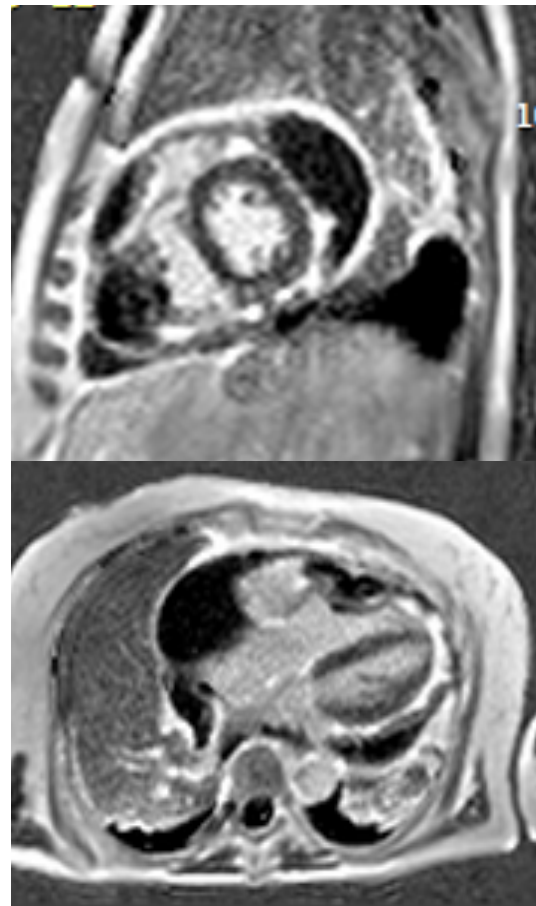
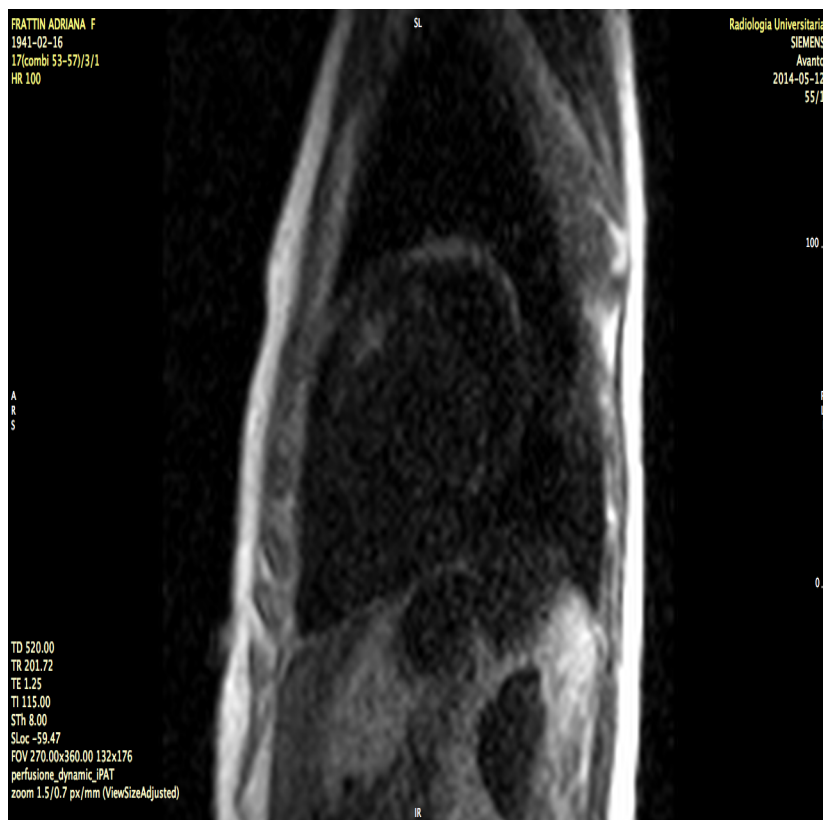
“Dopo mdc in fase precoce (first pass) visibile perfusione periferica; dopo iniezione di mdc in fase tardiva, disomogeneo enhancement, soprattutto alla periferia. Conclusione: lesione espansiva a contenuto necrotico/emorragico, con compromissione del pericardio.”

Clinical case: adenocarcinoma metastasis



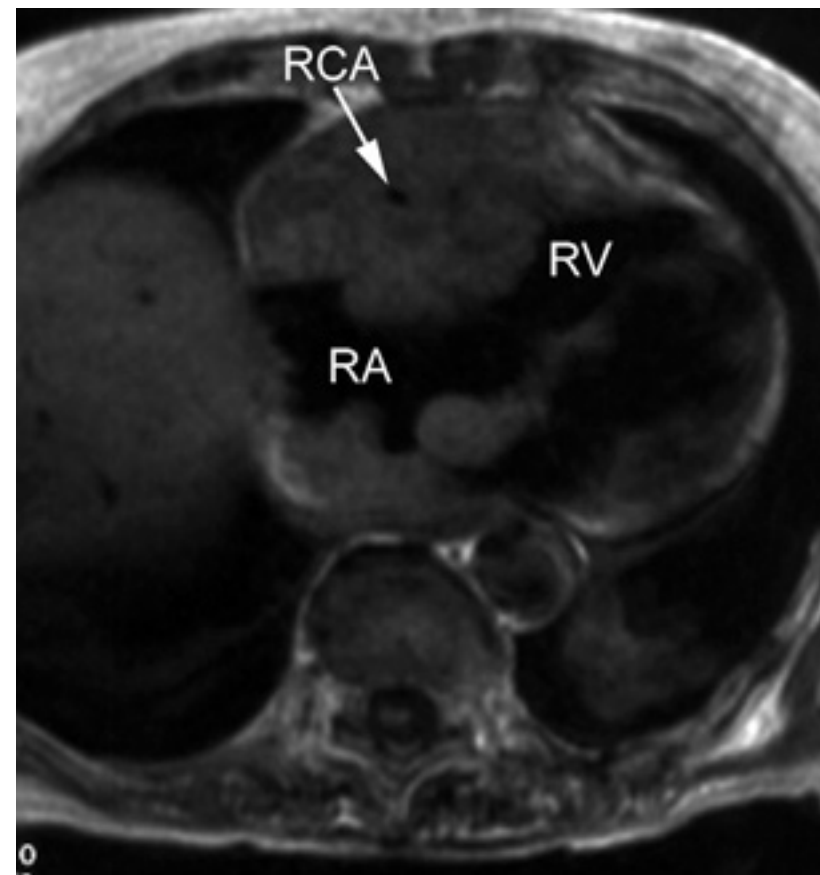
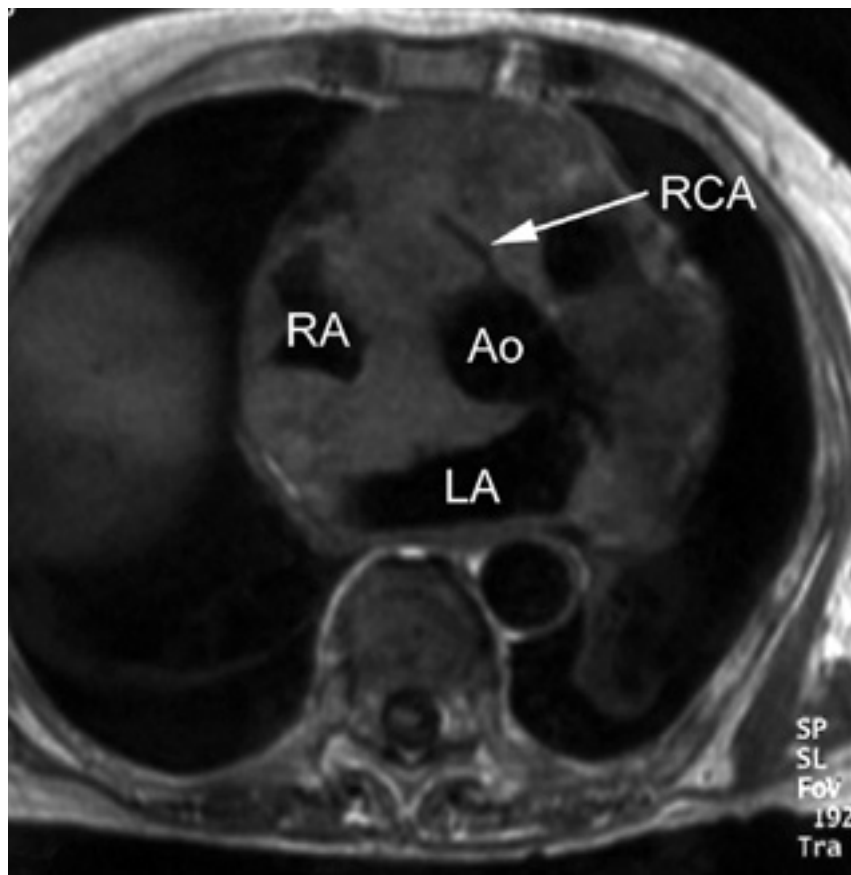
“Dopo mdc in fase precoce (first pass) visibile perfusione periferica; dopo iniezione di mdc in fase tardiva, disomogeneo enhancement, soprattutto alla periferia. Conclusione: lesione espansiva a contenuto necrotico/emorragico, con compromissione del pericardio.”

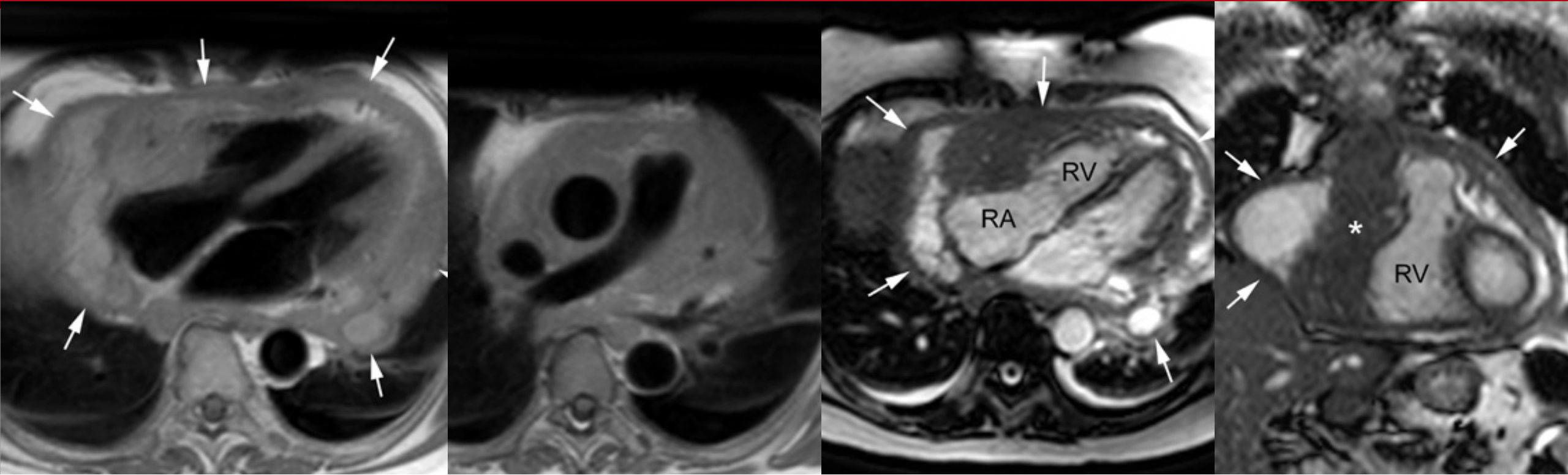
Clinical case: adenocarcinoma metastasis



“Dopo mdc in fase precoce (first pass) visibile perfusione periferica; dopo iniezione di mdc in fase tardiva, disomogeneo enhancement, soprattutto alla periferia. Conclusione: lesione espansiva a contenuto necrotico/emorragico, con compromissione del pericardio.”

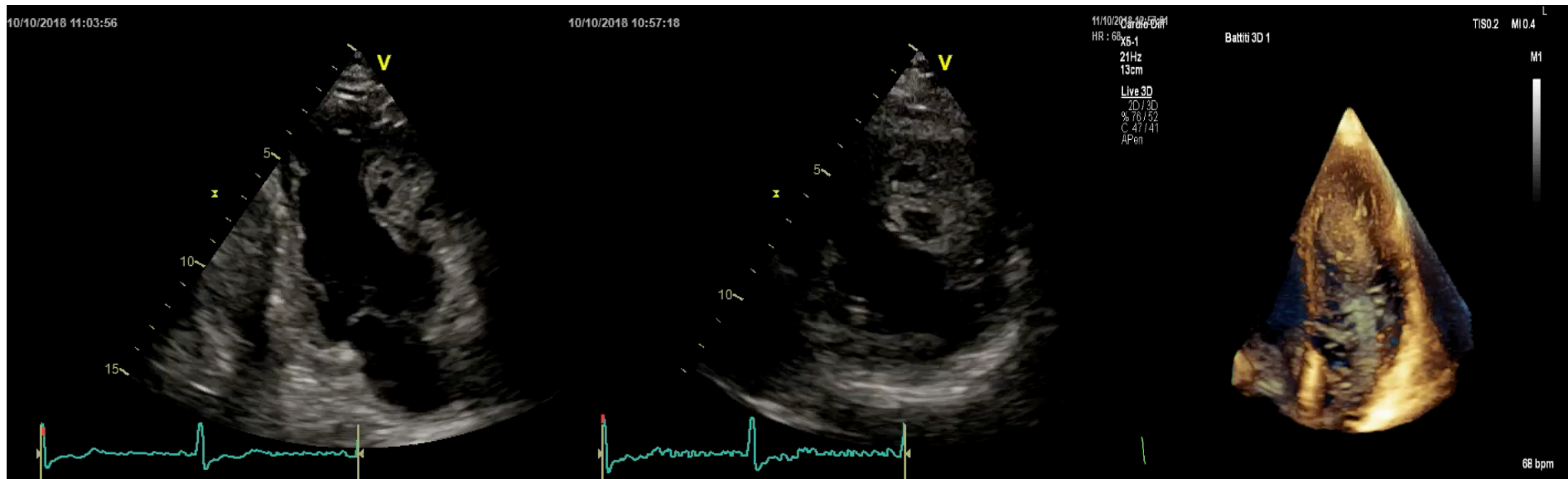
Lymphoma



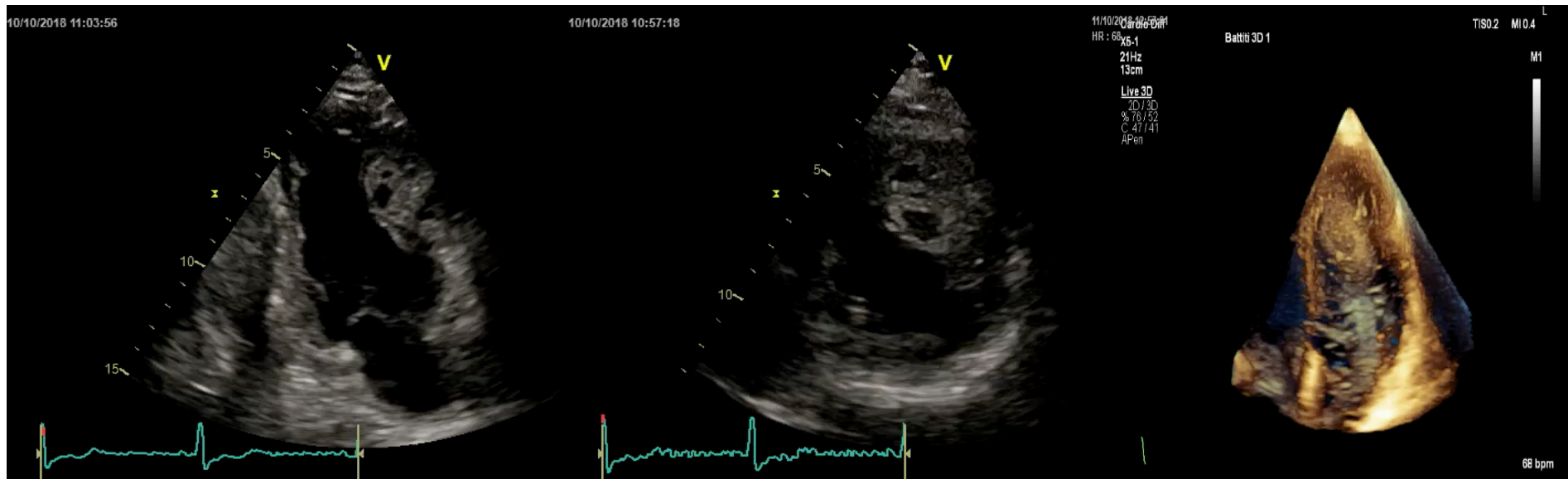


*The pericardium
is diffusely thickened
(arrows) with a rightsided
localized effusion*

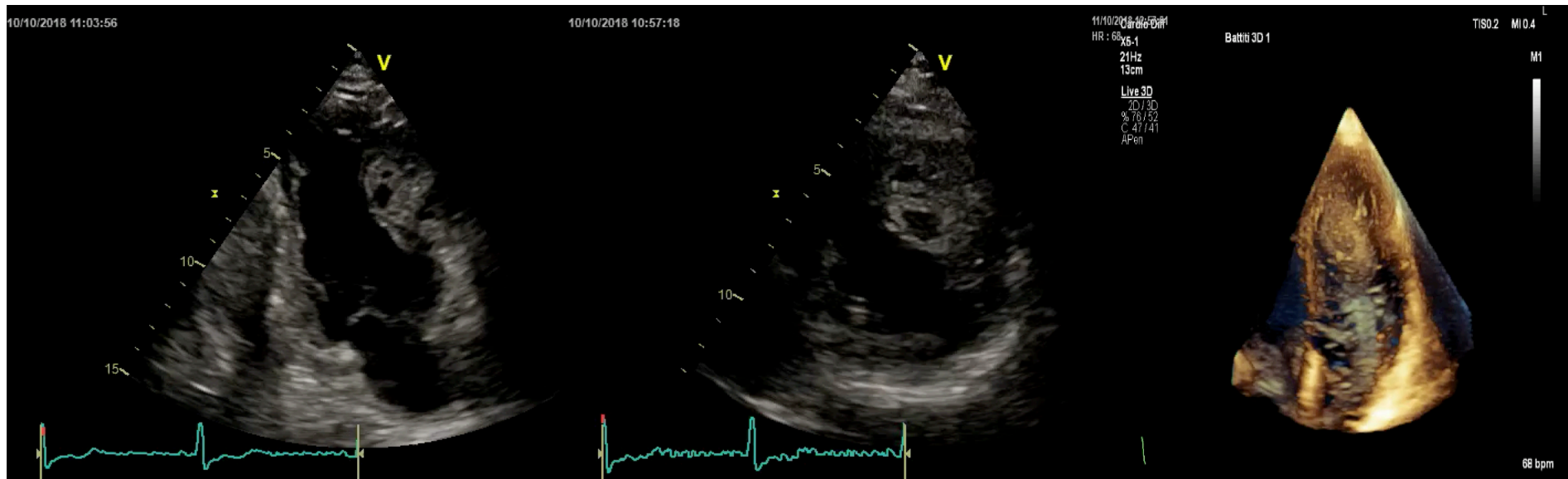
- 62-year-old male
- Prostate cancer, surgically treated 2 years before
- Asymptomatic
- Results of laboratory tests show normal hematocrit level, white blood cell count, liver function tests, and C-reactive protein



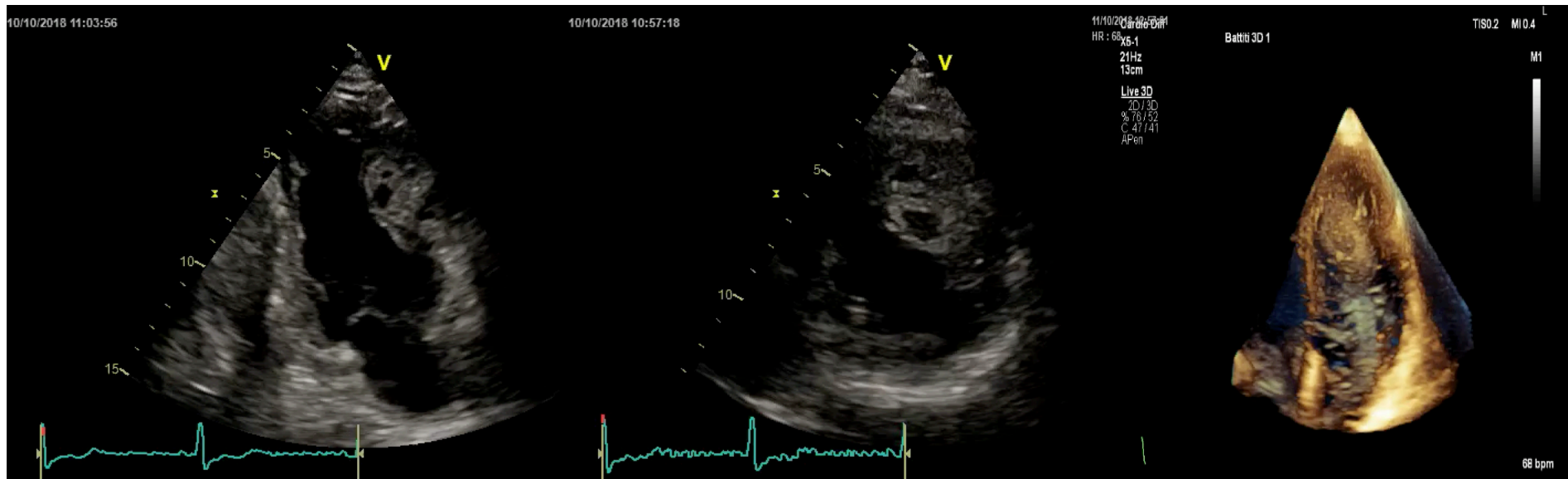
- 62-year-old male
- Prostate cancer, surgically treated 2 years before
- Asymptomatic
- Results of laboratory tests show normal hematocrit level, white blood cell count, liver function tests, and C-reactive protein



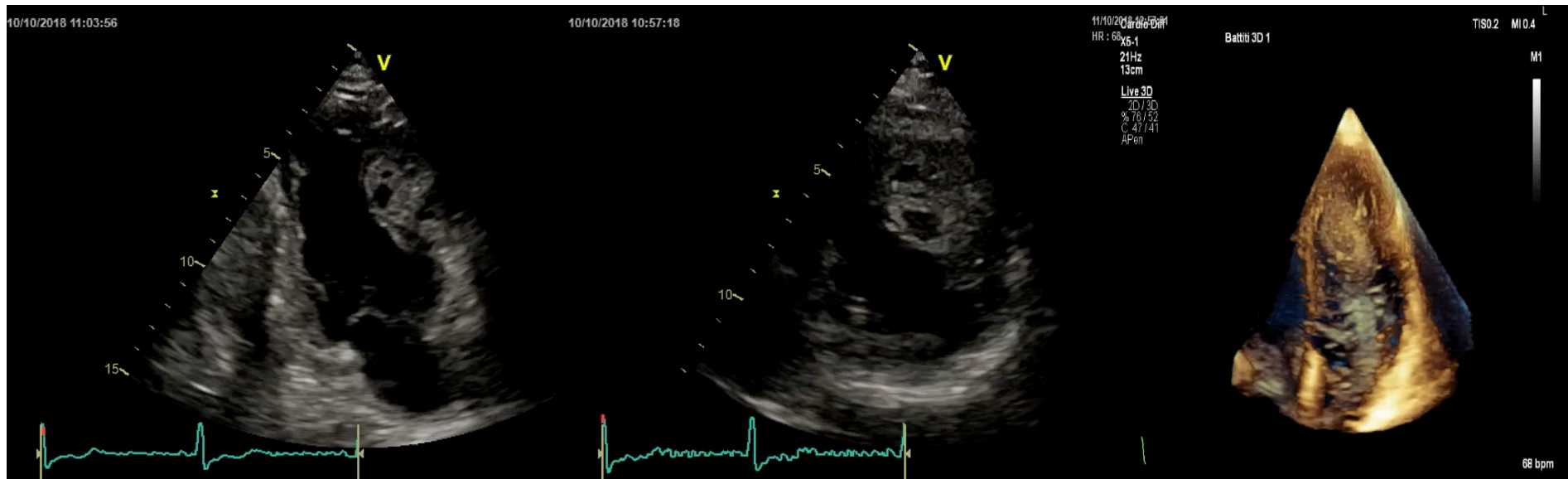
- 62-year-old male
- Prostate cancer, surgically treated 2 years before
- Asymptomatic
- Results of laboratory tests show normal hematocrit level, white blood cell count, liver function tests, and C-reactive protein



- 62-year-old male
- Prostate cancer, surgically treated 2 years before
- Asymptomatic
- Results of laboratory tests show normal hematocrit level, white blood cell count, liver function tests, and C-reactive protein

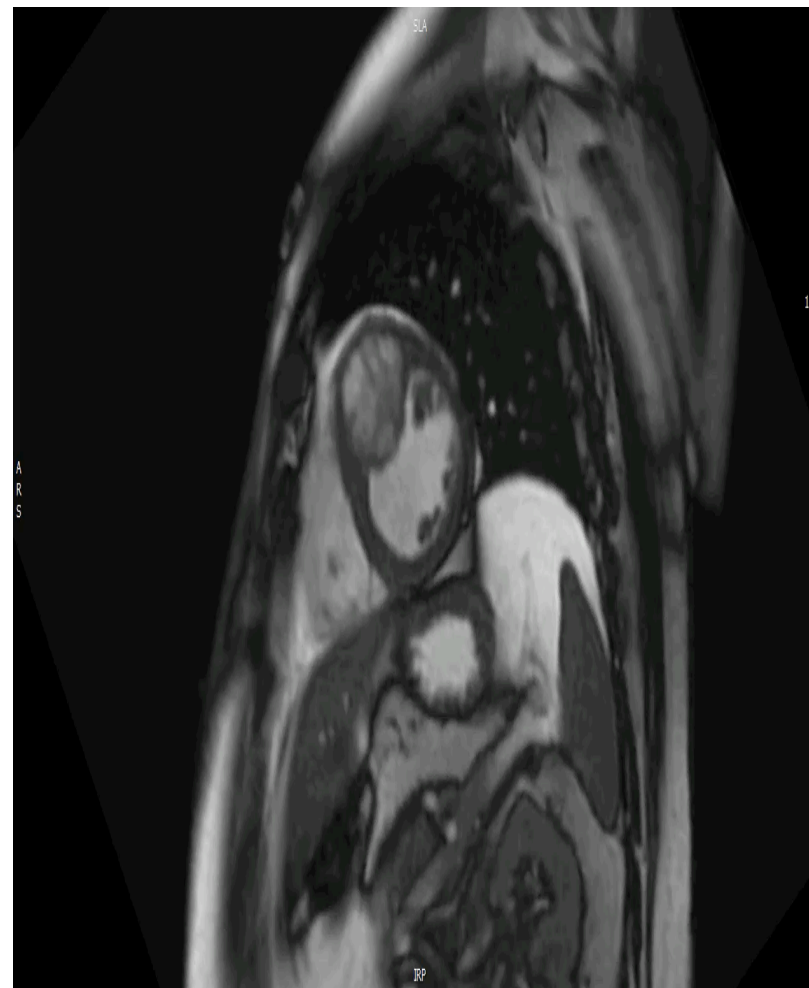
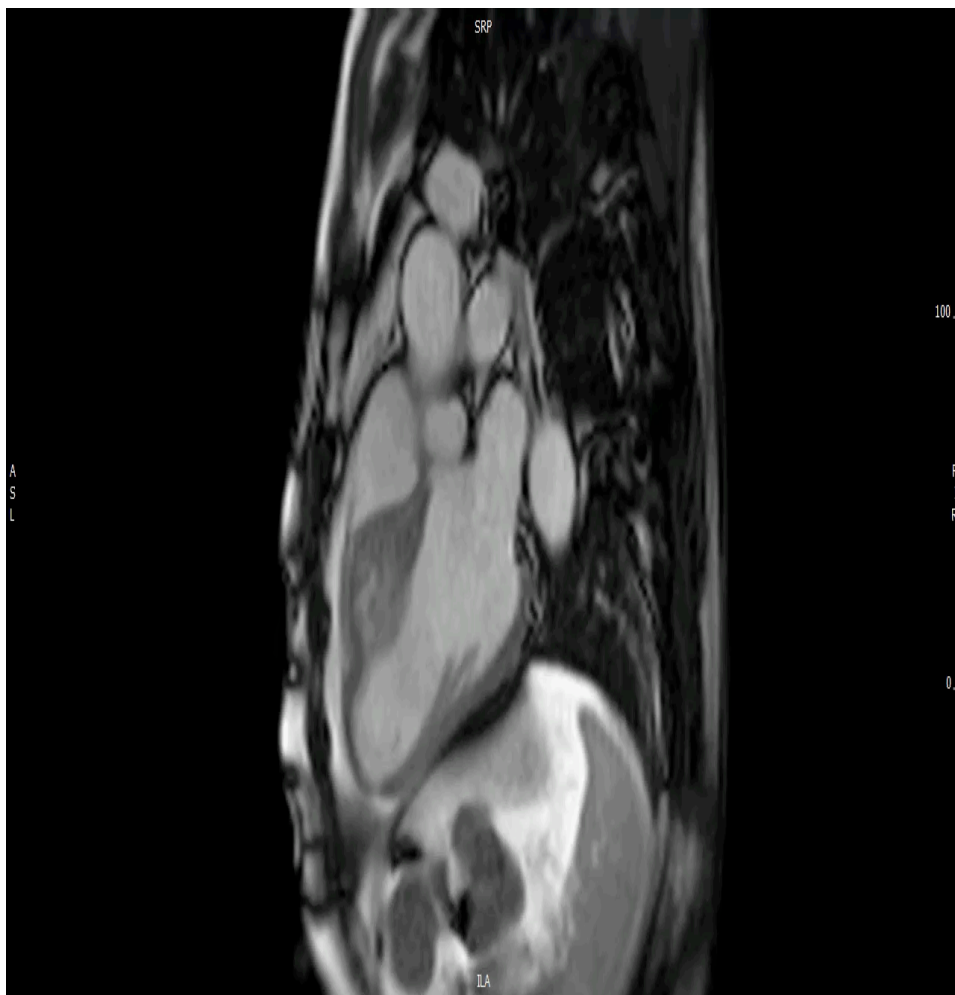


- 62-year-old male
- Prostate cancer, surgically treated 2 years before
- Asymptomatic
- Results of laboratory tests show normal hematocrit level, white blood cell count, liver function tests, and C-reactive protein



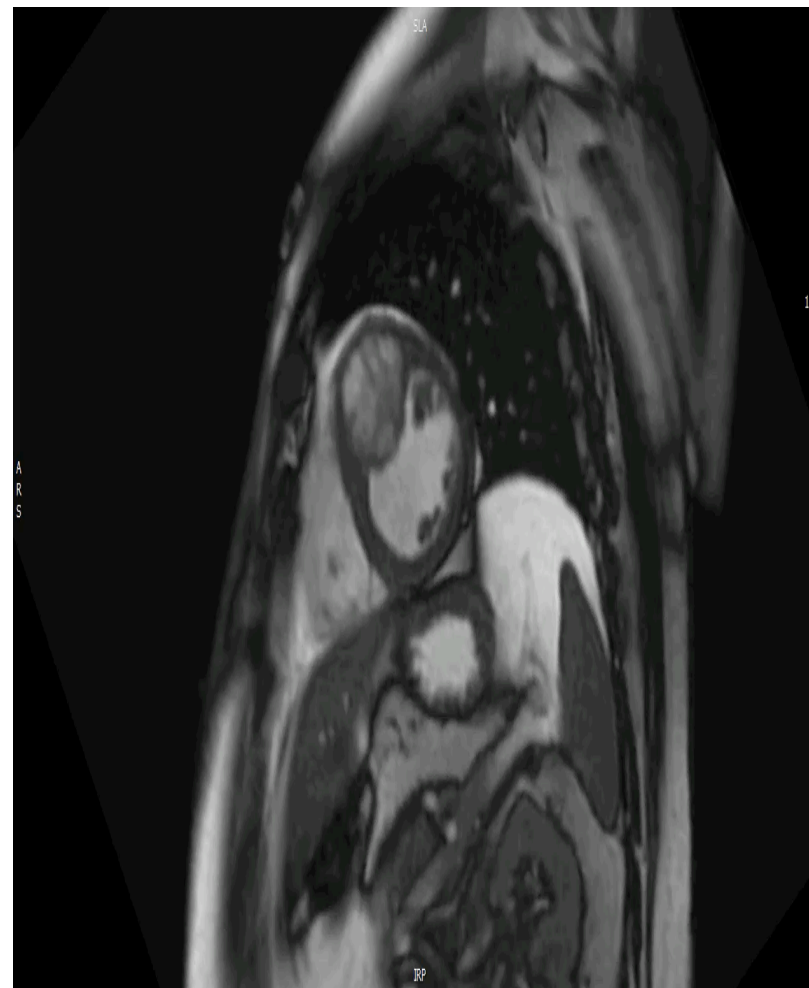


Clinical case: ?



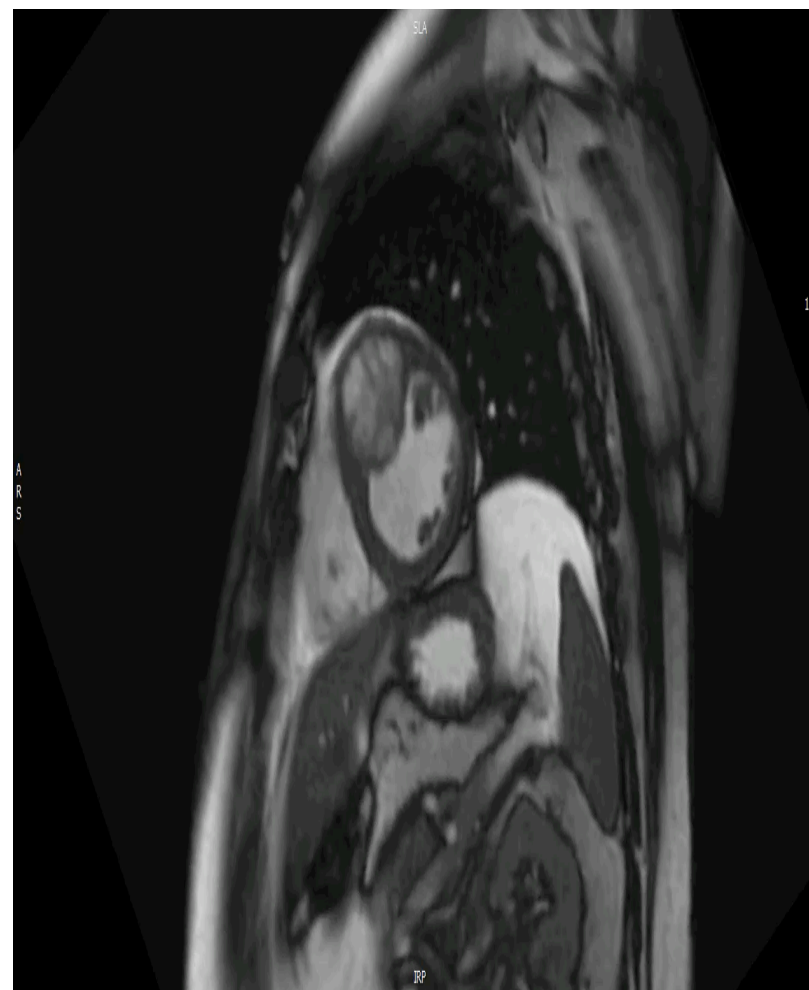
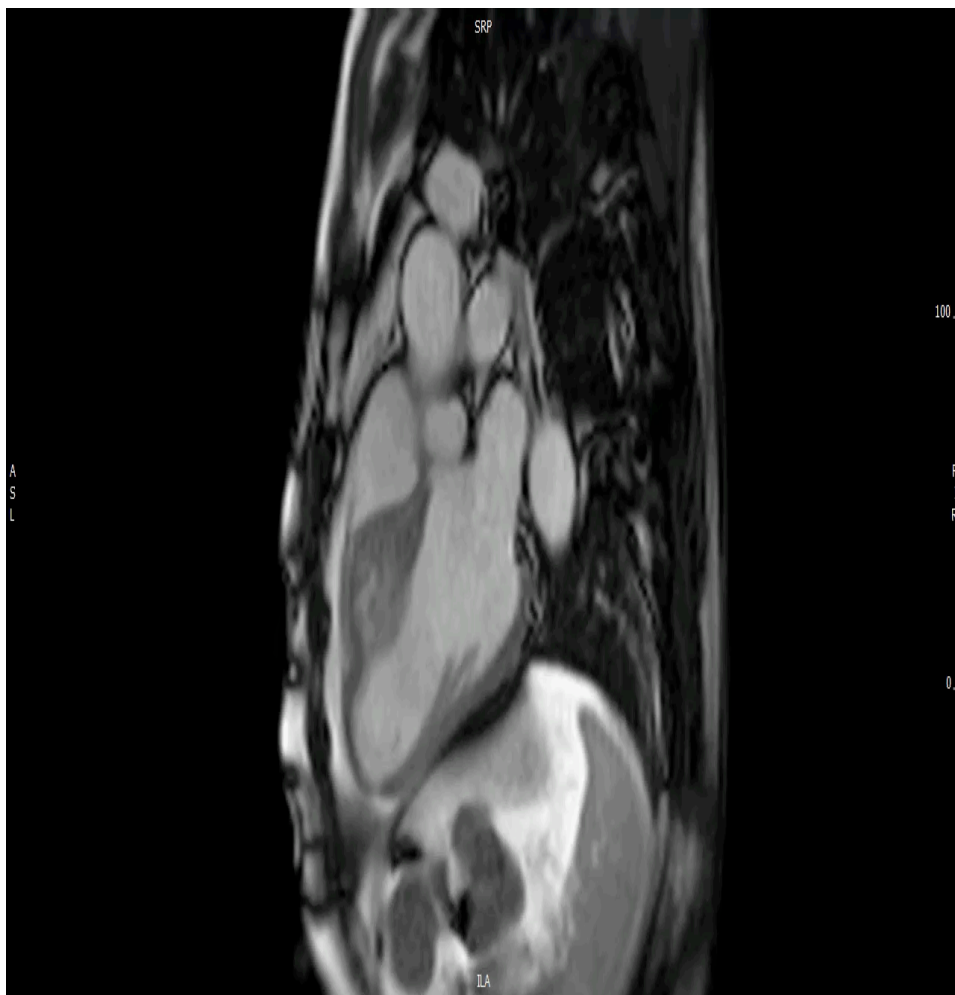


Clinical case: ?



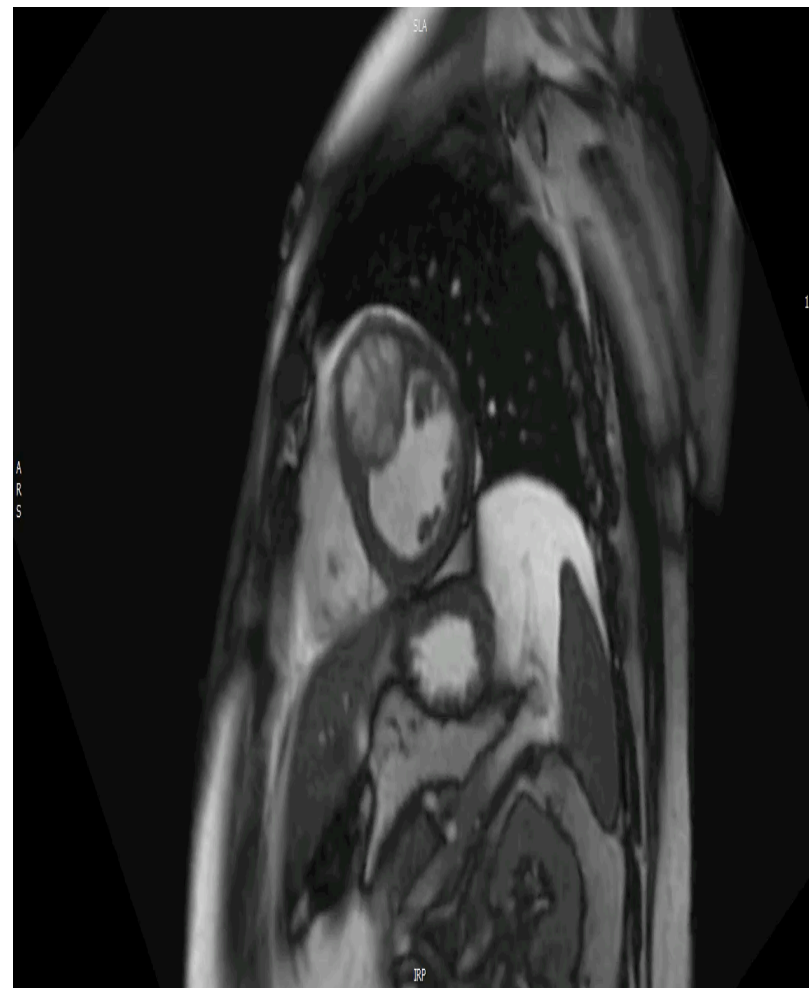
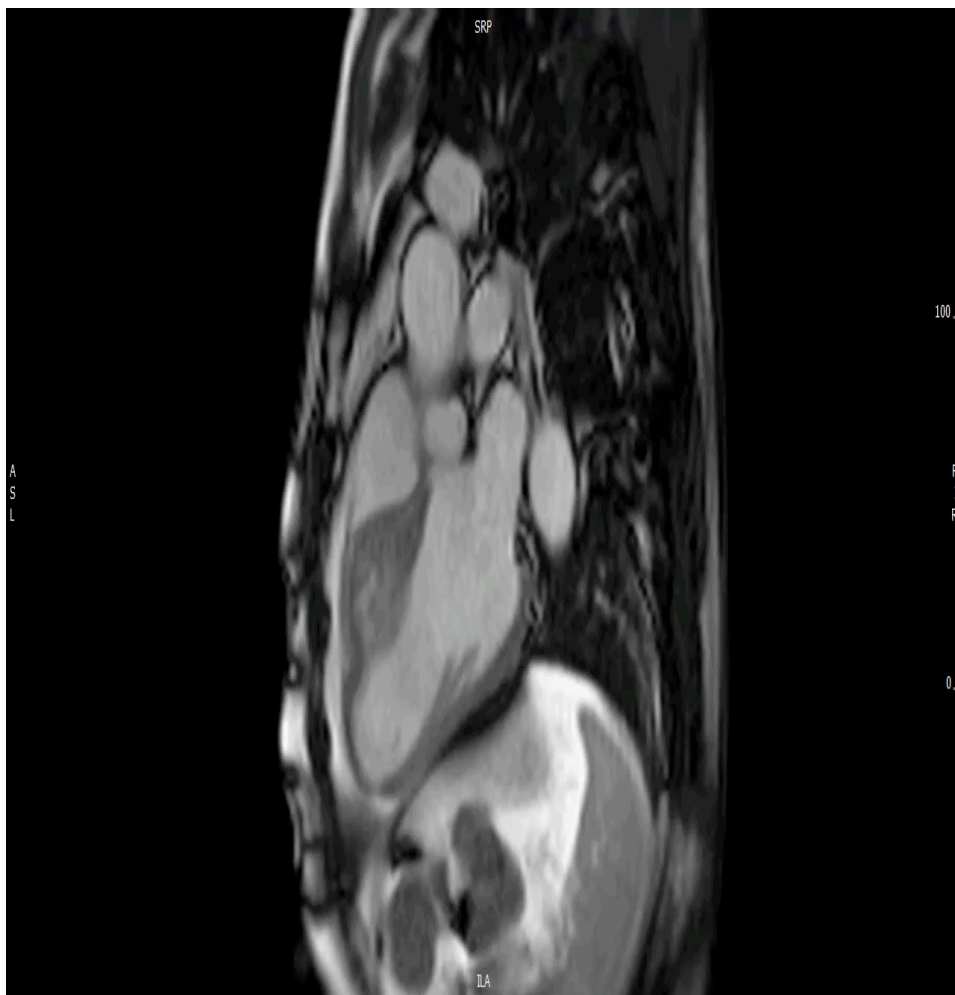


Clinical case: ?



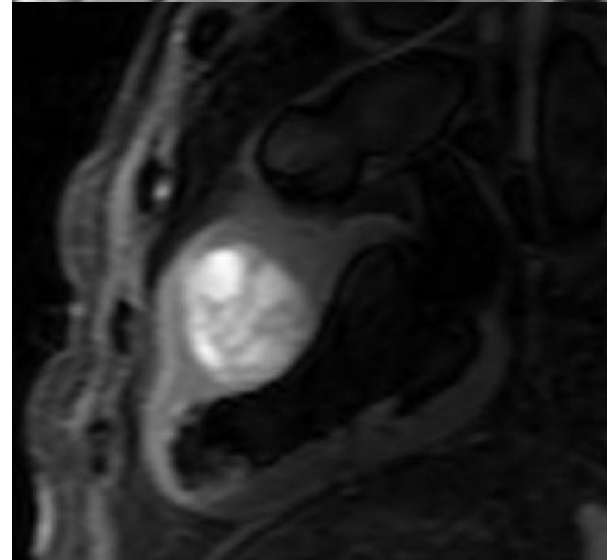
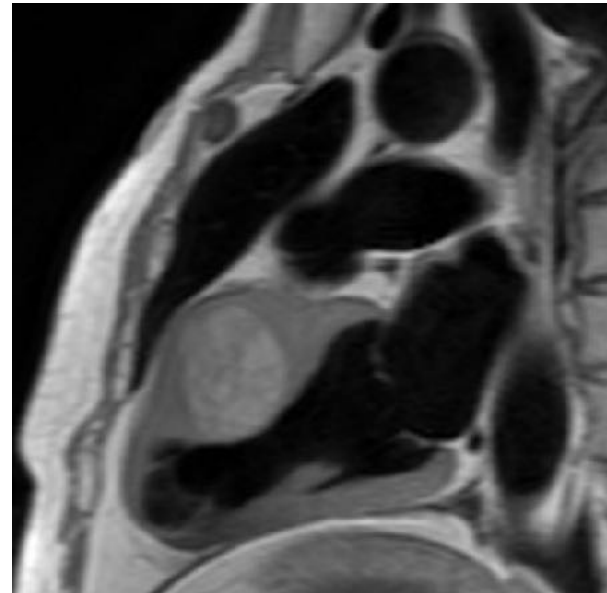
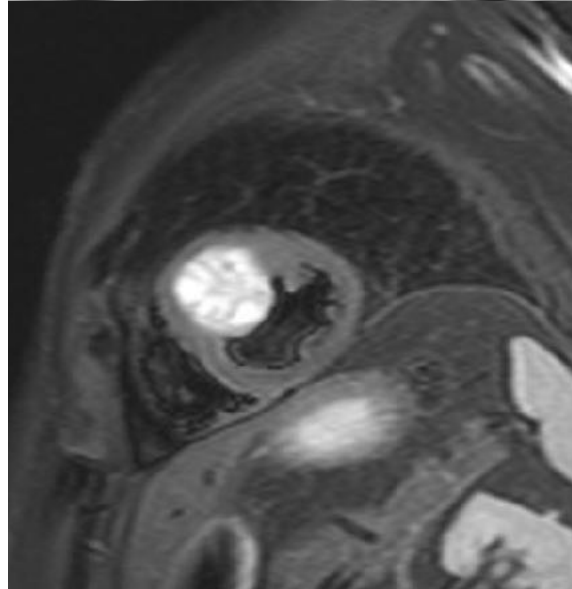
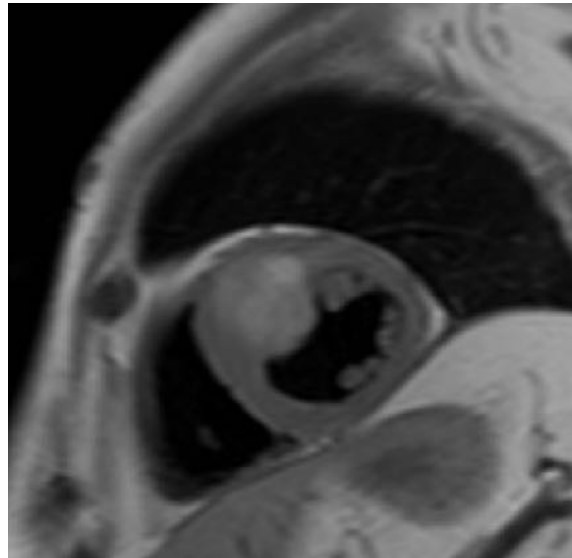


Clinical case: ?



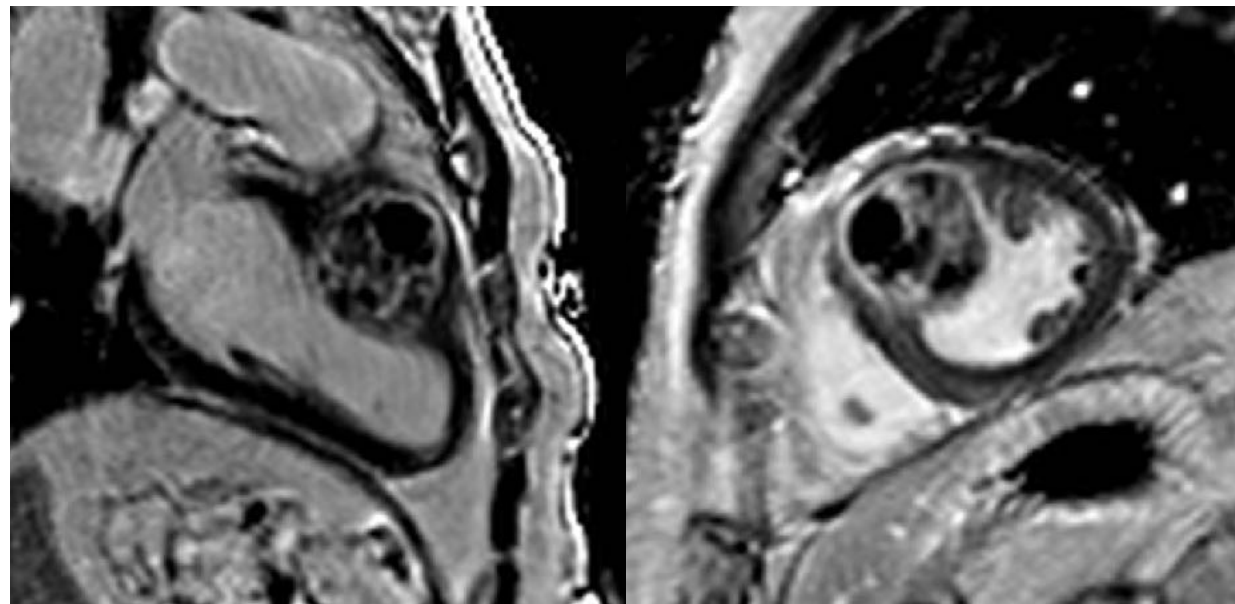
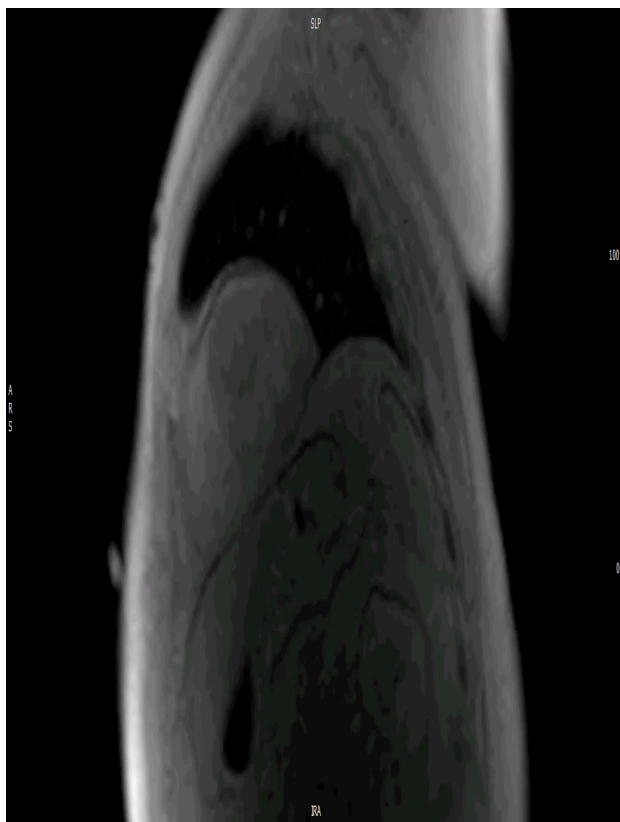


Clinical cases: ?



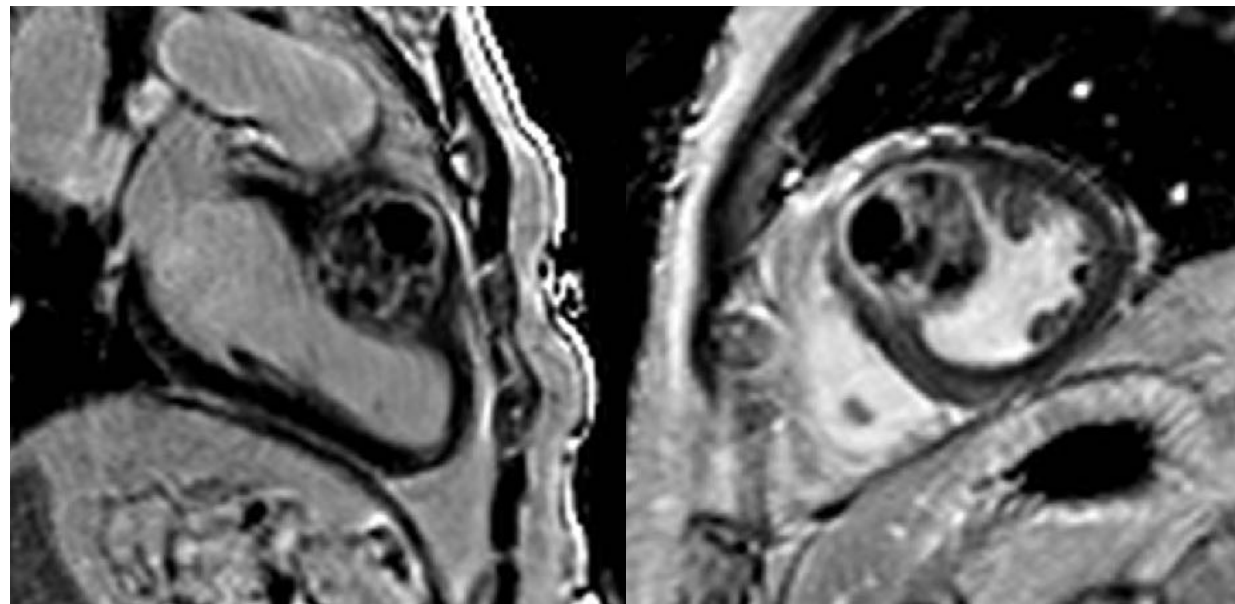
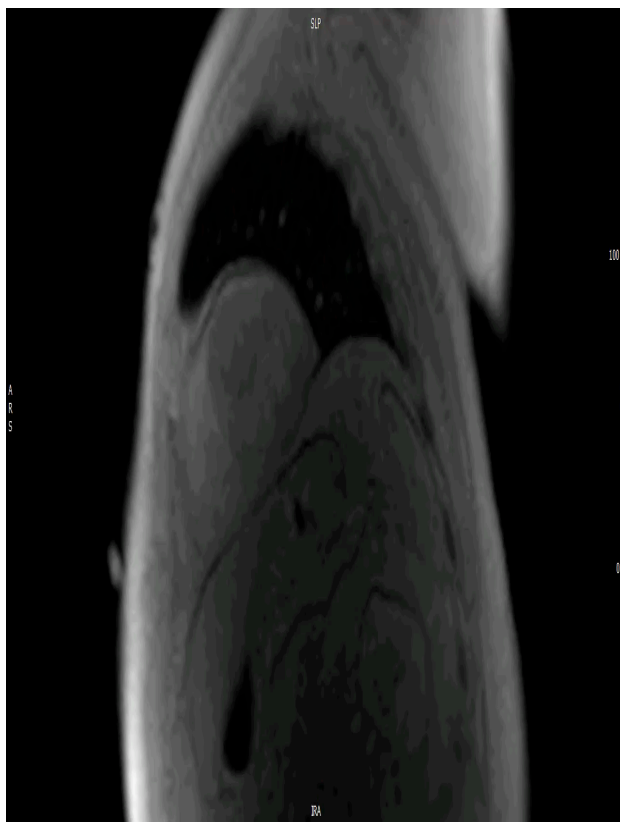


Clinical cases: ?



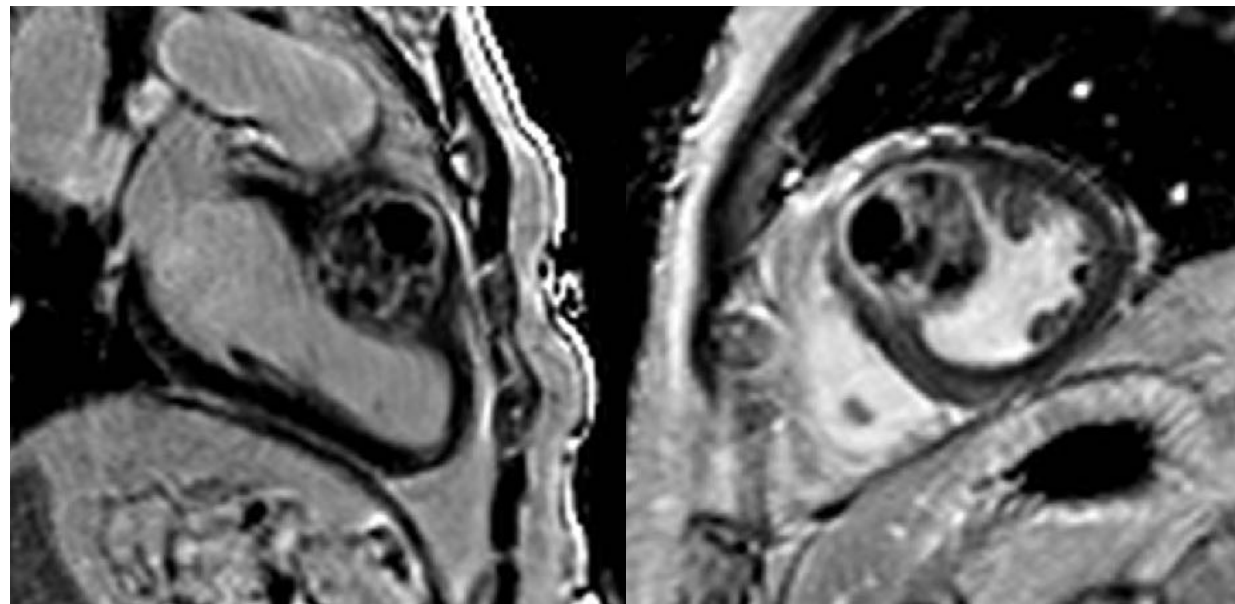
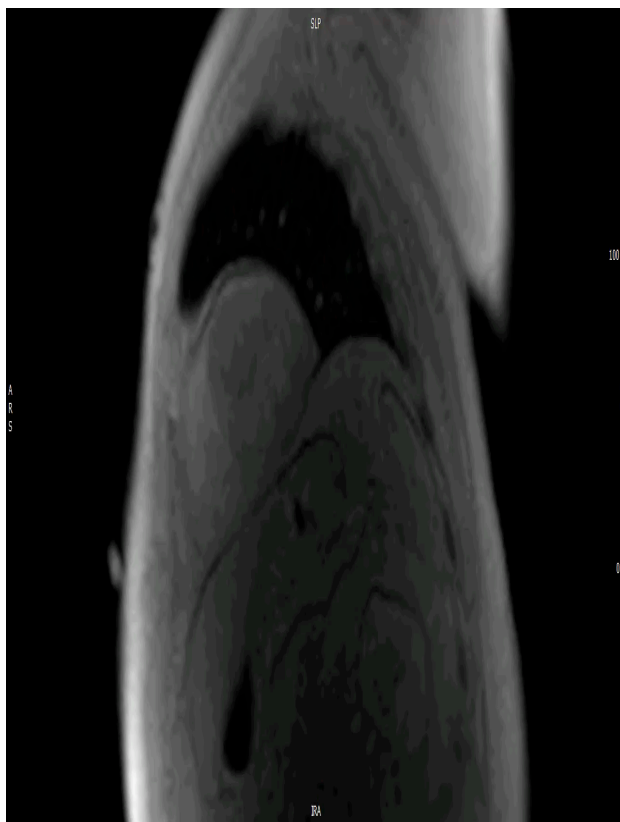


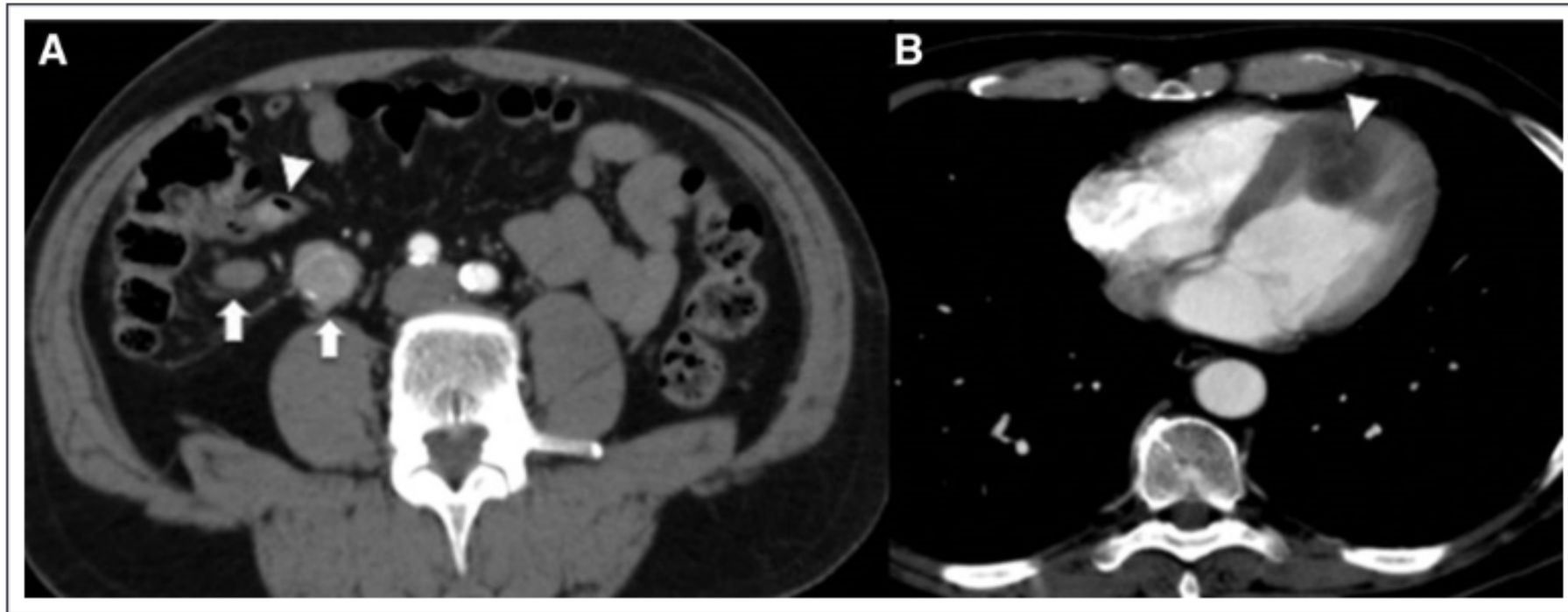
Clinical cases: ?





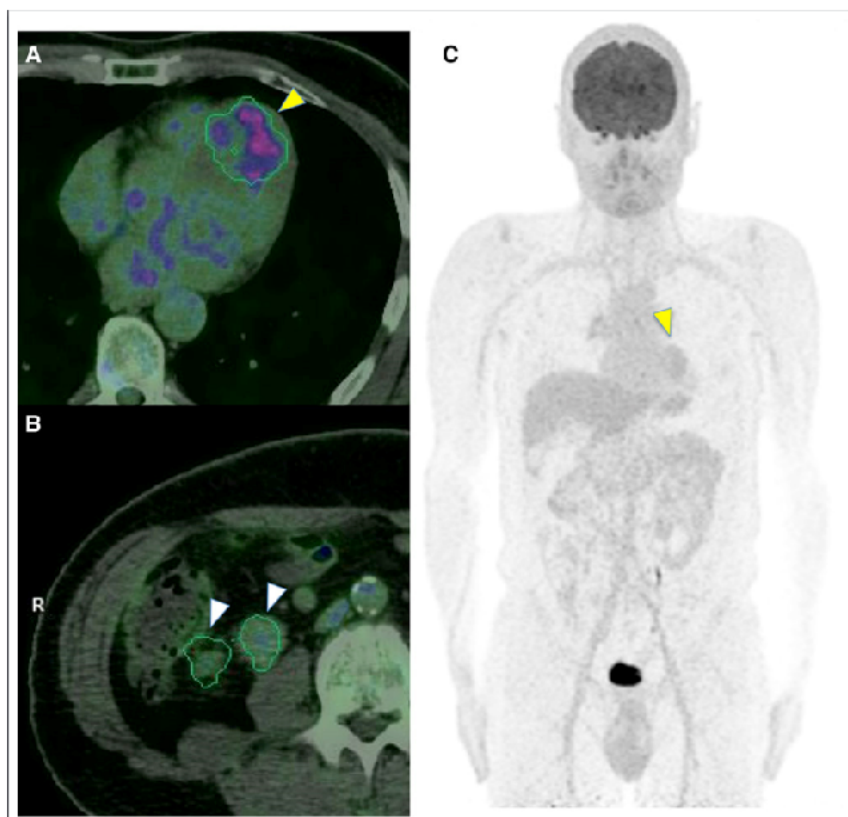
Clinical cases: ?



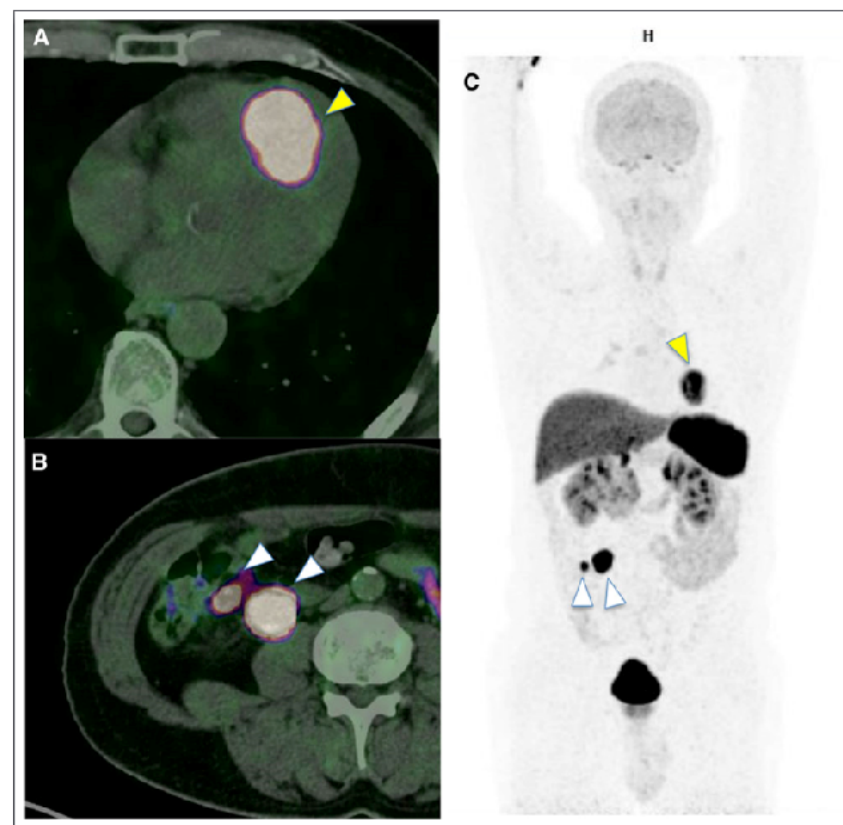


polypoid nodule in the terminal ileum, highly suggestive for a carcinoid tumor; enlarged lymph nodes with faint calcification and with increased enhancement at ileocolic level

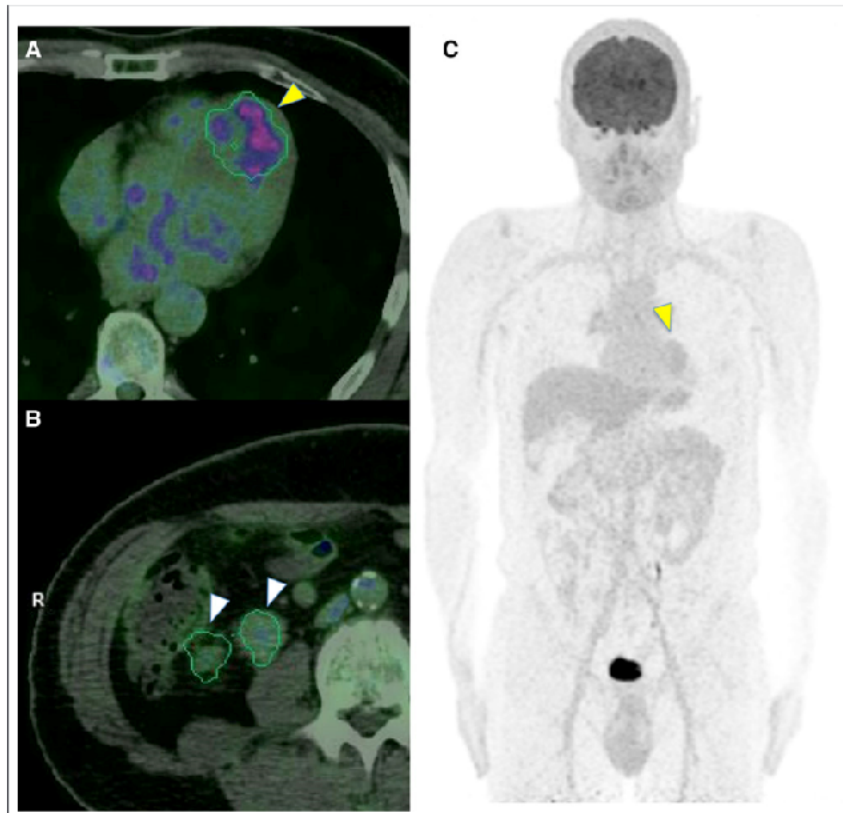
18F-FDG



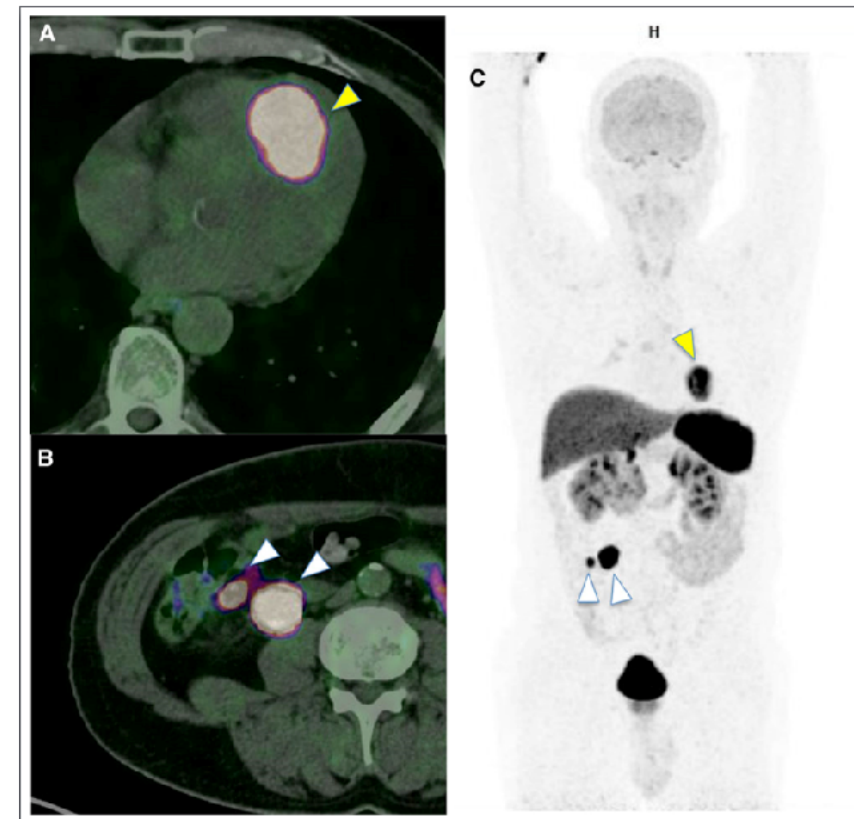
68Ga-DOTATATE



18F-FDG



68Ga-DOTATATE



These findings were definitively conclusive for the diagnosis of ileal neuroendocrine tumor with metastatic cardiac mass.

Courtesy of M. Salgarello




What are the main cardiac masses?

- Non-tumoral cardiac masses and mimics
- Metastatic tumors
- **Primary tumors: benign vs malignant**



- Myxomas are the most common type of primary cardiac tumor (25%—50%) and usually occur in the fourth to seventh decade of life.
- The typical patient diagnosed with this condition is a middle-aged female presenting with vague complaints such as atypical chest pains, palpitations, or intermittent shortness of breath with few if any clinical findings.
- They are typically solitary, vary in size from 1—15 cm, and have a predilection for the interatrial septum near the fossa ovalis. Approximately 75% occur in the left atrium, 20% in the right atrium, and 5% in either ventricle.
- Embolism occurs in 30—40% of patients with myxomas.
- Characteristic microscopic features are the typical myxoma cells in combination with an abundant myxomatous stroma.
- Their predilection to arise near the fossa ovalis facilitates the diagnosis of myxoma. However, when found in another location, differential diagnosis from other primary benign or malignant tumors, metastatic tumors and organized atrial thrombi is much more challenging.

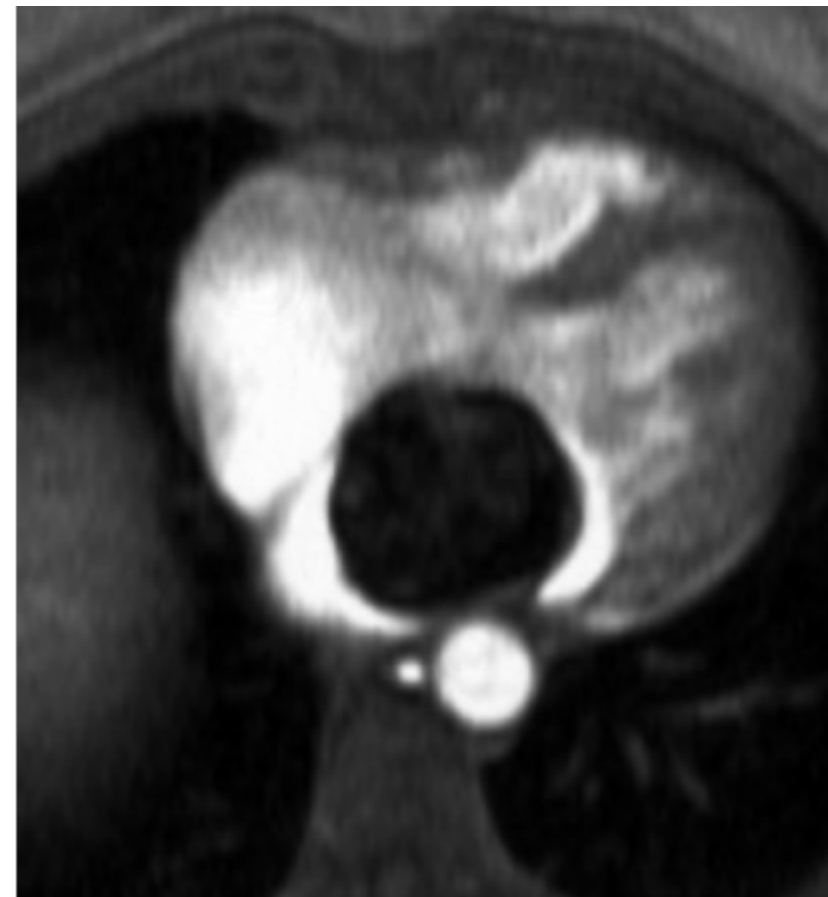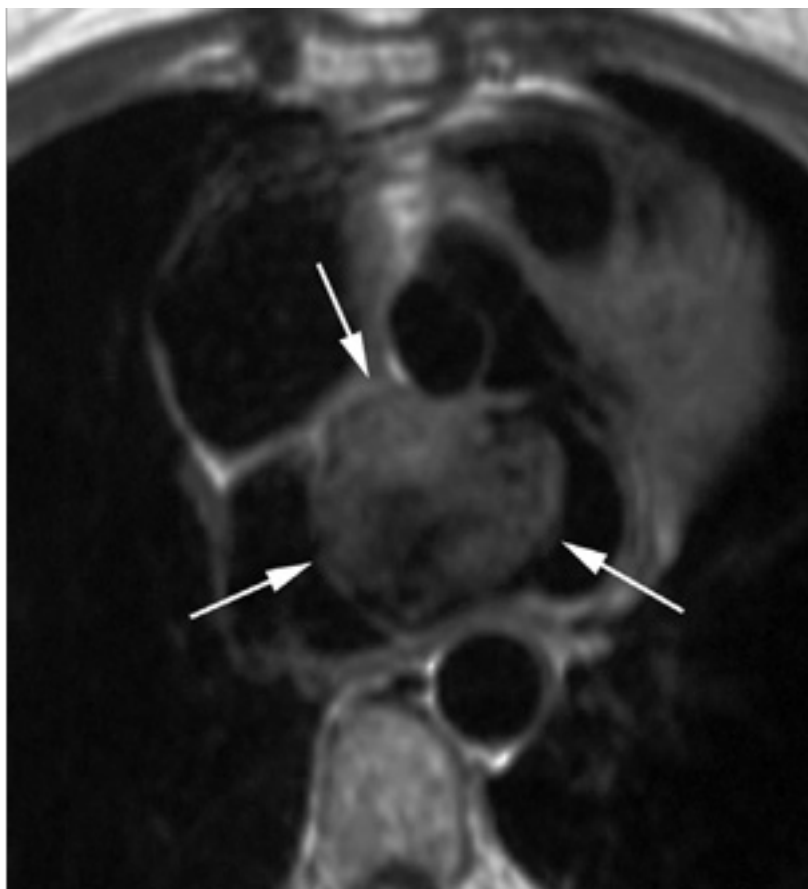


Cardiac Mass	T1w*	T1w fat sat*	T2w*	LGE
Myxoma	Isointense	Isointense	High	Heterogeneous

- They are generally well defined, smooth, lobular, or oval and often pedunculated.
- They are highly mobile, occasionally prolapsing through the mitral valve and causing obstruction.
- With SSFP cine techniques, myxomas appear hyperintense relative to the myocardium but hypointense relative to the blood pool.
- They appear isointense on T1-weighted images and have higher signal intensity on T2-weighted images owing to the high extracellular water content.
- Internally, myxomas may contain cysts, regions of necrosis, fibrosis, hemorrhage, and calcification, which lead to a typically heterogenous appearance at contrast enhancement.
- Many myxomas have a layer of surface thrombus, with low signal intensity on LGE images.

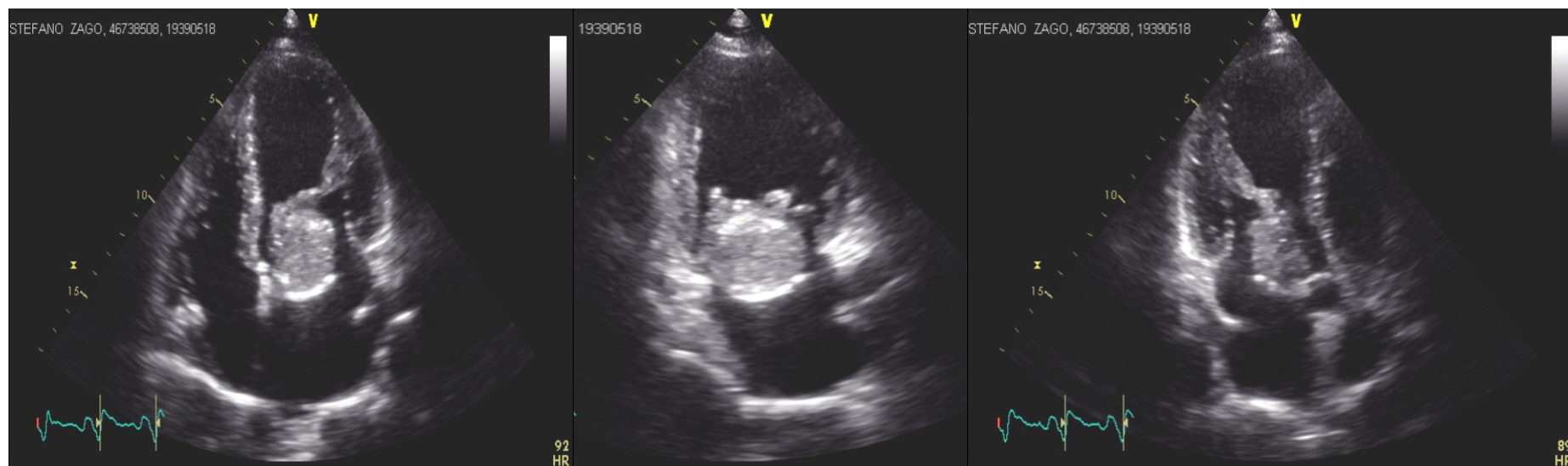
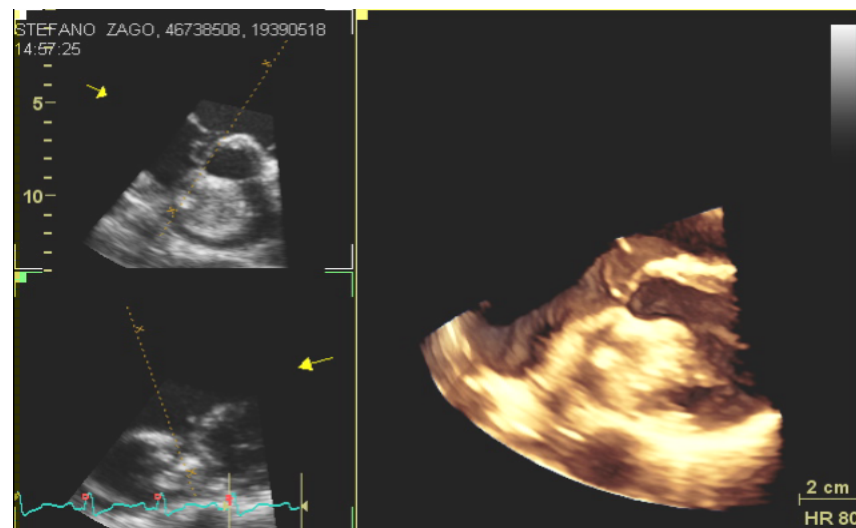


"Blooming artifact"



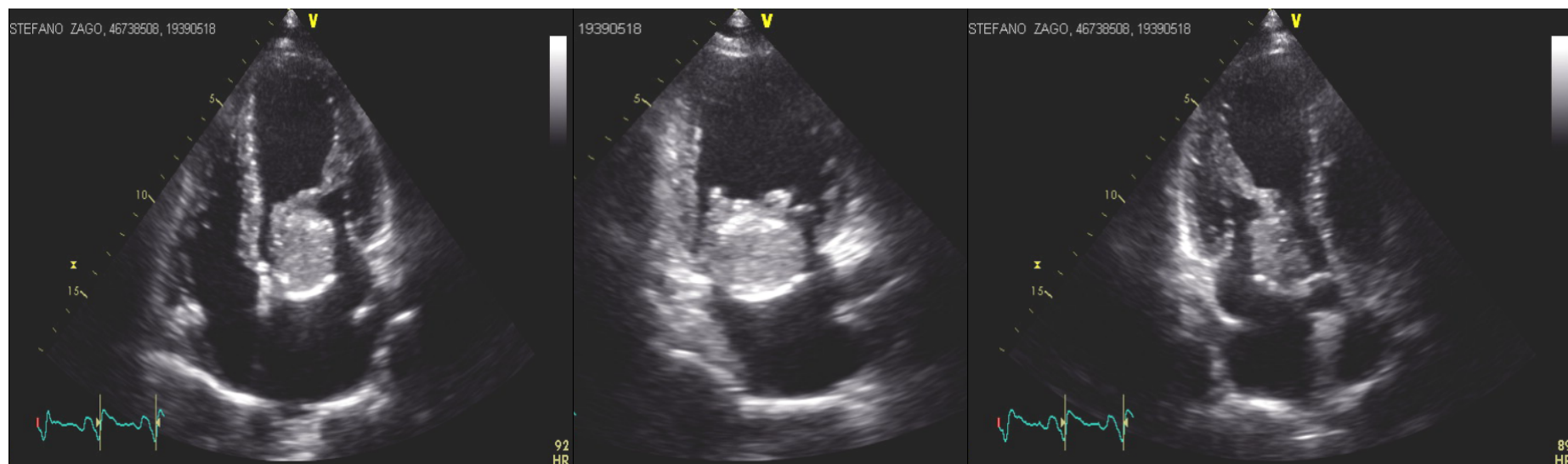
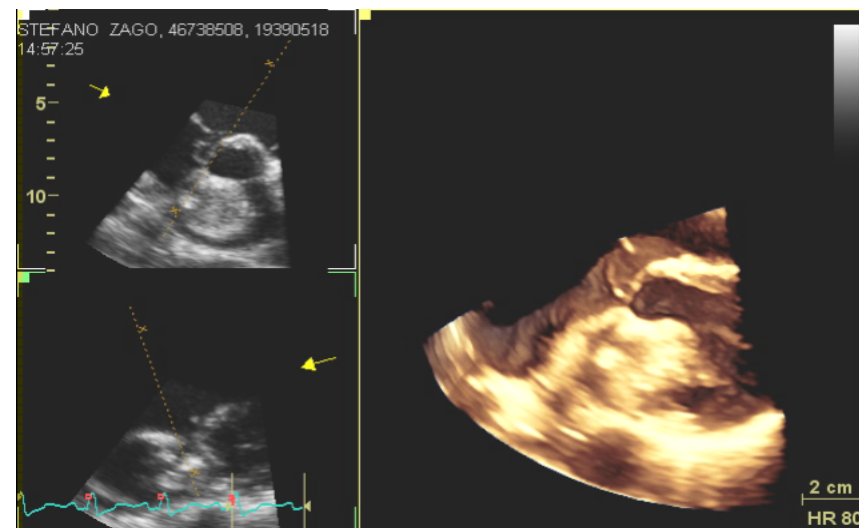
Clinical case: myxoma

- Male, 80 years old
- Hypertension
- Asymptomatic



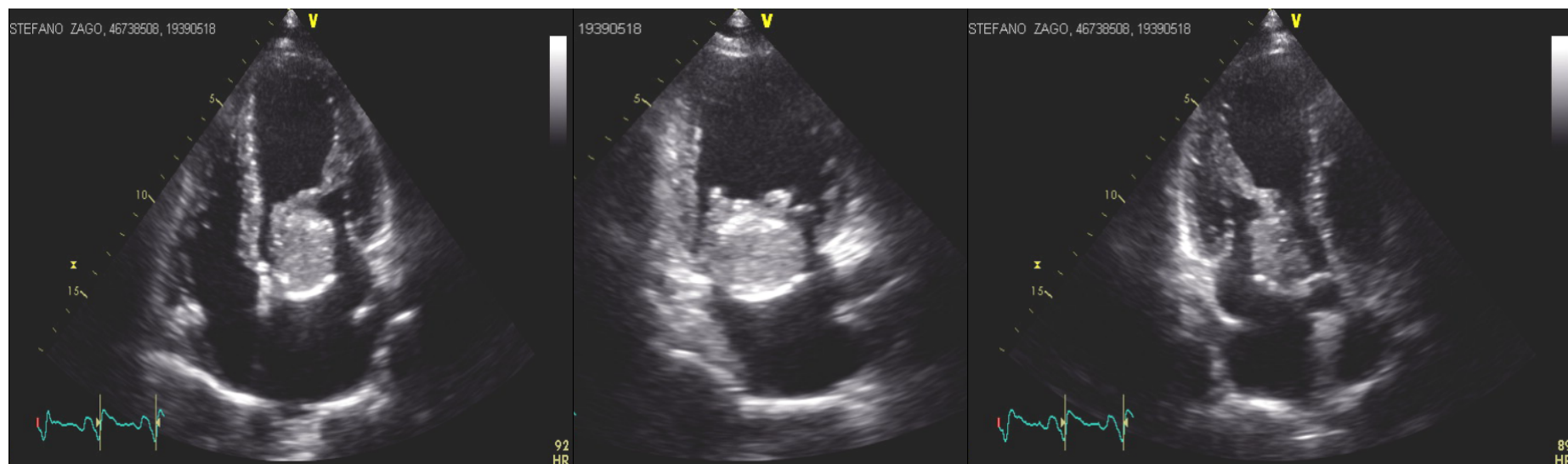
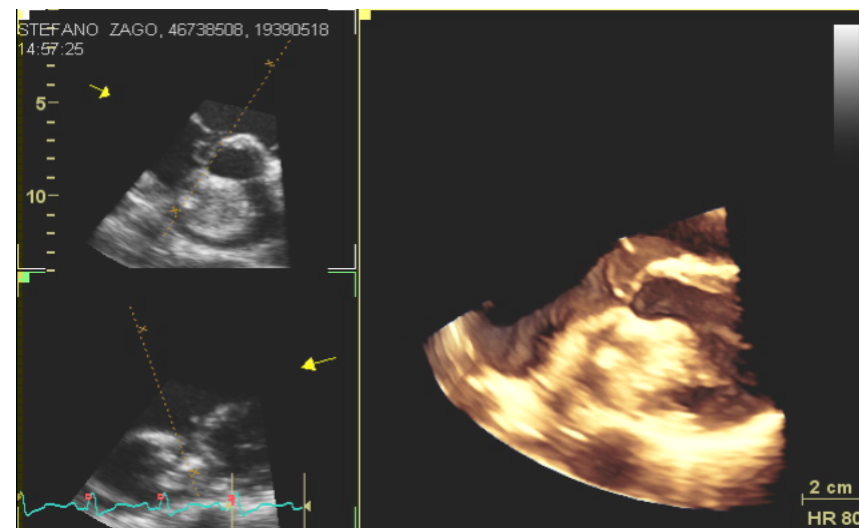
Clinical case: myxoma

- Male, 80 years old
- Hypertension
- Asymptomatic



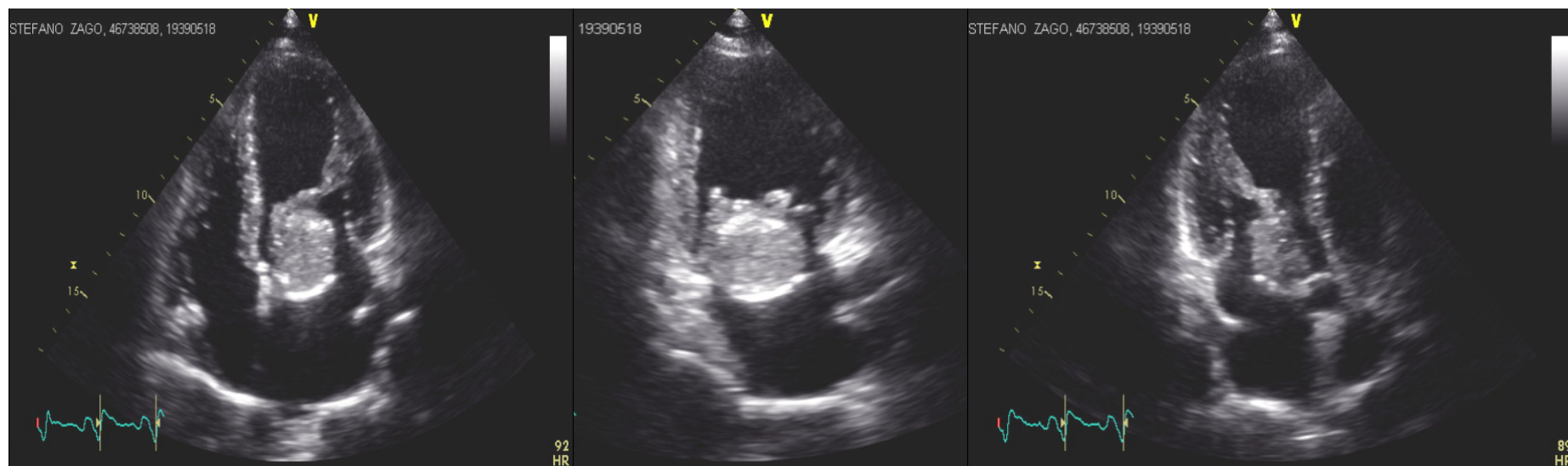
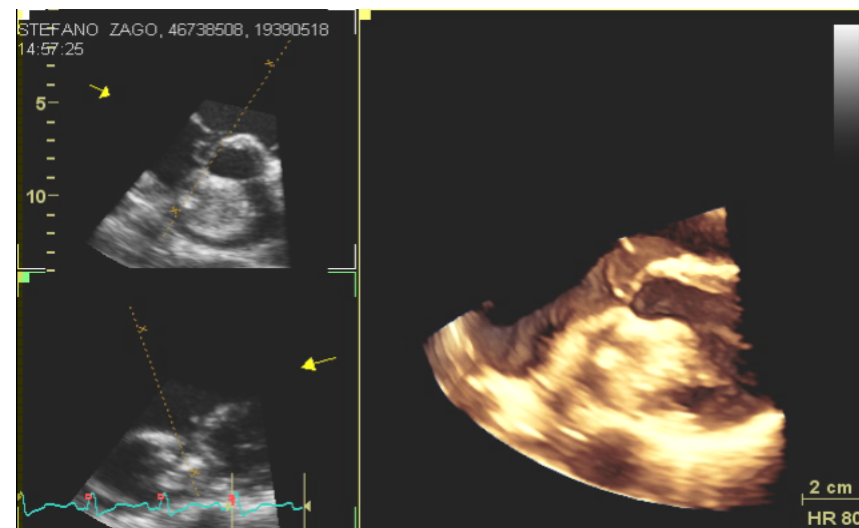
Clinical case: myxoma

- Male, 80 years old
- Hypertension
- Asymptomatic



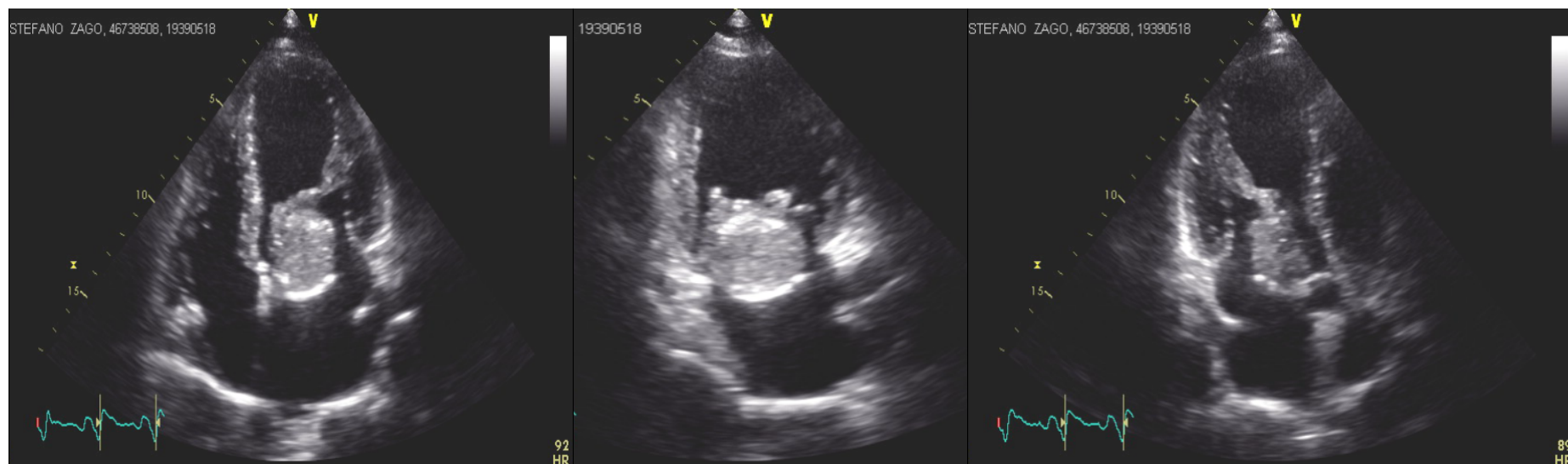
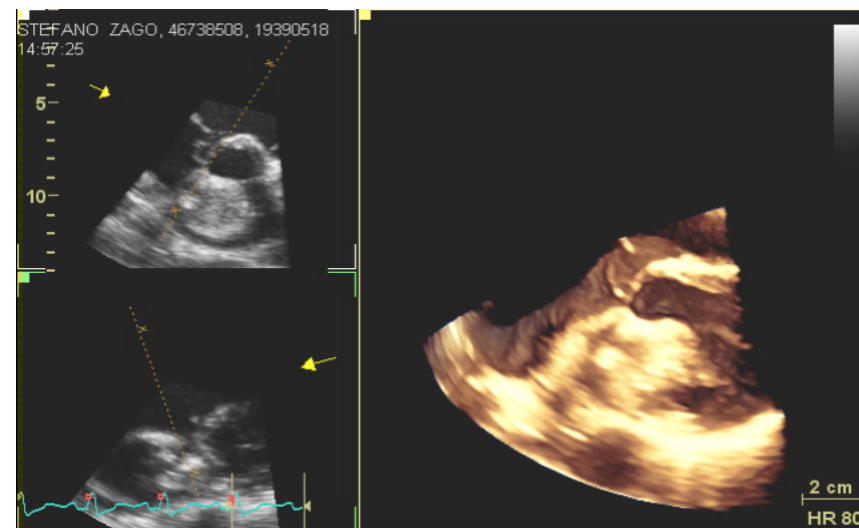
Clinical case: myxoma

- Male, 80 years old
- Hypertension
- Asymptomatic



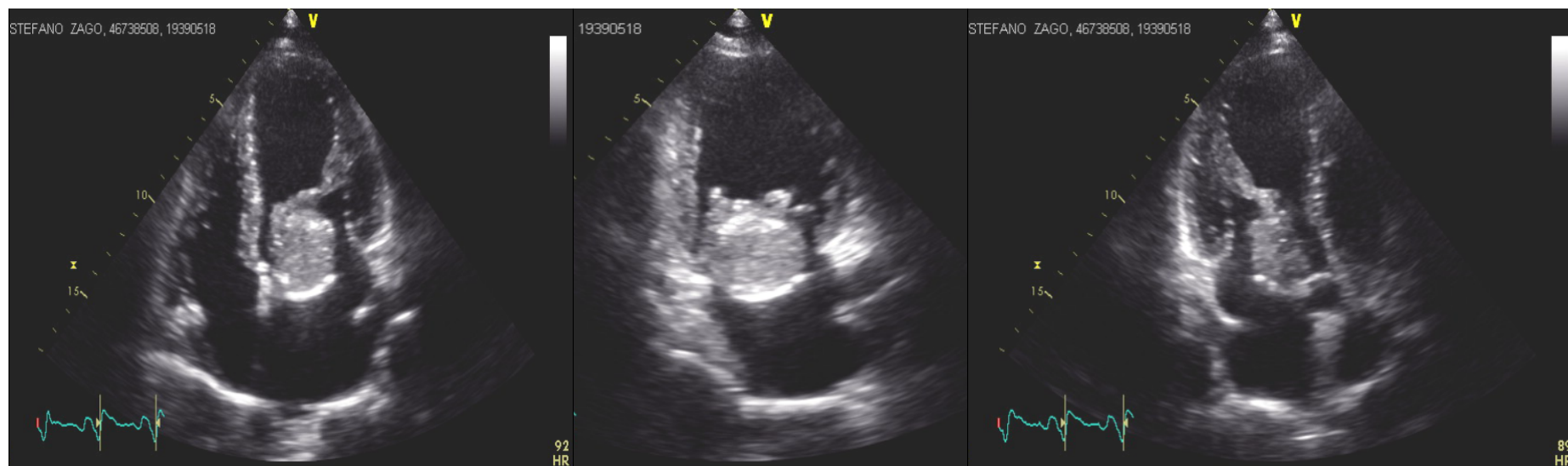
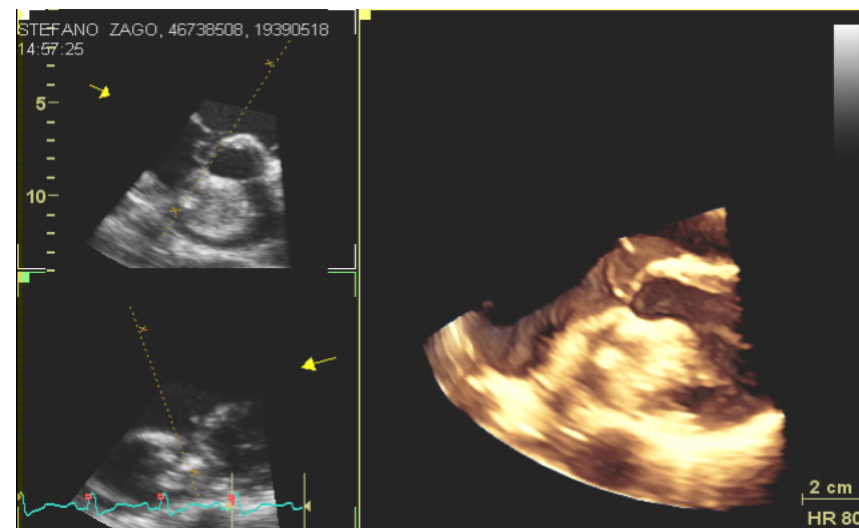
Clinical case: myxoma

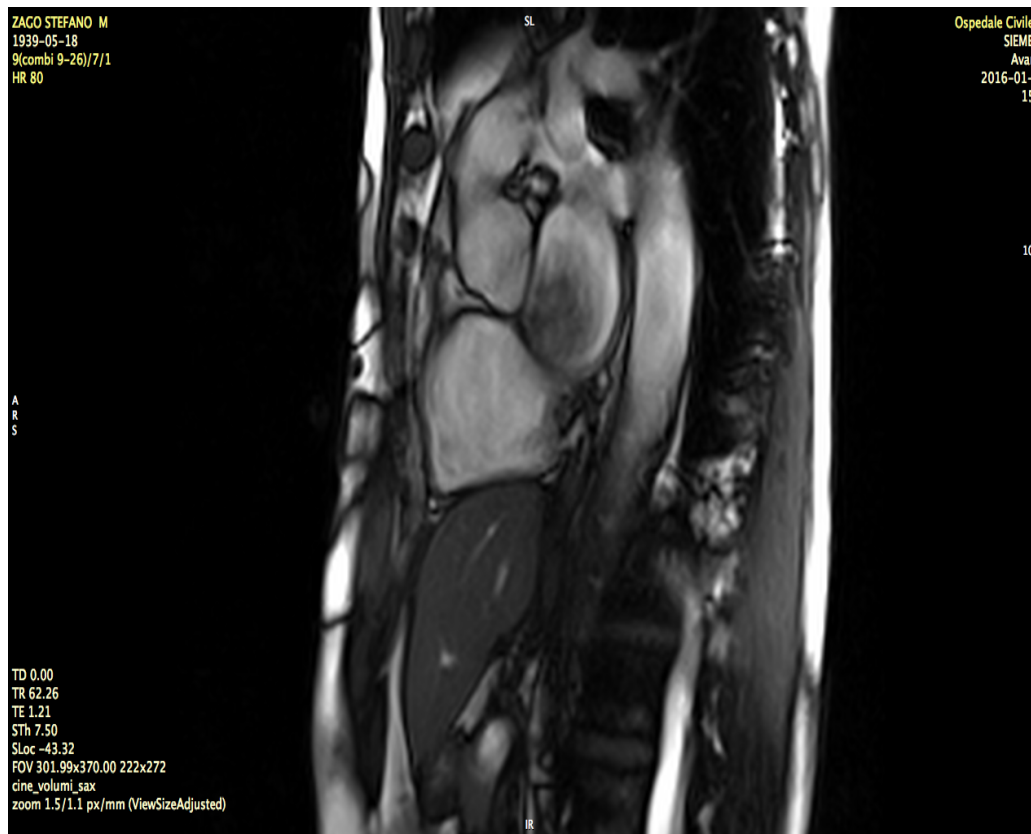
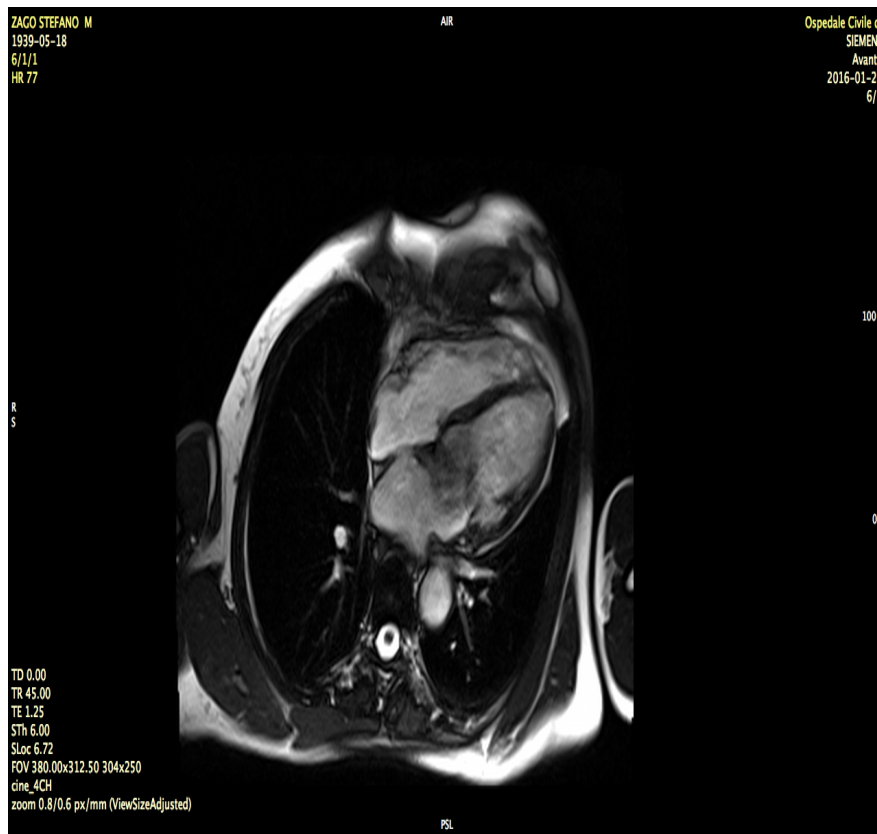
- Male, 80 years old
- Hypertension
- Asymptomatic



Clinical case: myxoma

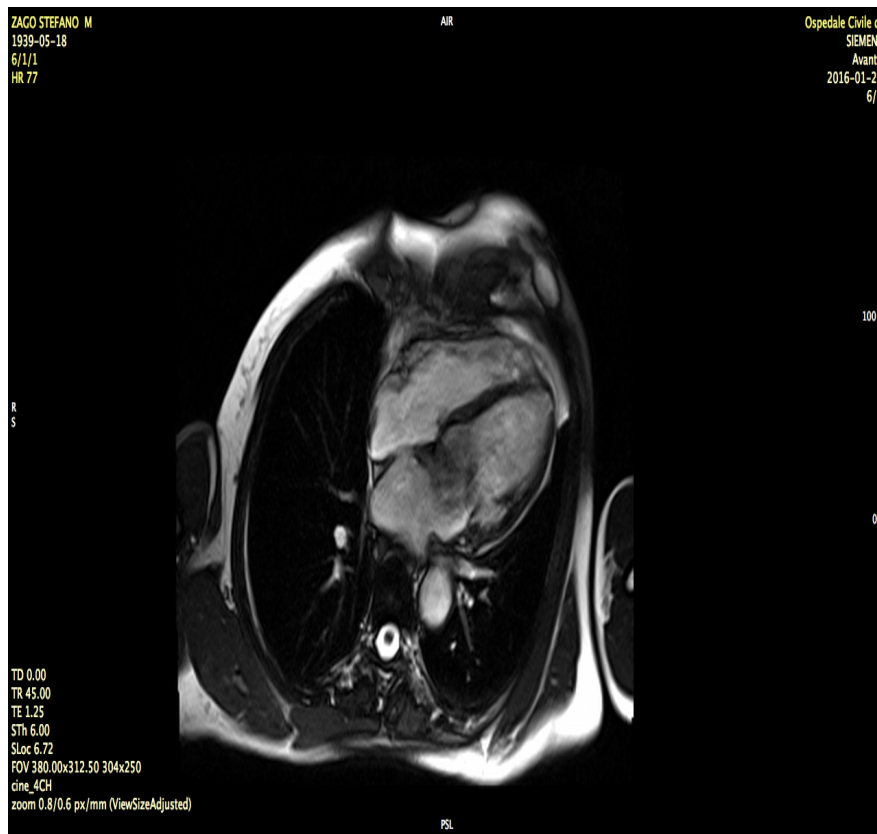
- Male, 80 years old
- Hypertension
- Asymptomatic





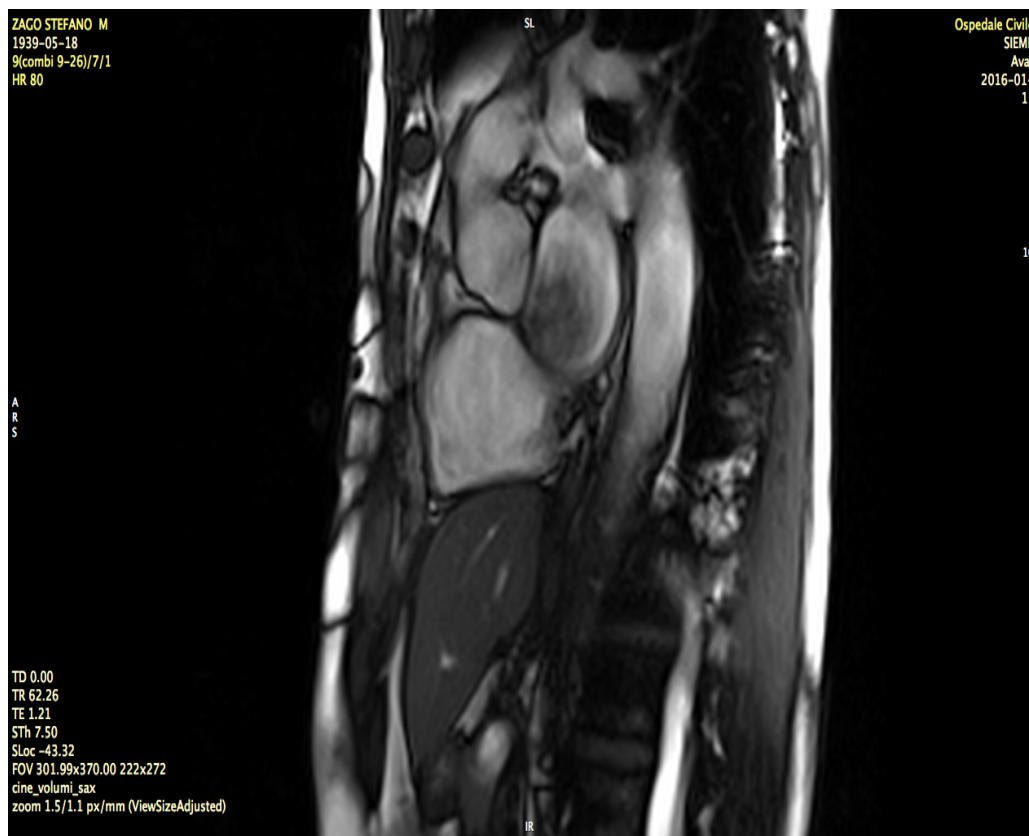
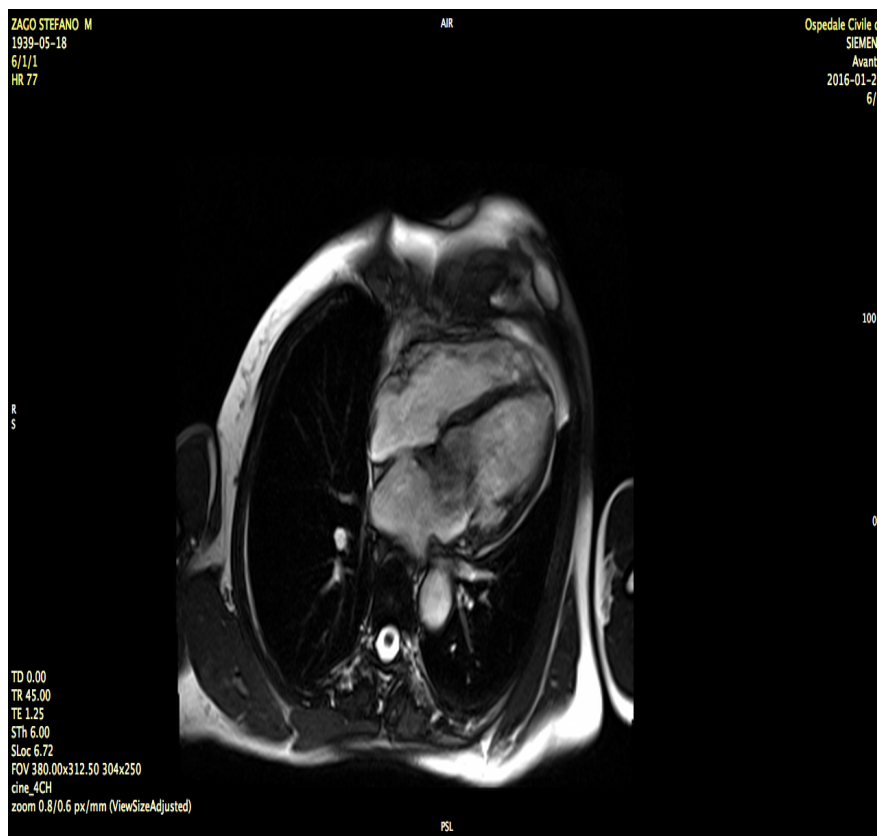
- Lesione espansiva rotondeggiante (35 x 35 x 38 mm) pedunculata
- In atrio sinistro
- Base di impianto sul setto IA, in prossimità dell' anulus mitralico
- Impegna parzialmente l' orifizio mitralico a livello del lembo anteriore causando lieve insufficienza mitralica

Clinical case: myxoma

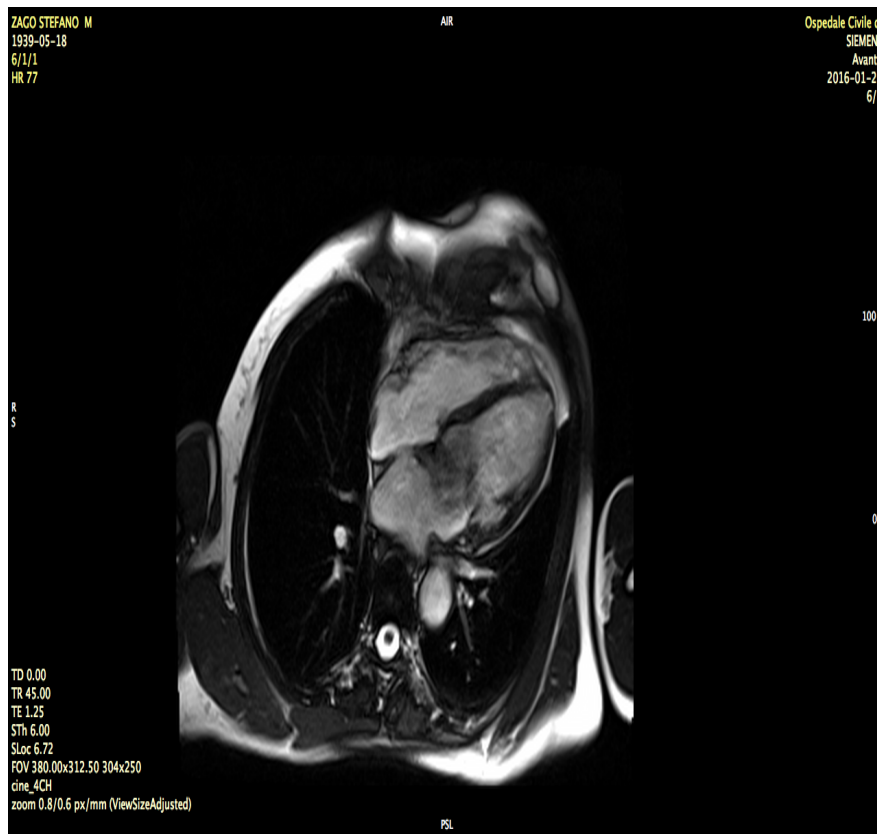


- Lesione espansiva rotondeggiante (35 x 35 x 38 mm) pedunculata
- In atrio sinistro
- Base di impianto sul setto IA, in prossimità dell' anulus mitralico
- Impegna parzialmente l' orifizio mitralico a livello del lembo anteriore causando lieve insufficienza mitralica

Clinical case: myxoma

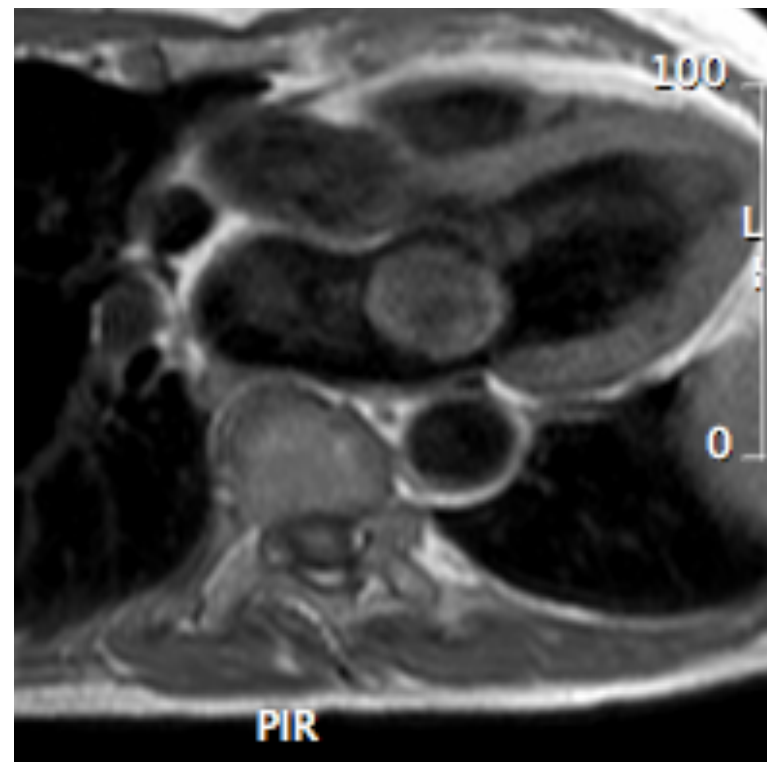
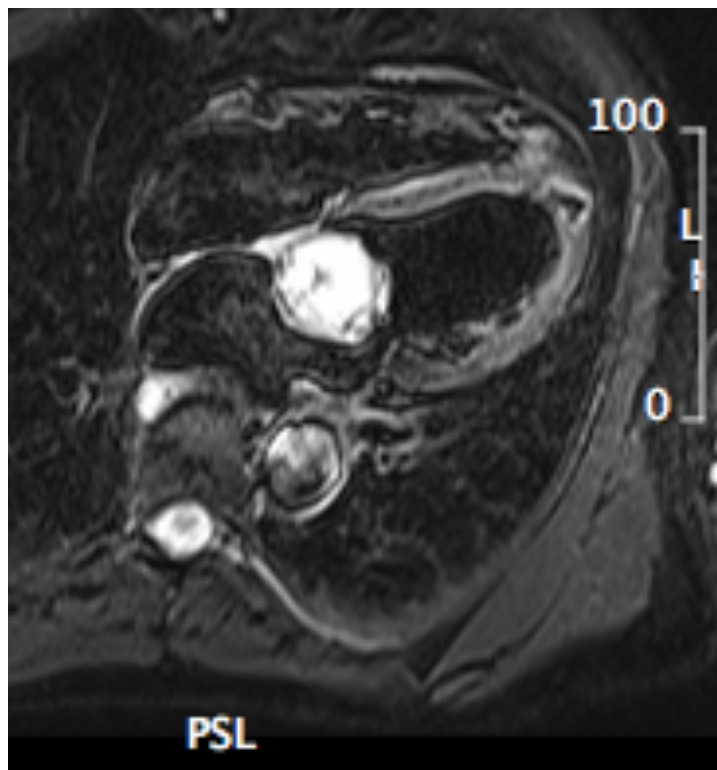


- Lesione espansiva rotondeggiante (35 x 35 x 38 mm) pedunculata
- In atrio sinistro
- Base di impianto sul setto IA, in prossimità dell' anulus mitralico
- Impegna parzialmente l' orifizio mitralico a livello del lembo anteriore causando lieve insufficienza mitralica



- Lesione espansiva rotondeggiante (35 x 35 x 38 mm) pedunculata
- In atrio sinistro
- Base di impianto sul setto IA, in prossimità dell' anulus mitralico
- Impegna parzialmente l' orifizio mitralico a livello del lembo anteriore causando lieve insufficienza mitralica

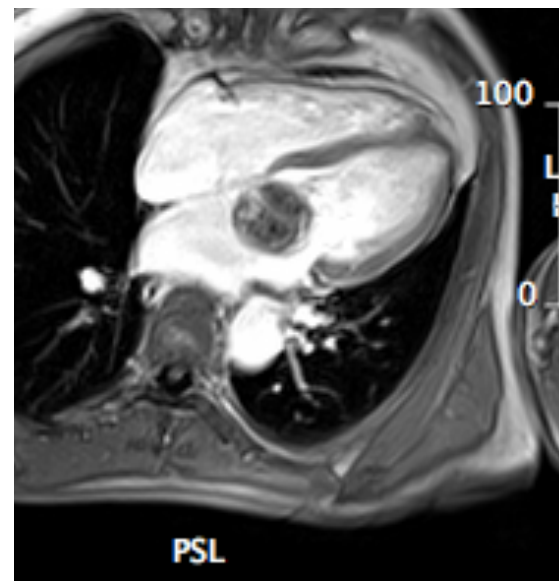
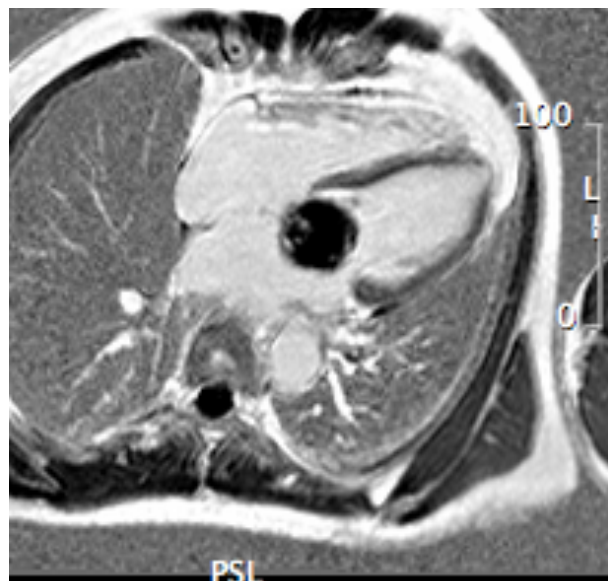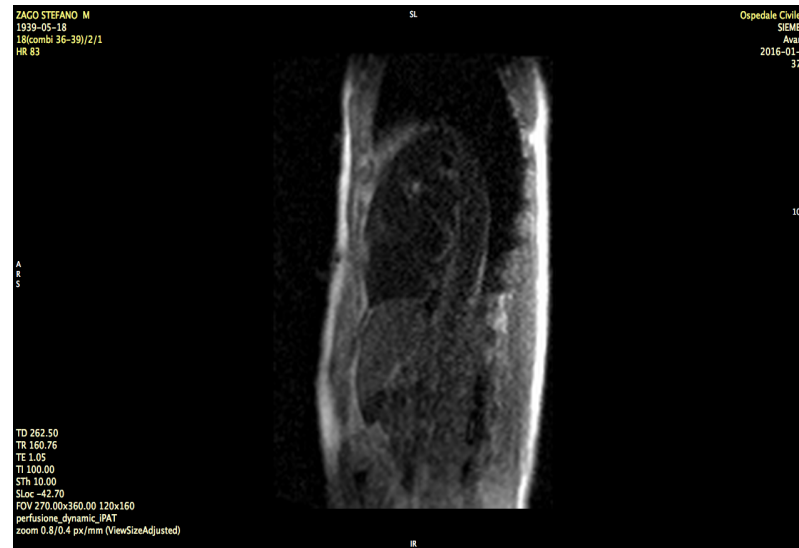
Clinical case: myxoma



- Ipointensa nelle sequenze cine; isointensa in T1; iperintensa nelle TIRM

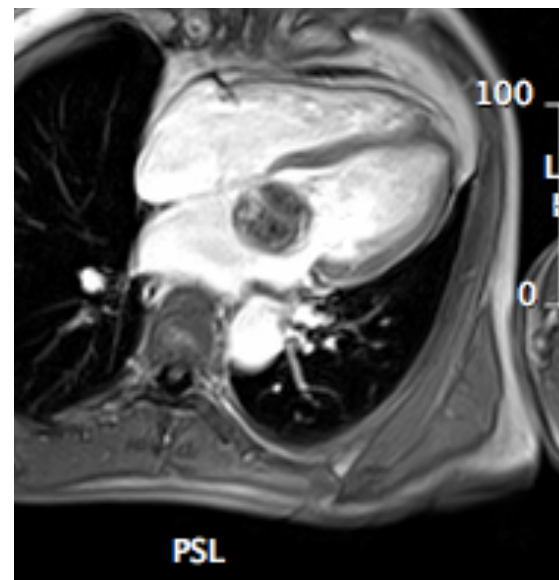
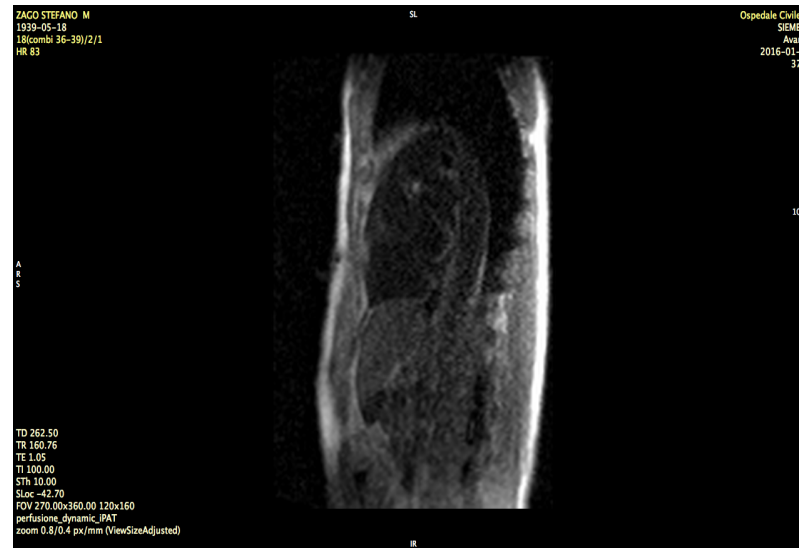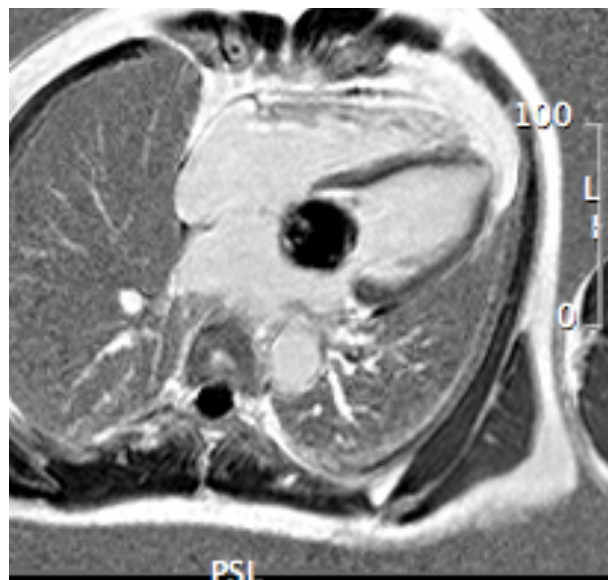
Clinical case: myxoma

- Dopo somministrazione di mdc, in fase precoce (first pass) ipoperfusa;
- In fase tardiva, disomogeneo LE; con long TI focali ipointensità (danno emorragico? calcificazioni?)
- Massa atriale compatibile con mixoma



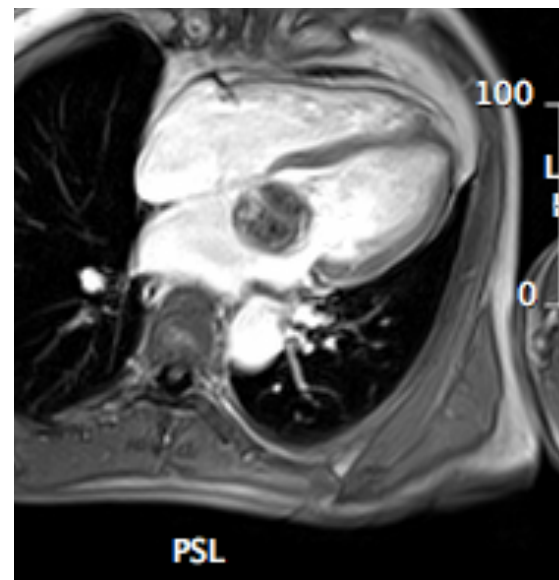
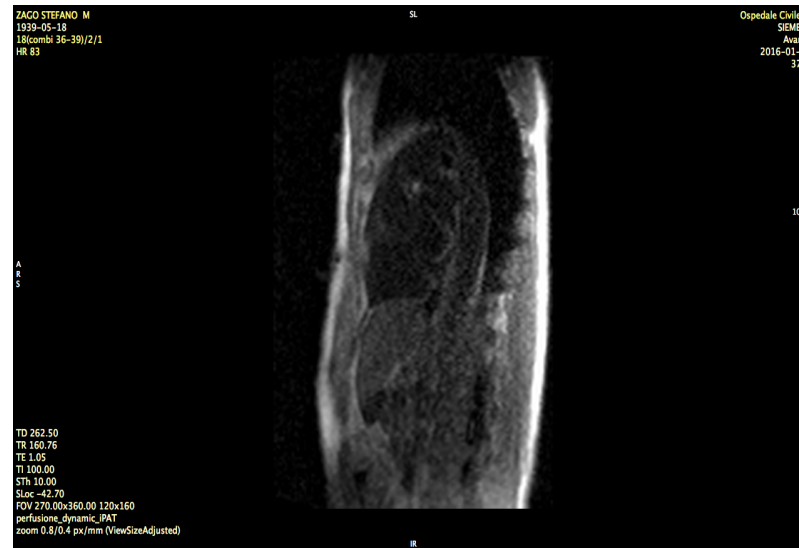
Clinical case: myxoma

- Dopo somministrazione di mdc, in fase precoce (first pass) ipoperfusa;
- In fase tardiva, disomogeneo LE; con long TI focali ipointensità (danno emorragico? calcificazioni?)
- Massa atriale compatibile con mixoma



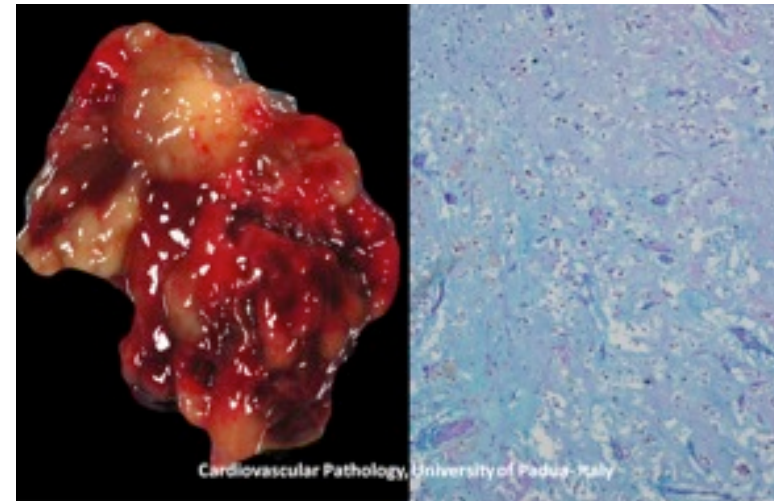
Clinical case: myxoma

- Dopo somministrazione di mdc, in fase precoce (first pass) ipoperfusa;
- In fase tardiva, disomogeneo LE; con long TI focali ipointensità (danno emorragico? calcificazioni?)
- Massa atriale compatibile con mixoma





Esame istologico: “neoformazione costituita da cellule fusiformi...immerse in abbondante matrice mixoide... presenti stravasi emorragici interstiziali ed aree di calcificazione distrofica...
Diagnosi: mixoma sessile liscio pseudovascolare calcifico (litomixoma).

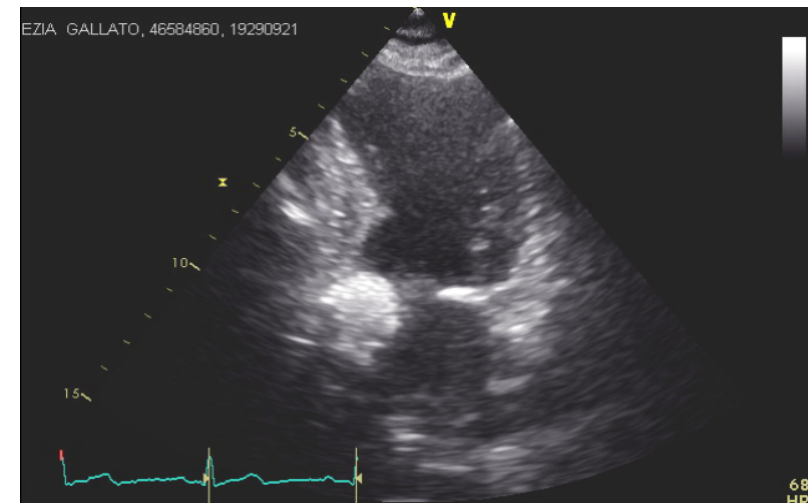
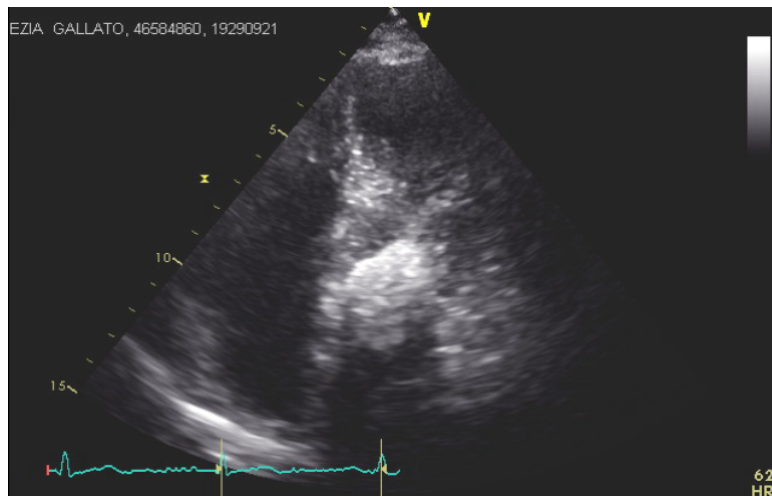
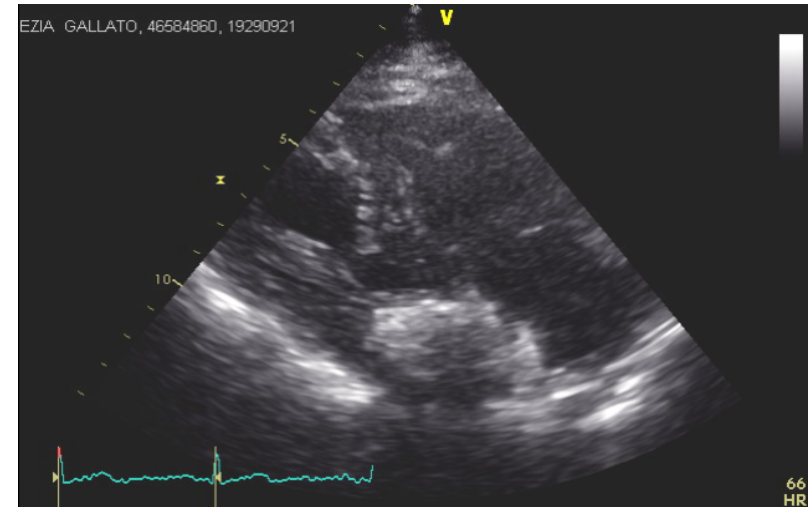




- Second most common congenital tumor and typically present in pediatric or young adult life.
- They are usually solitary tumors and are most often located intramurally in the ventricles.
- Macroscopically, they are solitary, well-defined masses within the myocardium. Microscopically, they are composed of neoplastic fibroblasts without cystic change, hemorrhage, or necrosis but frequently have central calcification.
- With MR imaging, fibromas are isointense relative to normal myocardium on T1-w images and are characteristically hypointense on T2-w images. With gadolinium-based contrast agent administration, fibromas generally show no contrast enhancement during perfusion imaging due to their avascularity. However, later, they classically show intense hyperenhancement on LGE images.

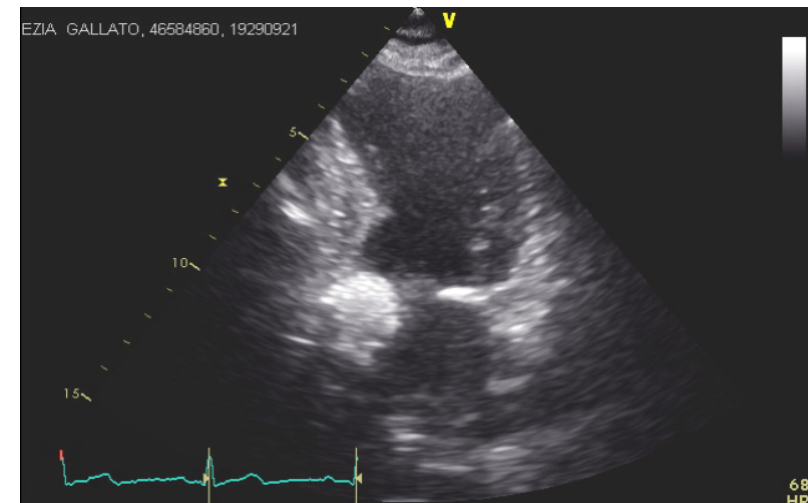
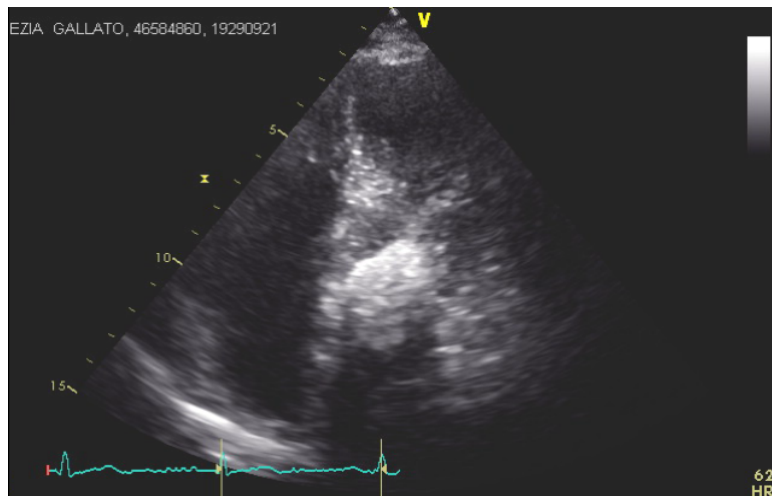
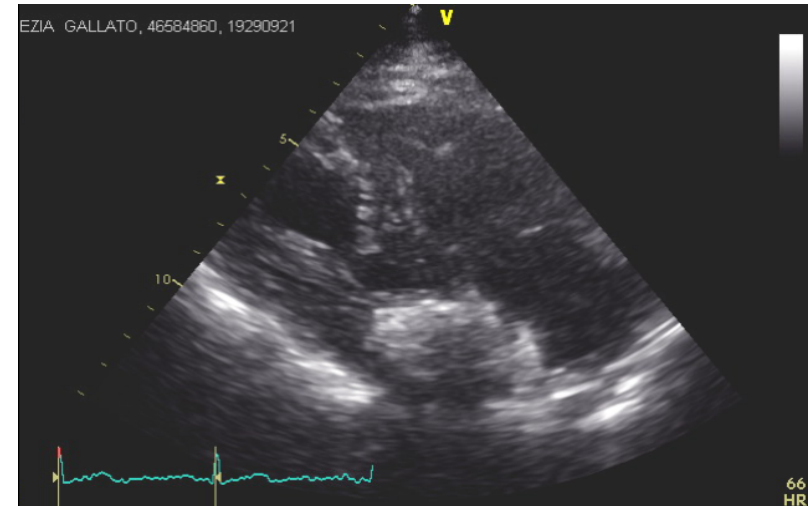
Clinical case: fibroma

- Female, 90 years old
- Hypertension, diabetes
- Dyspnoea and palpitation

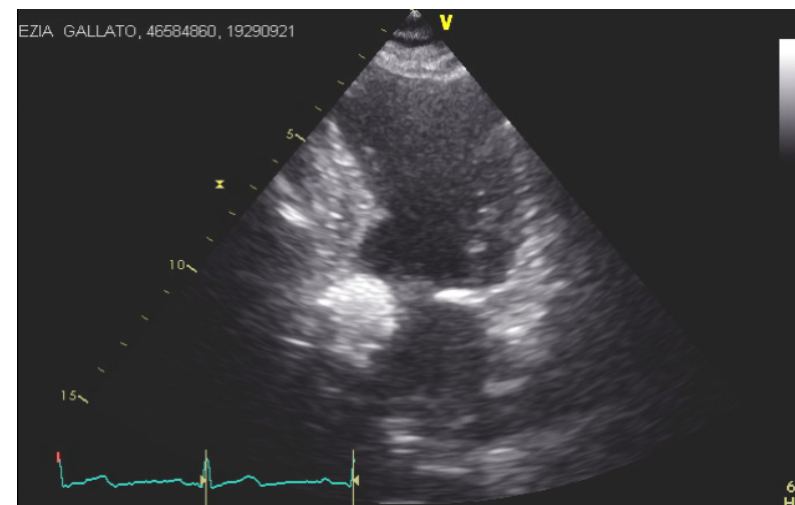
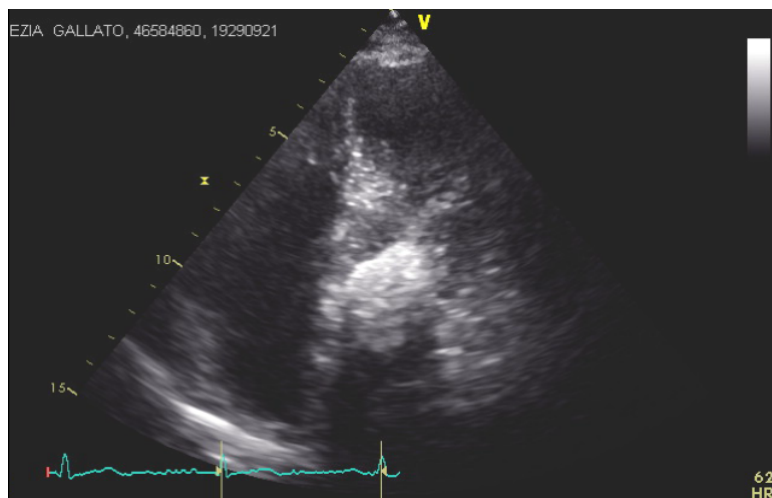
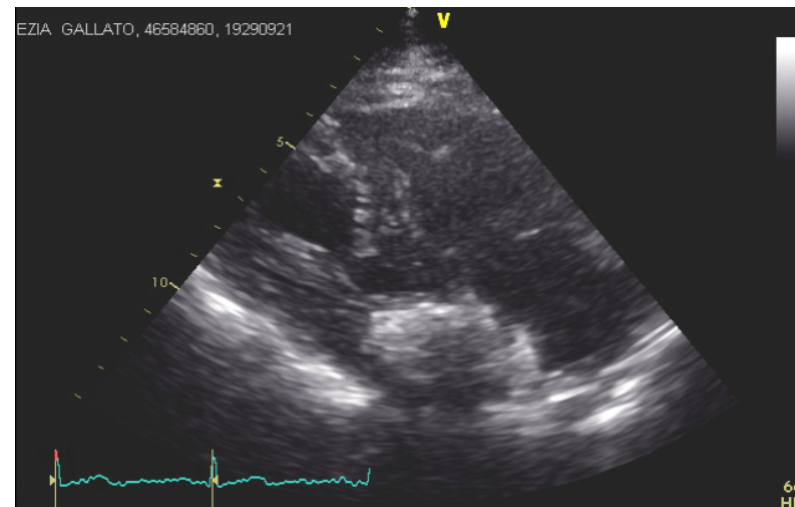


Clinical case: fibroma

- Female, 90 years old
- Hypertension, diabetes
- Dyspnoea and palpitation

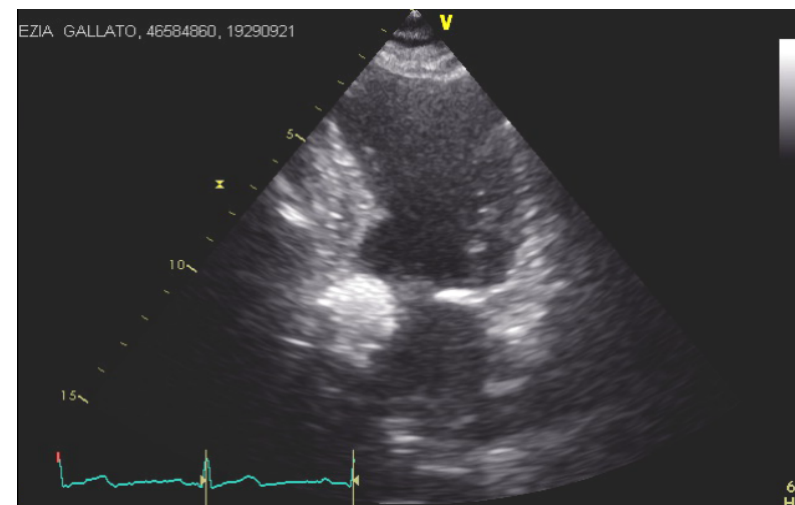
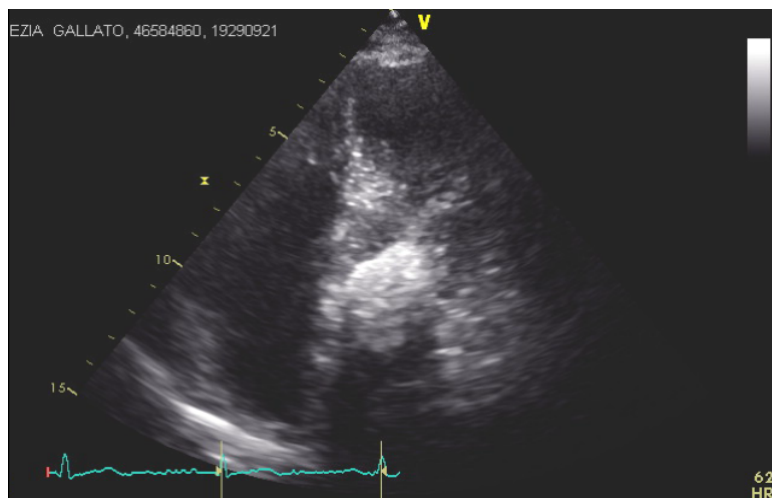
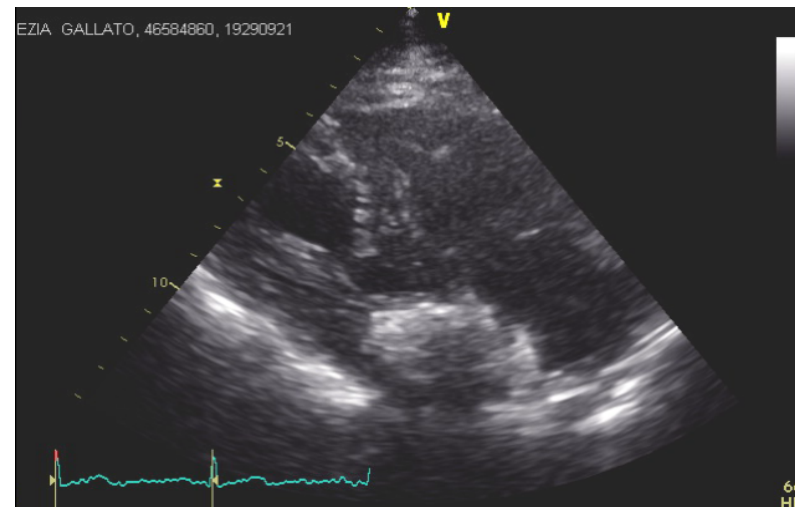


- Female, 90 years old
- Hypertension, diabetes
- Dyspnoea and palpitation



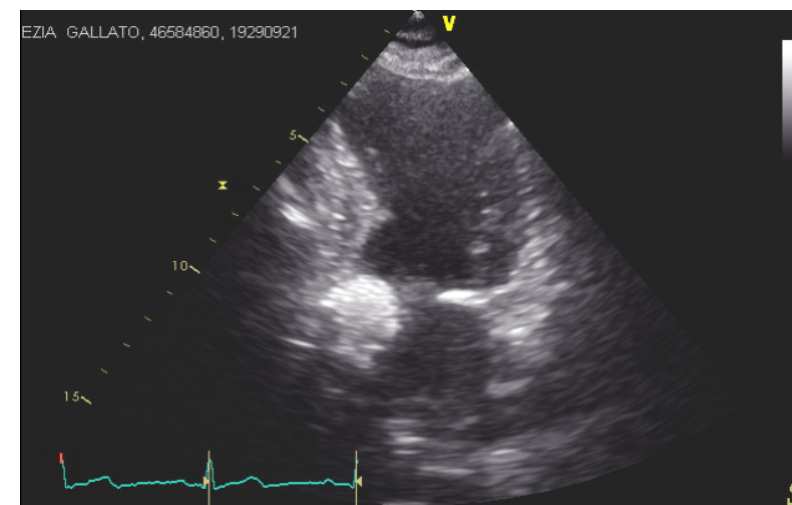
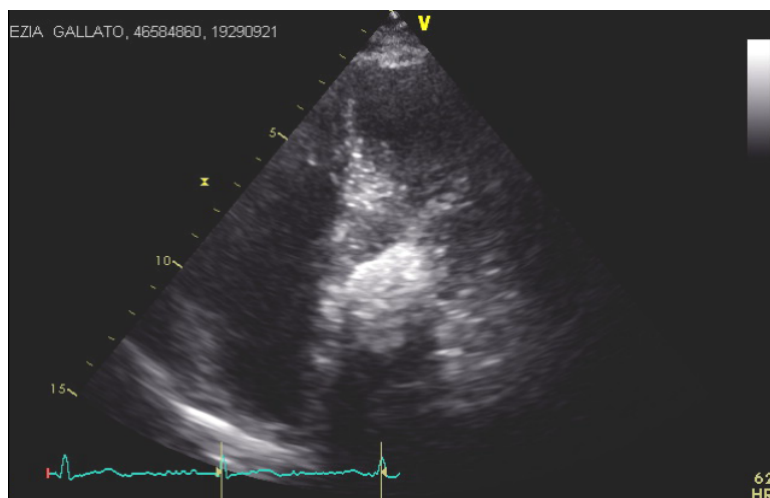
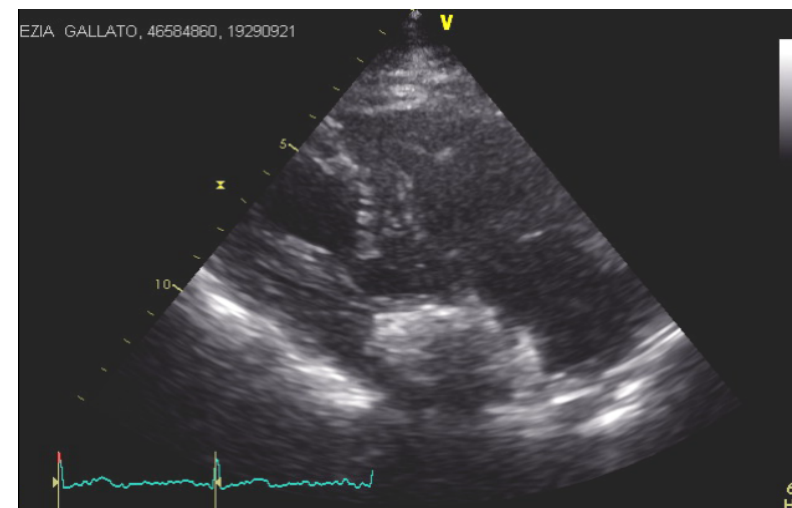
Clinical case: fibroma

- Female, 90 years old
- Hypertension, diabetes
- Dyspnoea and palpitation

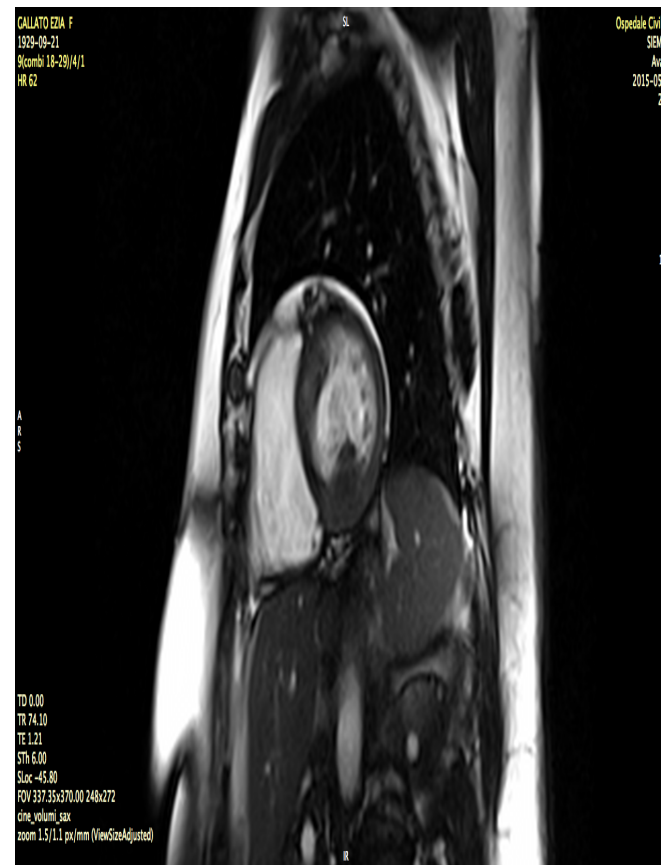
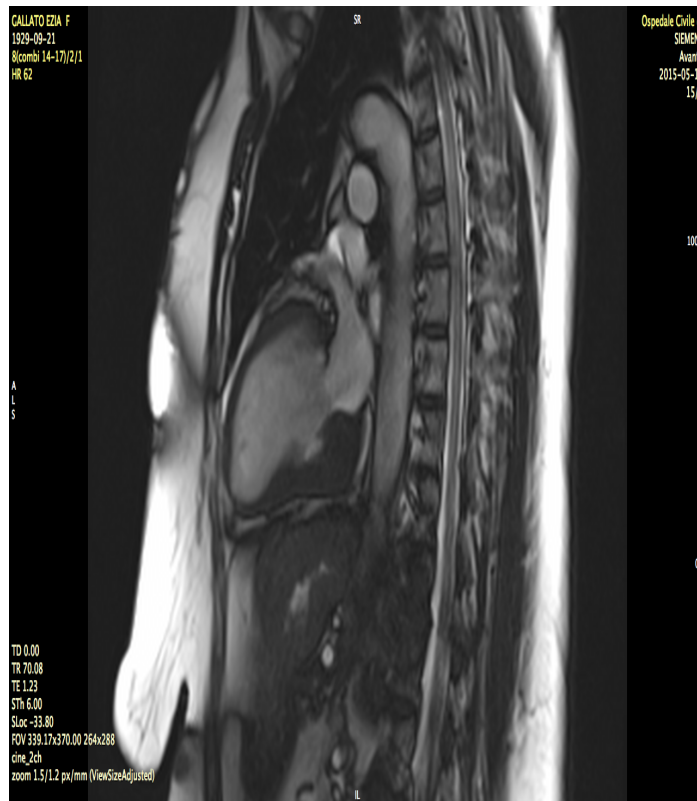
Clinical case: fibroma

- Female, 90 years old
- Hypertension, diabetes
- Dyspnoea and palpitation

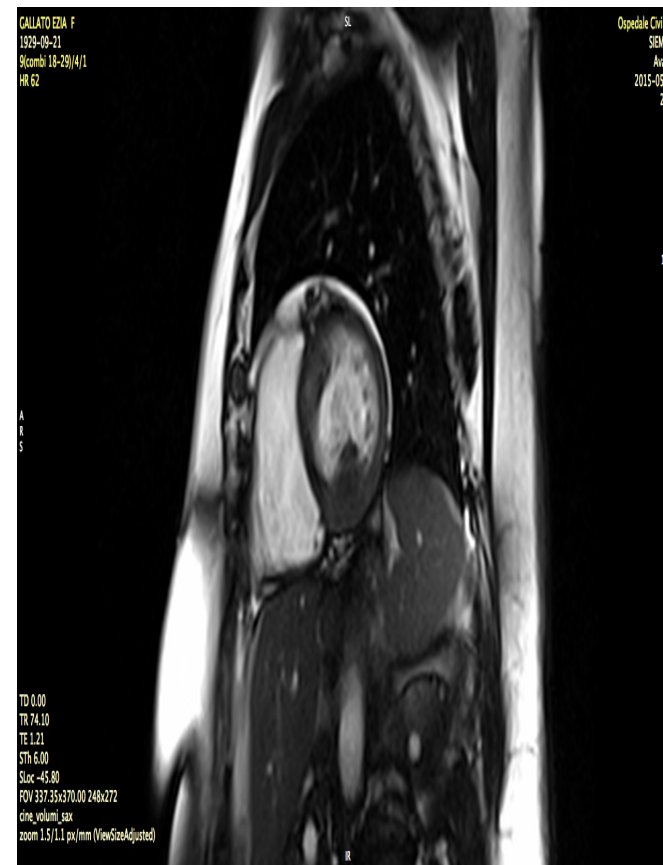
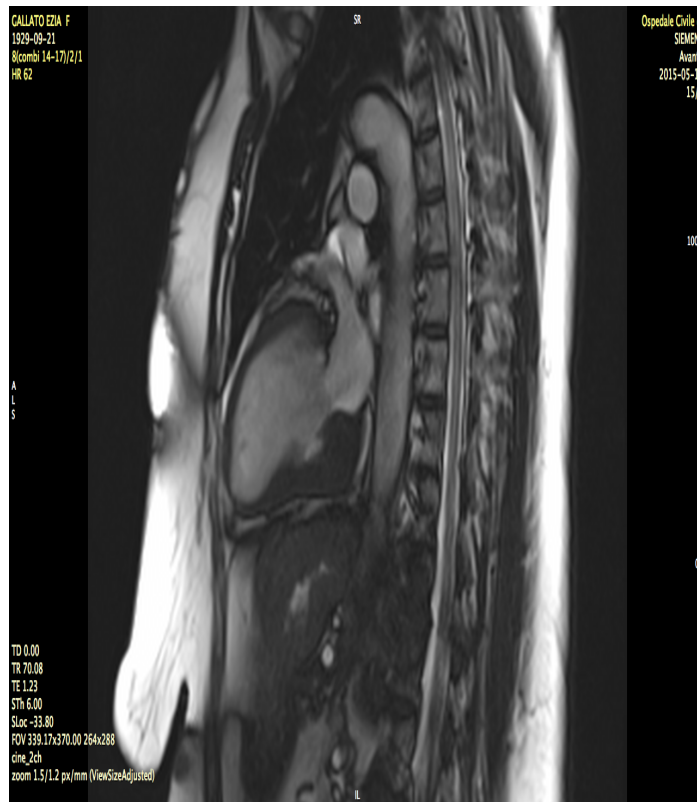
Clinical case: fibroma



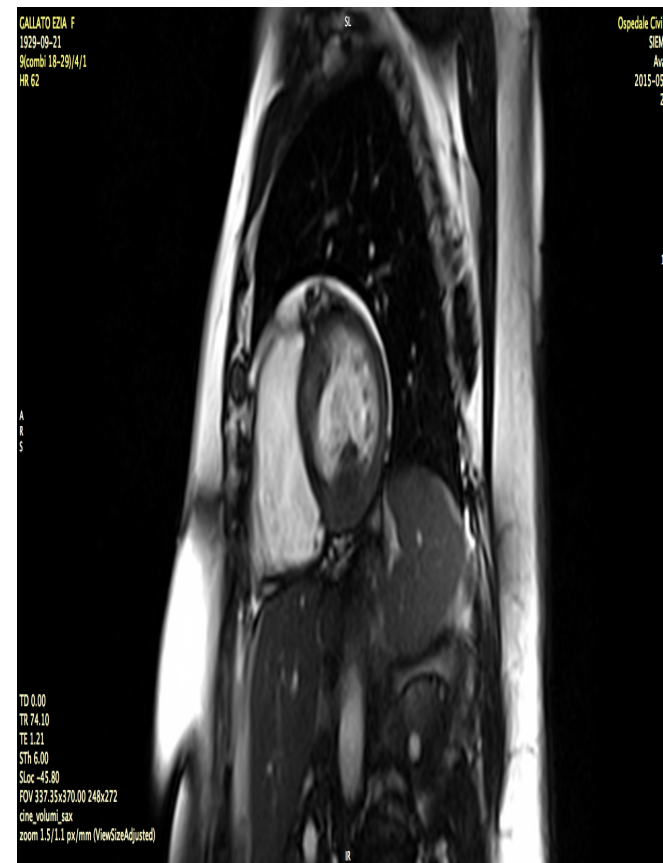“Formazione espansiva, di dimensioni 25x22x30 mm, non contrattile, a profili netti, nel contesto della parete inferiore basale del ventricolo sinistro, in prossimità del lembo posteriore mitralico che non appare infiltrato dalla massa stessa.”

Clinical case: fibroma



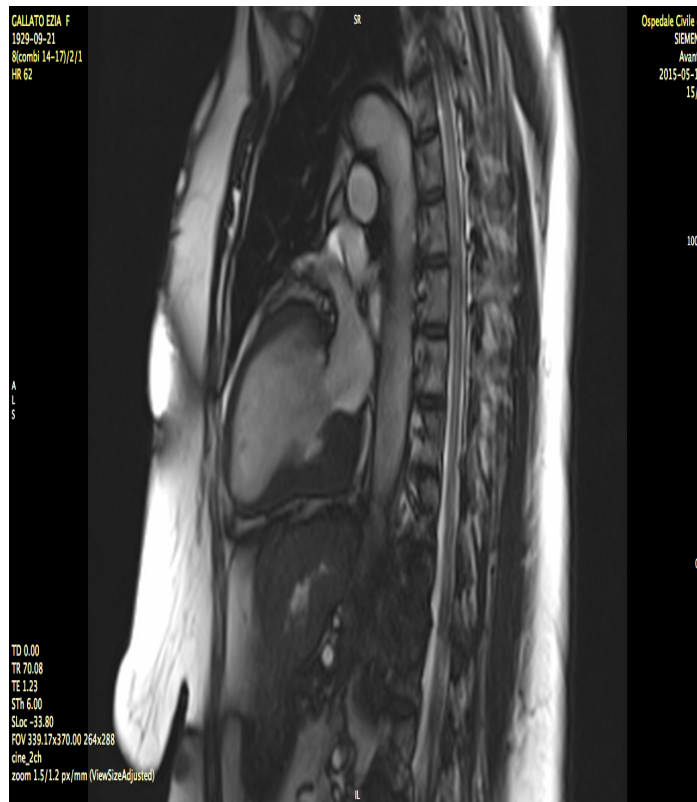
“Formazione espansiva, di dimensioni 25x22x30 mm, non contrattile, a profili netti, nel contesto della parete inferiore basale del ventricolo sinistro, in prossimità del lembo posteriore mitralico che non appare infiltrato dalla massa stessa.”

Clinical case: fibroma

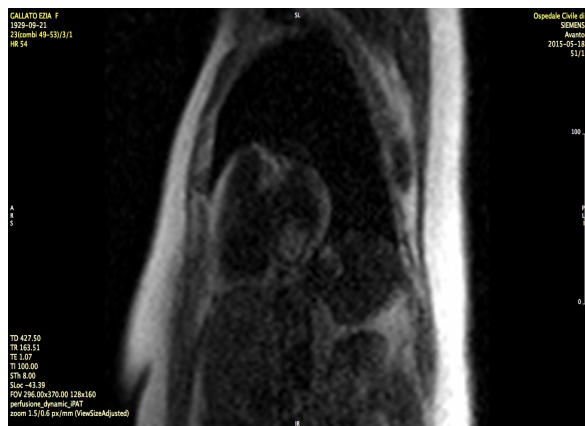


“Formazione espansiva, di dimensioni 25x22x30 mm, non contrattile, a profili netti, nel contesto della parete inferiore basale del ventricolo sinistro, in prossimità del lembo posteriore mitralico che non appare infiltrato dalla massa stessa.”

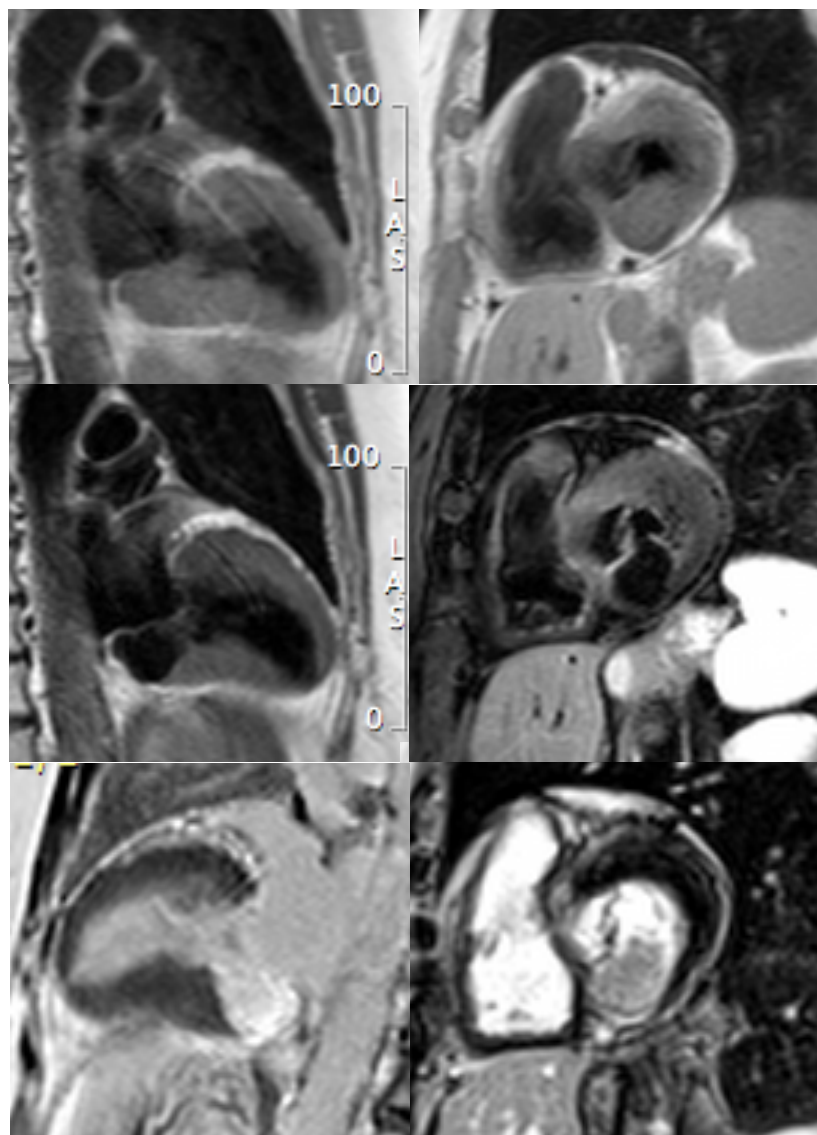
Clinical case: fibroma

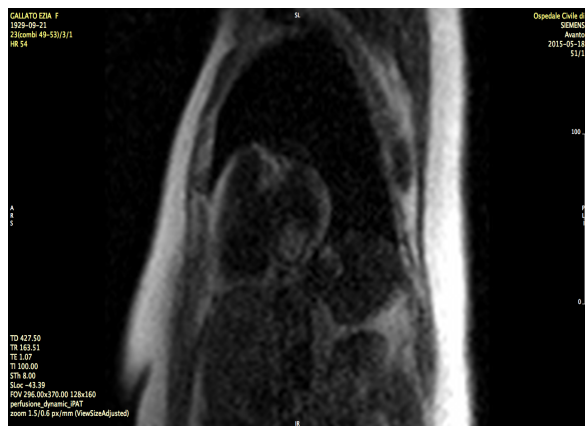


“Formazione espansiva, di dimensioni 25x22x30 mm, non contrattile, a profili netti, nel contesto della parete inferiore basale del ventricolo sinistro, in prossimità del lembo posteriore mitralico che non appare infiltrato dalla massa stessa.”

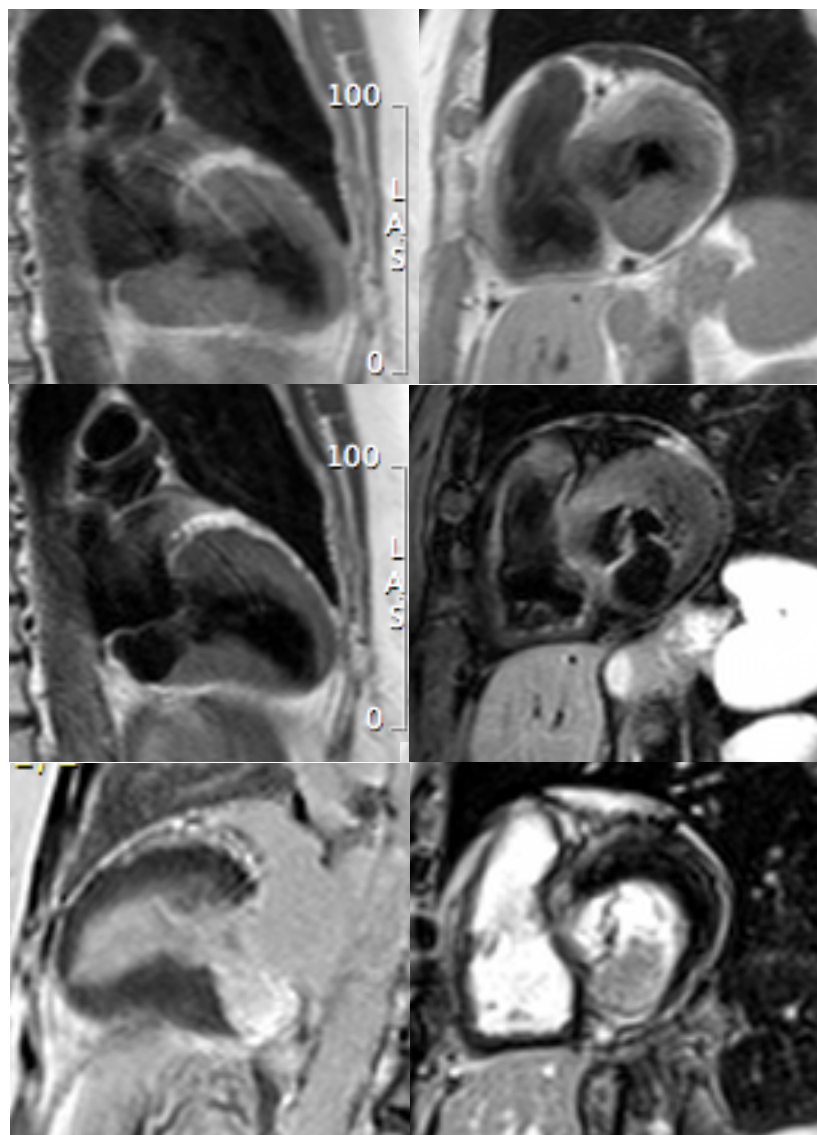


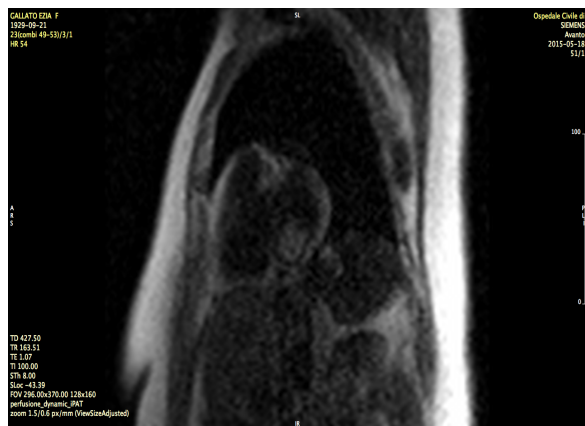
“Formazione iso-iperintensa nelle sequenze T1 pesate, ipointensa nelle sequenze T2 pesate, dopo iniezione di mdc in fase precoce (first pass) disomogeneamente ipoperfusa, omogeneo LE in fase tardiva con rim perilesionale. Conclusione: compatibile con lesione di tipo fibromatoso”



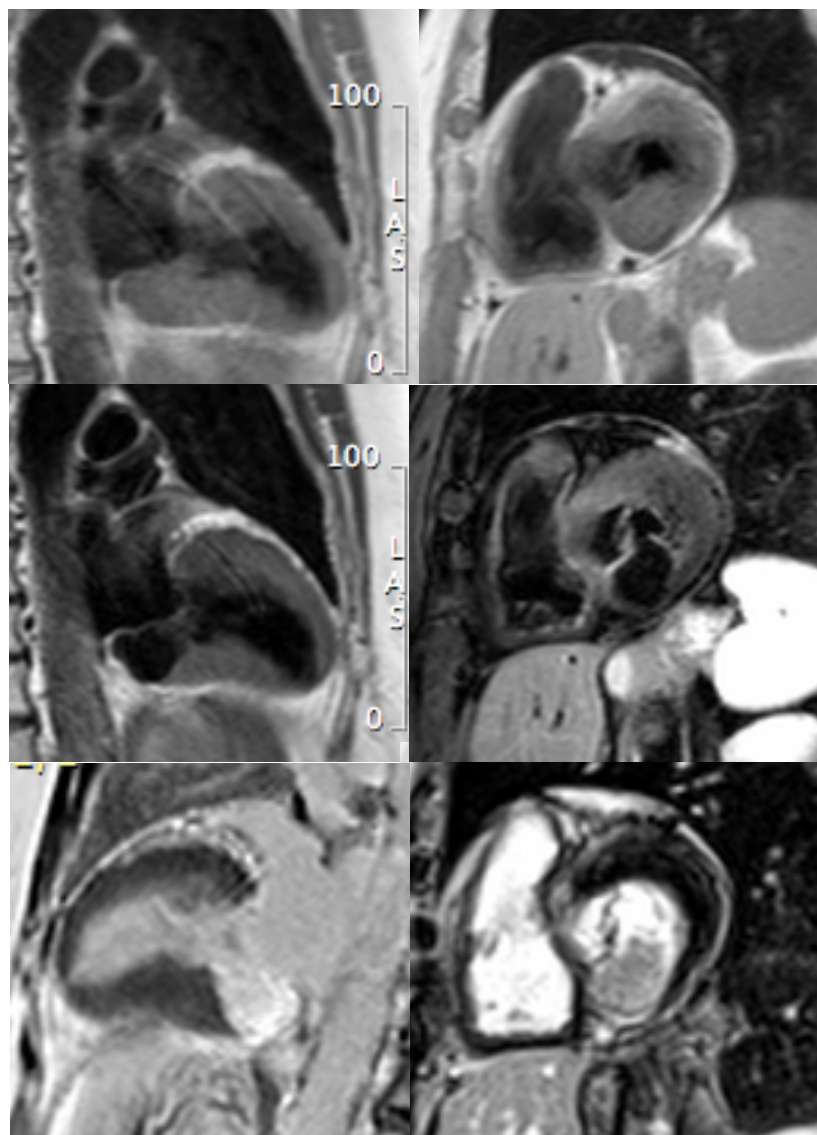


“Formazione iso-iperintensa nelle sequenze T1 pesate, ipointensa nelle sequenze T2 pesate, dopo iniezione di mdc in fase precoce (first pass) disomogeneamente ipoperfusa, omogeneo LE in fase tardiva con rim perilesionale. Conclusione: compatibile con lesione di tipo fibromatoso”





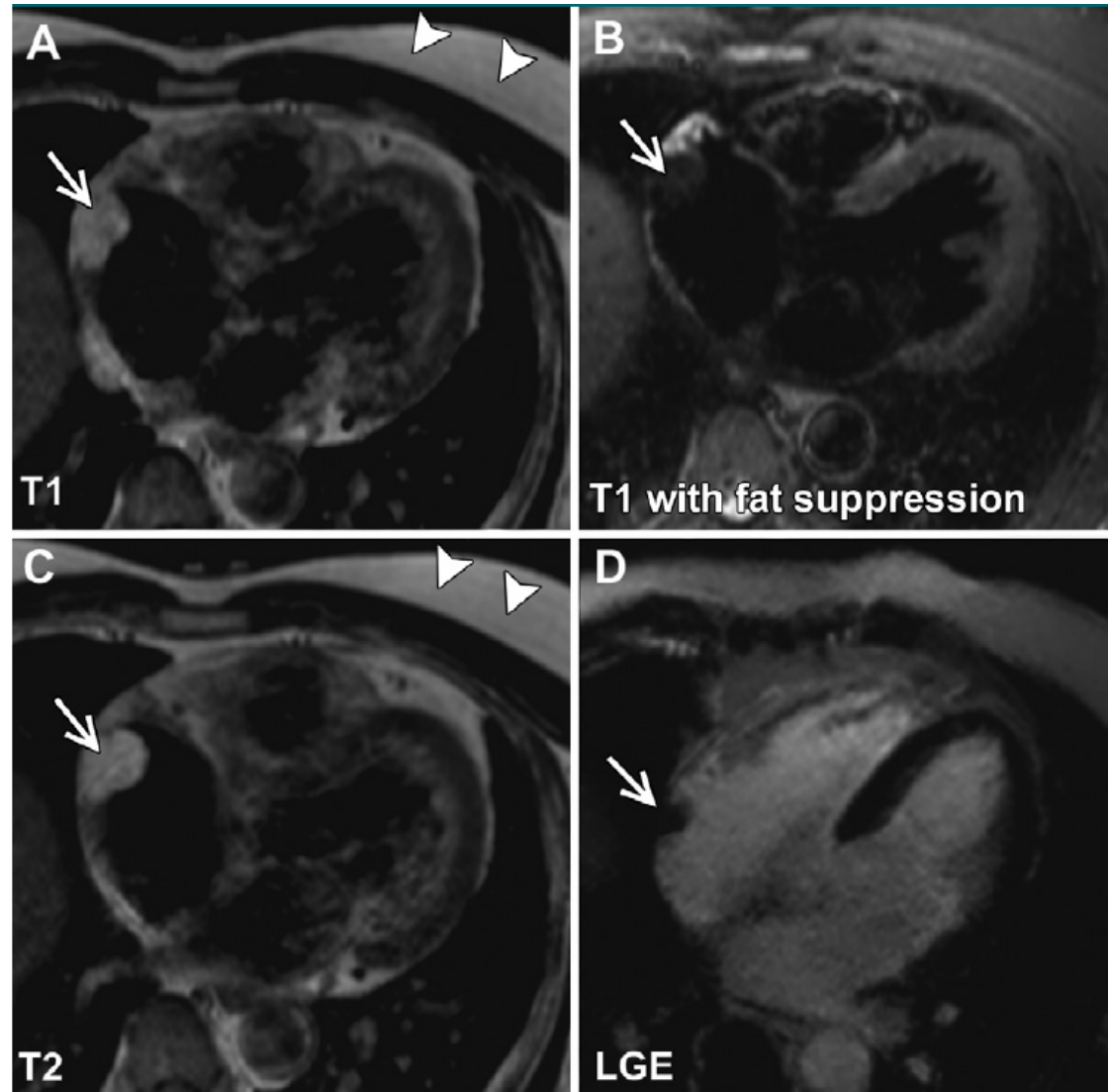
“Formazione iso-iperintensa nelle sequenze T1 pesate, ipointensa nelle sequenze T2 pesate, dopo iniezione di mdc in fase precoce (first pass) disomogeneamente ipoperfusa, omogeneo LE in fase tardiva con rim perilesionale. Conclusione: compatibile con lesione di tipo fibromatoso”





- Lipomas are a common type of benign tumor and account for about 10% of all primary cardiac tumors.
- They are well defined, homogeneous, encapsulated tumors containing neoplastic adipose cells.
- The majority arise from the epicardial surface and can extend into the pericardial space; subendocardial lipomas are less common and tend to be smaller and sessile.
- The key diagnostic finding on cardiac MR images is homogeneous high signal intensity (relative to myocardium) on T1-w images that markedly suppresses with the application of additional fat-saturation prepulses (SPIR). Lipomas are avascular and do not enhance with contrast material.

Clinical case: lipoma

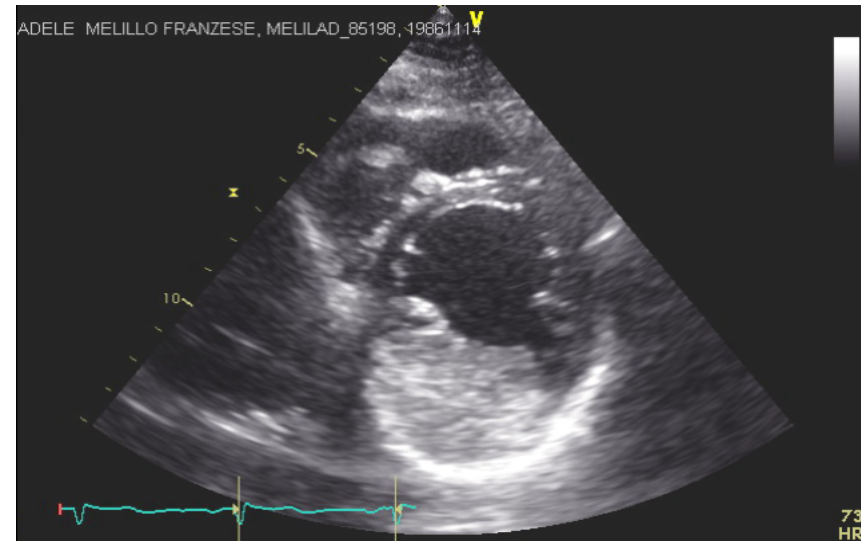
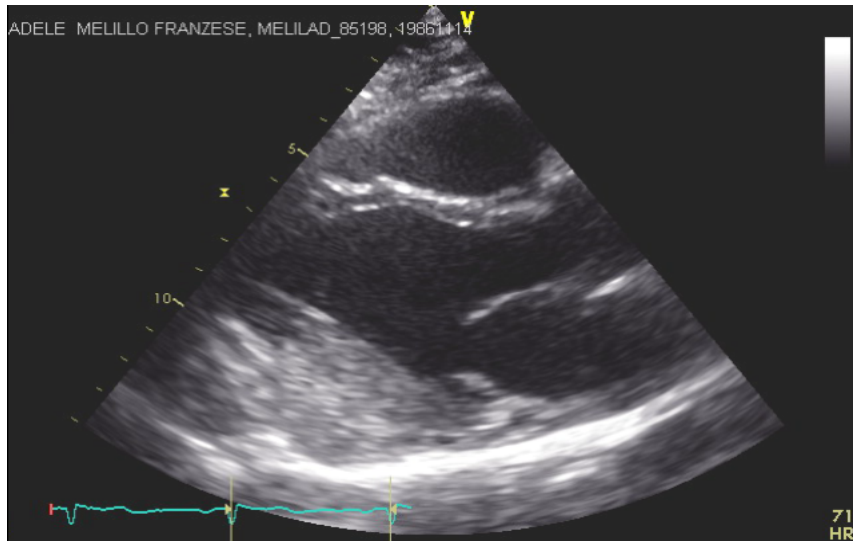




- Cardiac hemangiomas are vascular tumors that account for 5%—10% of all primary benign cardiac tumors.
- They are typically solitary and found in either ventricle but can be located in any chamber.
- Histologically they can be capillary, cavernous, or arteriovenous in nature.
- On cardiac MR images, hemangiomas are typically heterogenous and hyperintense on T1- and T2-w images owing to slow blood flow. During and after contrast agent administration they are intensely hyperintense due to their vascular content— but there may be regions of inhomogeneity owing to calcification or fibrous septa.

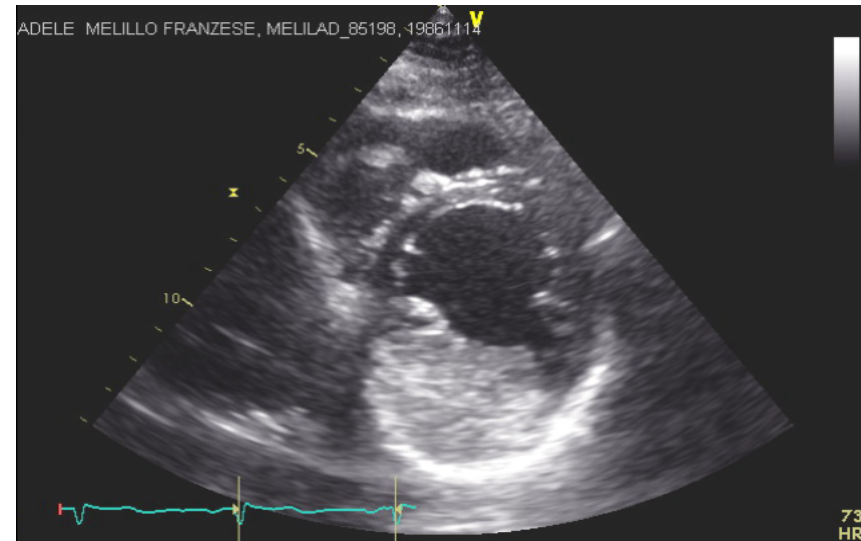
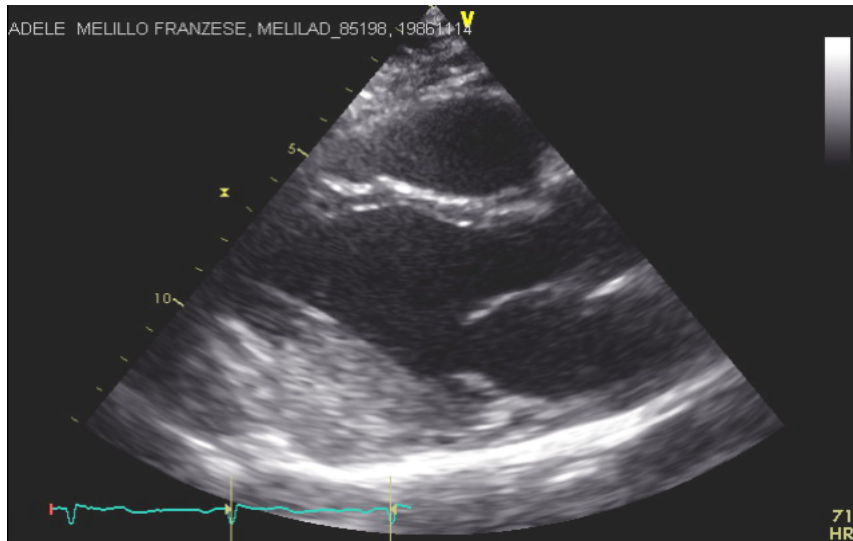
Clinical case: hemangioma

- Female, 28 years old
- Negative T waves on the ECG



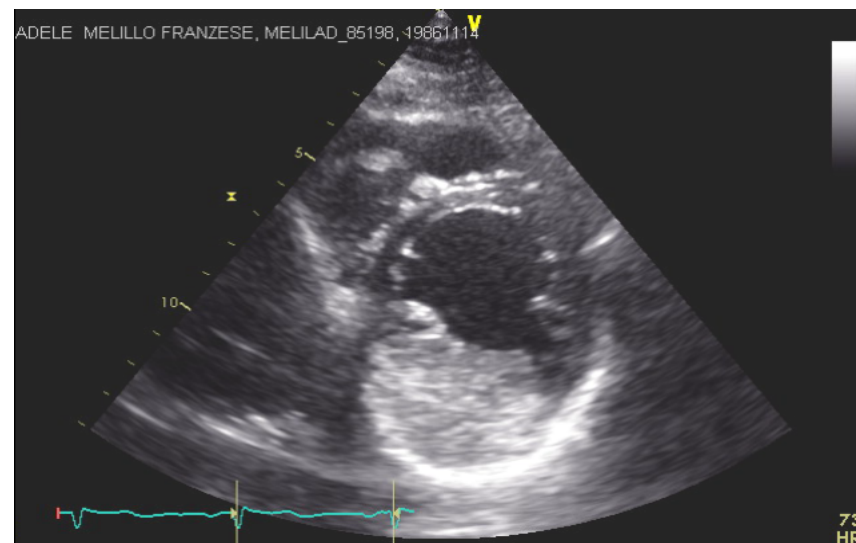
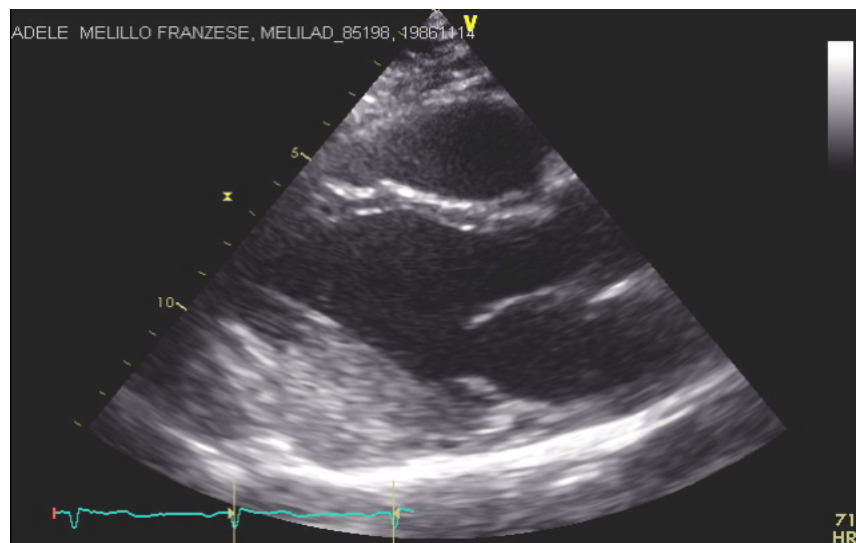
Clinical case: hemangioma

- Female, 28 years old
- Negative T waves on the ECG



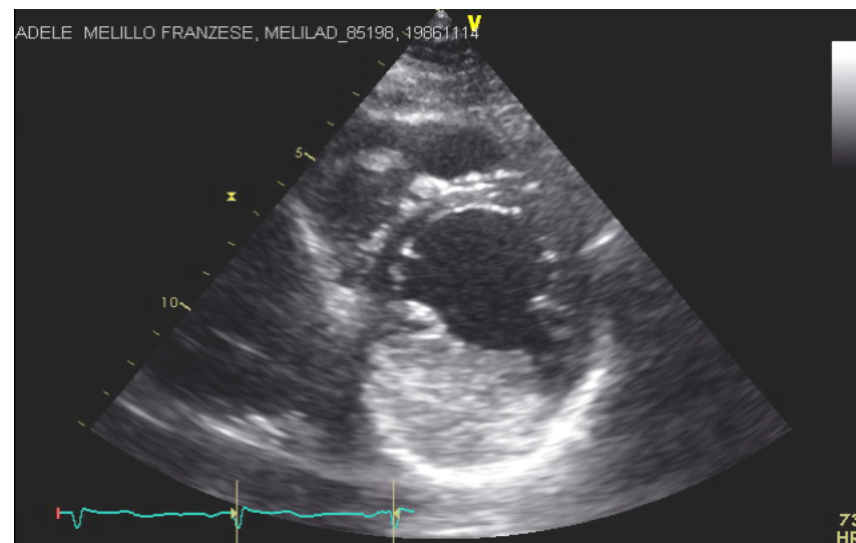
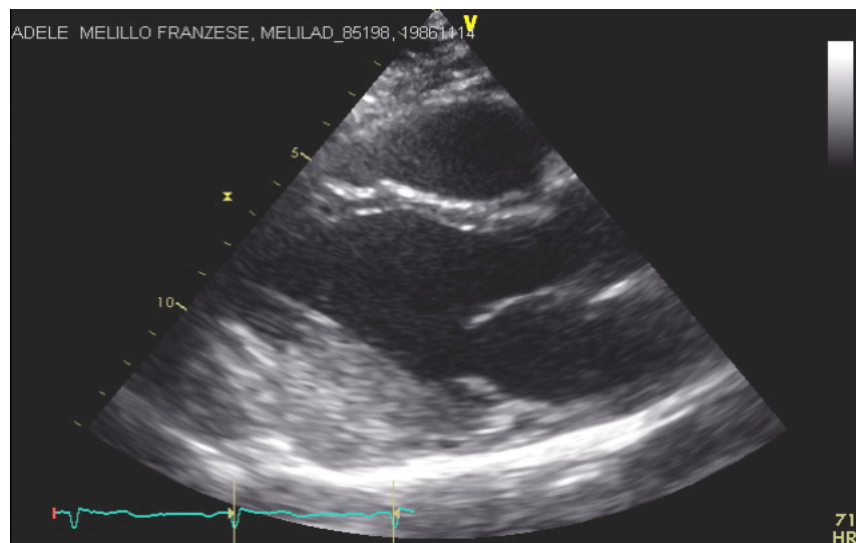
Clinical case: hemangioma

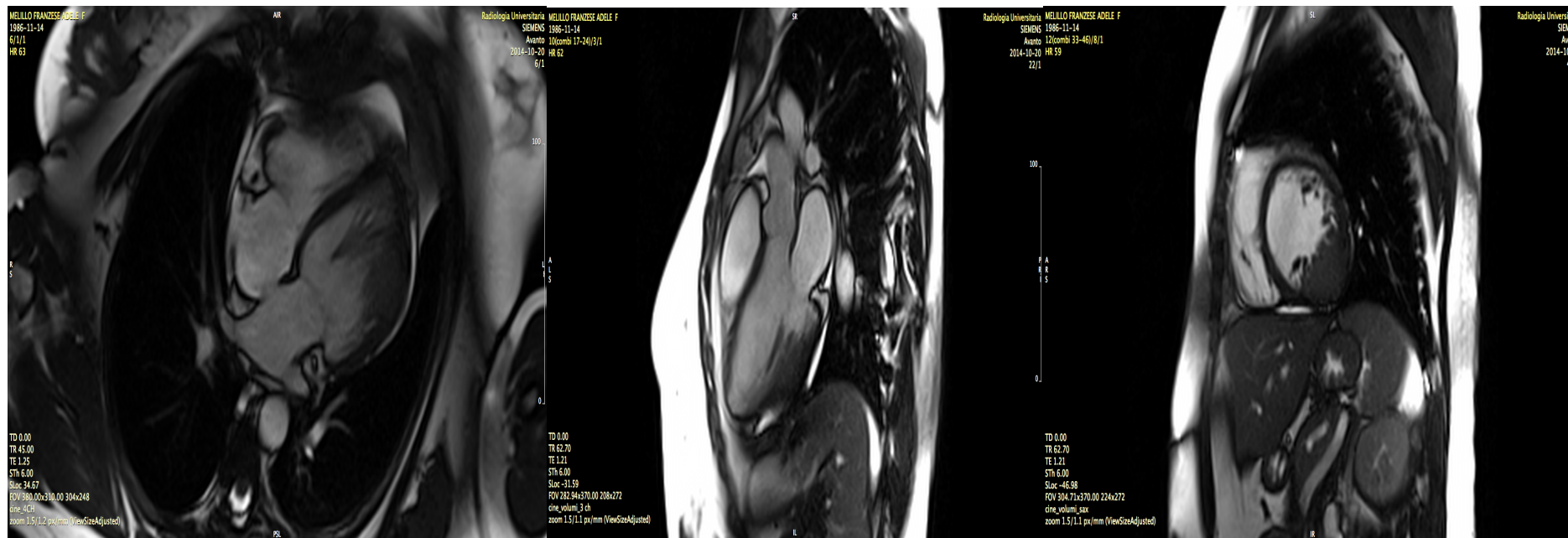
- Female, 28 years old
- Negative T waves on the ECG



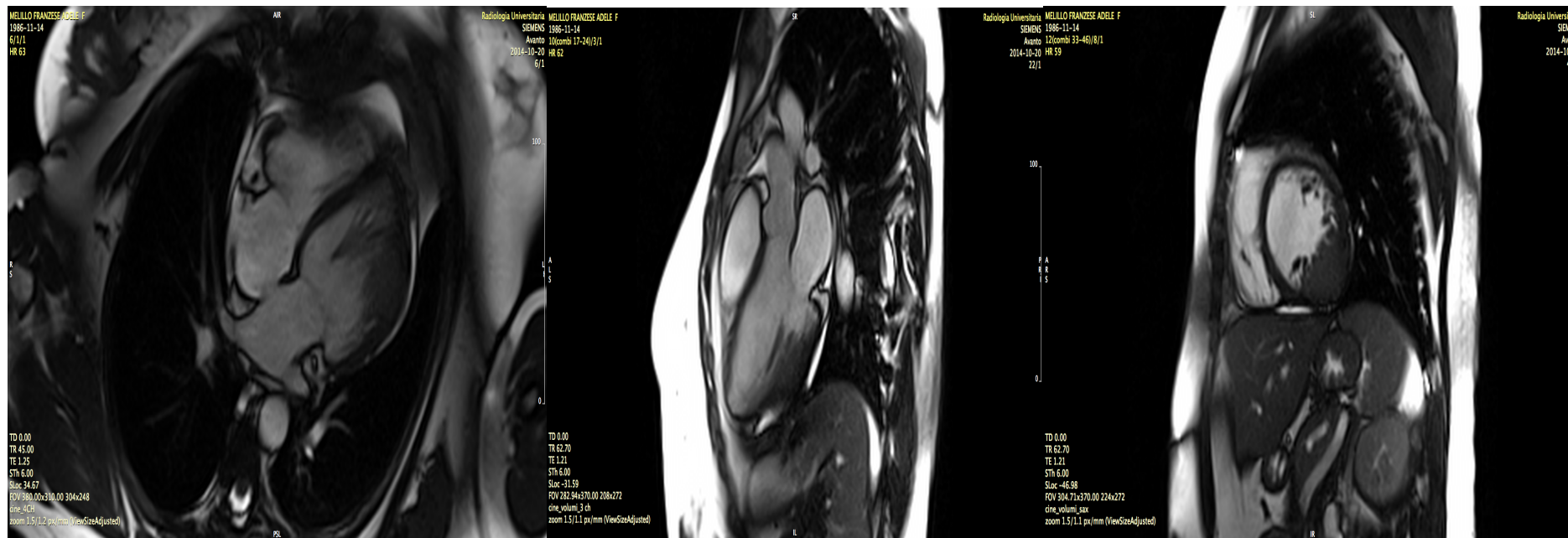
Clinical case: hemangioma

- Female, 28 years old
- Negative T waves on the ECG

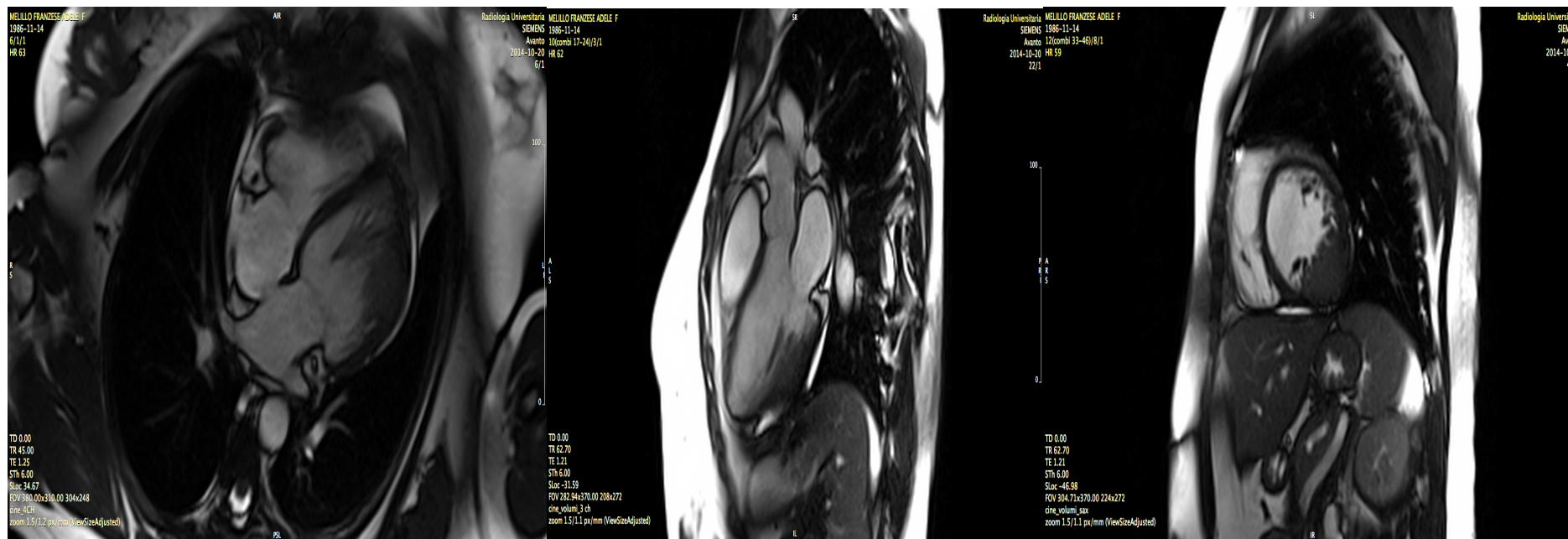




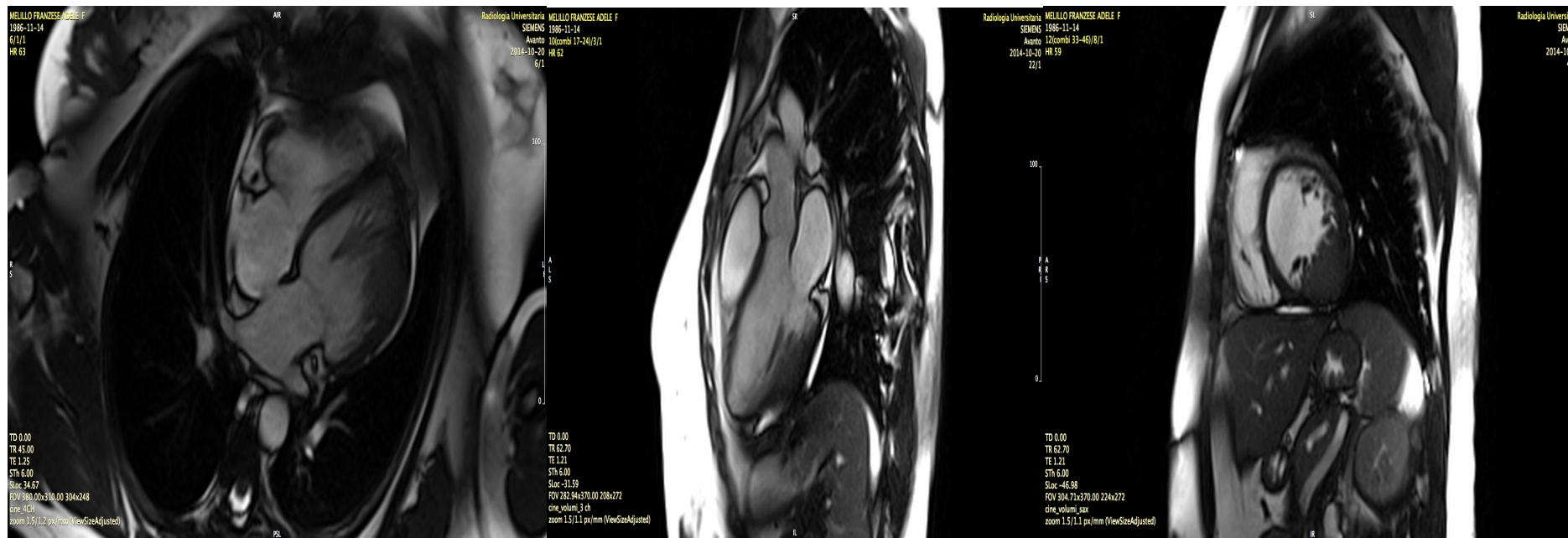
“Le pareti infero-laterale ed inferiore media del ventricolo sinistro risultano sostituite da formazione con effetto massa, con morfologia a clessidra, delle dimensioni 5x4x3,3 cm, apparentemente non contrattile, protudente in ventricolo sinistro e che determina bozzatura del profilo epicardico.”



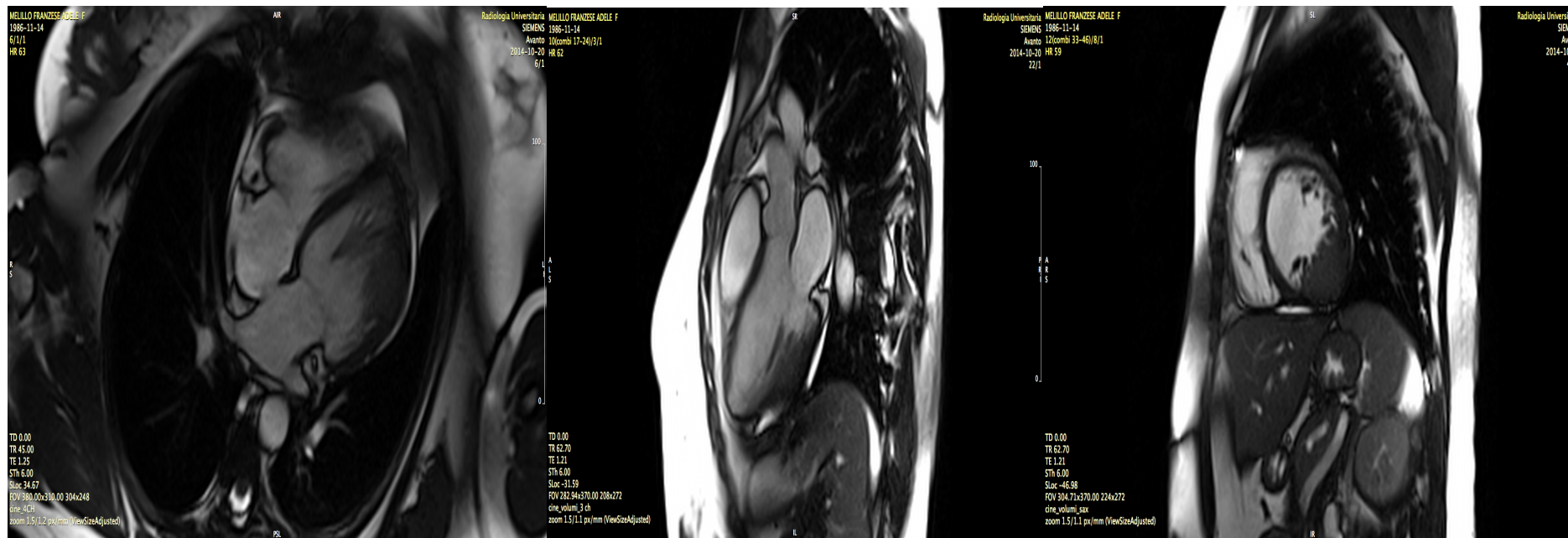
“Le pareti infero-laterale ed inferiore media del ventricolo sinistro risultano sostituite da formazione con effetto massa, con morfologia a clessidra, delle dimensioni 5x4x3,3 cm, apparentemente non contrattile, protudente in ventricolo sinistro e che determina bozzatura del profilo epicardico.”



“Le pareti infero-laterale ed inferiore media del ventricolo sinistro risultano sostituite da formazione con effetto massa, con morfologia a clessidra, delle dimensioni 5x4x3,3 cm, apparentemente non contrattile, protudente in ventricolo sinistro e che determina bozzatura del profilo epicardico.”

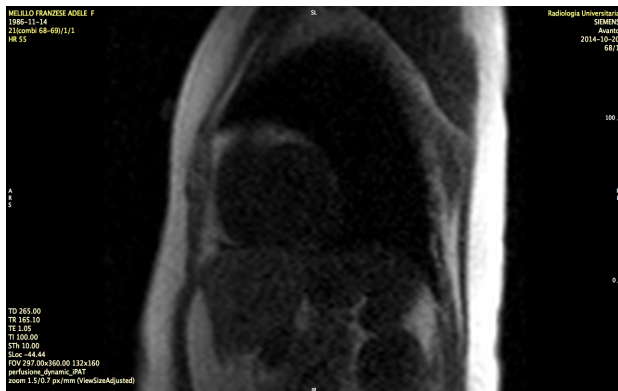

“Le pareti infero-laterale ed inferiore media del ventricolo sinistro risultano sostituite da formazione con effetto massa, con morfologia a clessidra, delle dimensioni 5x4x3,3 cm, apparentemente non contrattile, protudente in ventricolo sinistro e che determina bozzatura del profilo epicardico.”

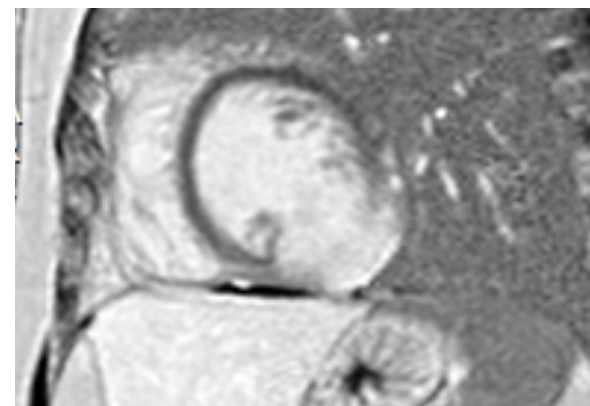
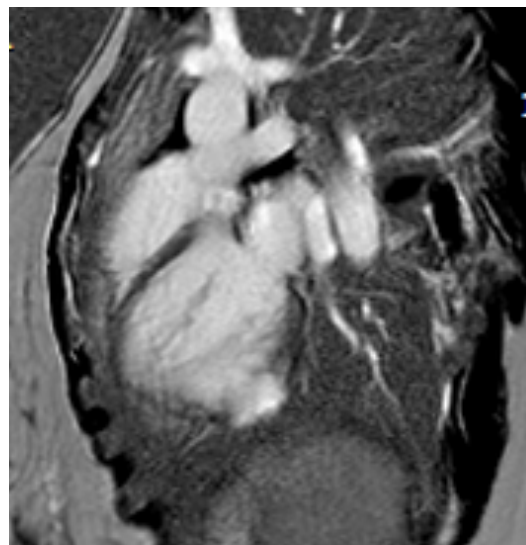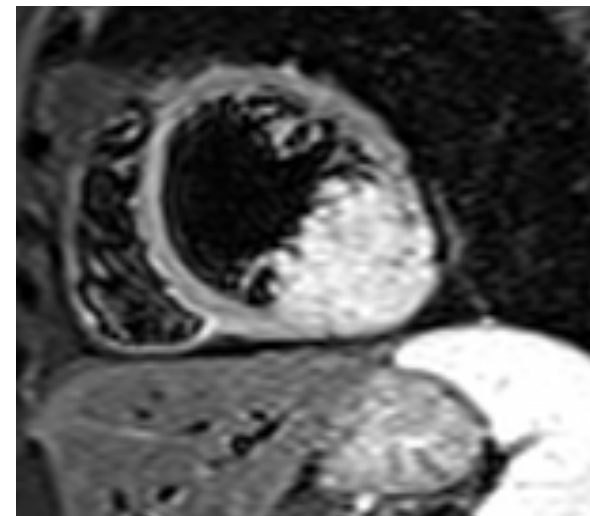
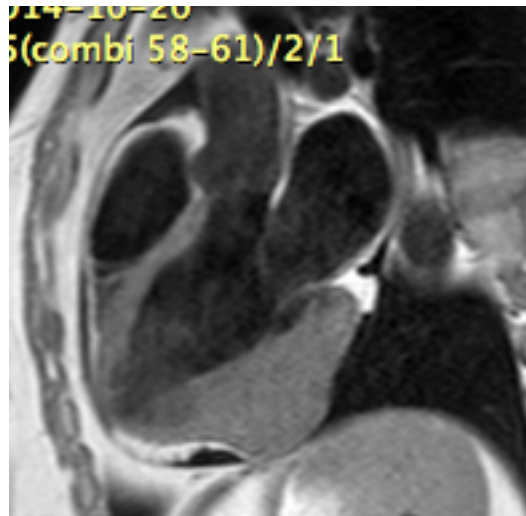


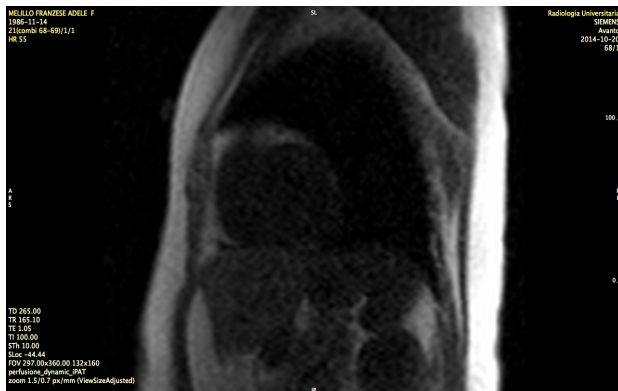
“Le pareti infero-laterale ed inferiore media del ventricolo sinistro risultano sostituite da formazione con effetto massa, con morfologia a clessidra, delle dimensioni 5x4x3,3 cm, apparentemente non contrattile, protudente in ventricolo sinistro e che determina bozzatura del profilo epicardico.”

Clinical case: hemangioma

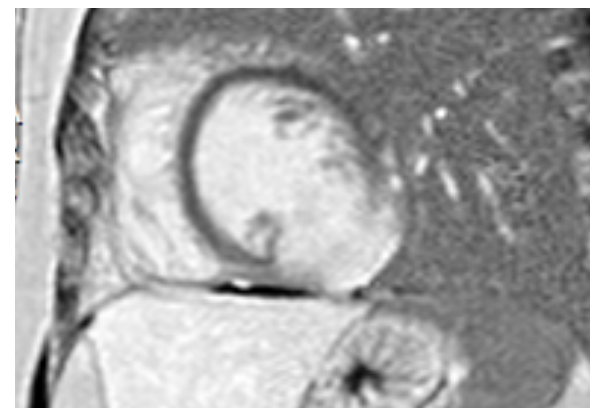
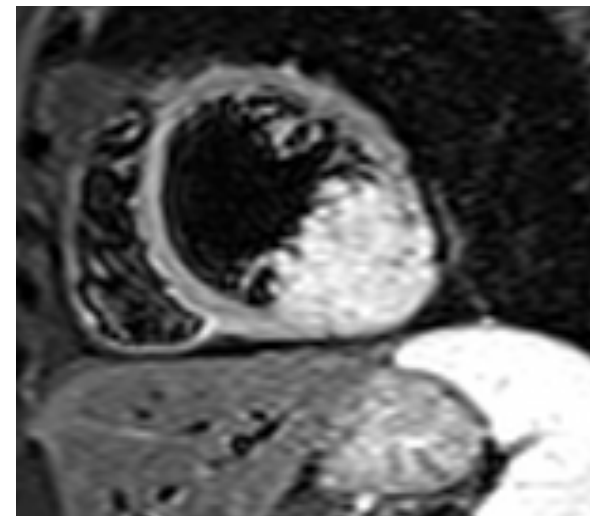
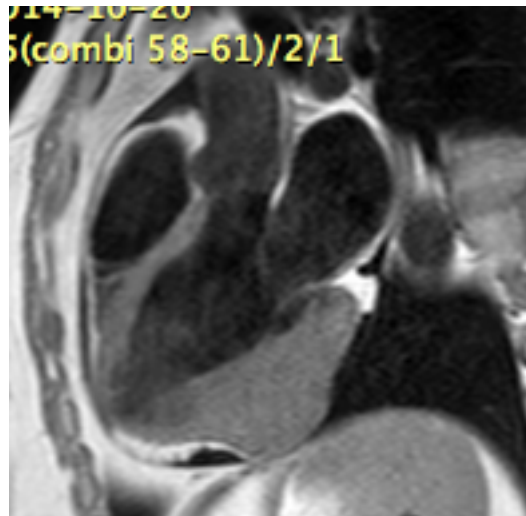


“Isointensa nelle sequenze T1 pesate, iperintensa nelle TIRM. Dopo somministrazione di mdc in fase precoce (first pass), la formazione si presenta ipervascolarizzata rispetto al miocardio. Omogeneo enhancement in fase tardiva. Non evidenti piani di clivaggio. Conclusione: compatibile con emangioma”



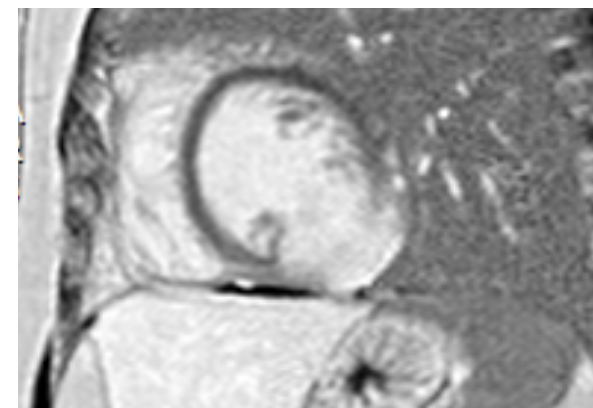
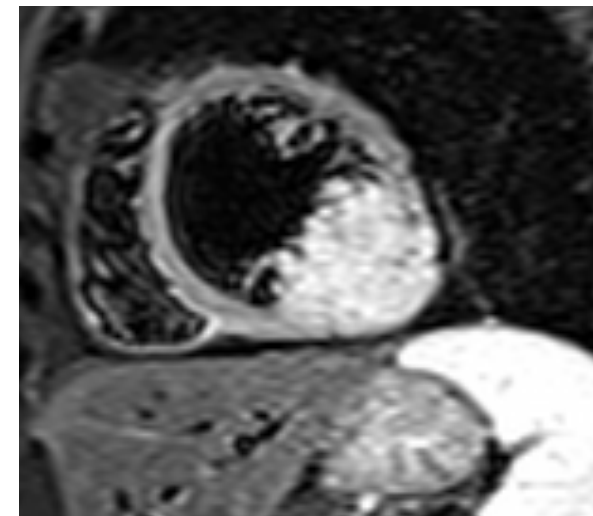
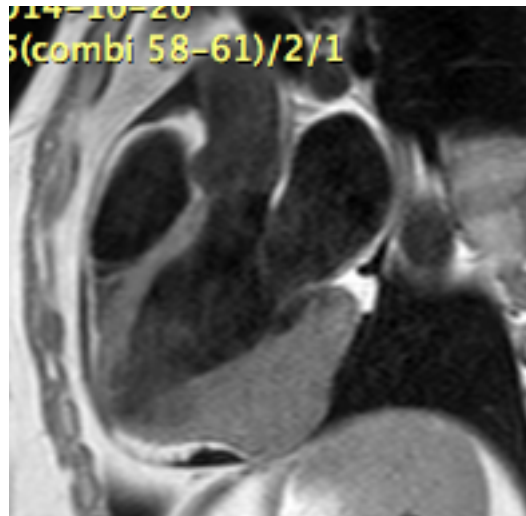


“Isointensa nelle sequenze T1 pesate, iperintensa nelle TIRM. Dopo somministrazione di mdc in fase precoce (first pass), la formazione si presenta ipervascolarizzata rispetto al miocardio. Omogeneo enhancement in fase tardiva. Non evidenti piani di clivaggio. Conclusione: compatibile con emangioma”





“Isointensa nelle sequenze T1 pesate, iperintensa nelle TIRM. Dopo somministrazione di mdc in fase precoce (first pass), la formazione si presenta ipervascolarizzata rispetto al miocardio. Omogeneo enhancement in fase tardiva. Non evidenti piani di clivaggio. Conclusione: compatibile con emangioma”





- Malignant primary cardiac tumors are very rare.
- The majority (95%) of these malignant primary cardiac tumors are sarcomas.
- Sarcomas occur mainly in adulthood, usually between the third and fifth decades of life, and carry an extremely poor prognosis
- Angiosarcomas are the most common primary cardiac malignancy in adulthood and rhabdomyosarcomas are the most common in childhood (4,76).
- Angiosarcomas typically originate in the right atrium and usually present with right heart failure, hemorrhagic pericardial effusions, or metastases.
- Microscopically, angiosarcomas consist of rapidly proliferating, extensively infiltrating anaplastic cells derived from blood vessels and lining irregular blood-filled spaces, and there are usually large regions of hemorrhage and necrosis within the tumor.
- Macroscopically, there are two morphologic variants: The “focal” variety is typically a well-defined mass protruding into the right atrium, causing serious intracavitary obstruction; the “diffuse” variety is a more extensive mass that rapidly infiltrates the right ventricle and pericardium that manifests with right-sided heart failure or tamponade.

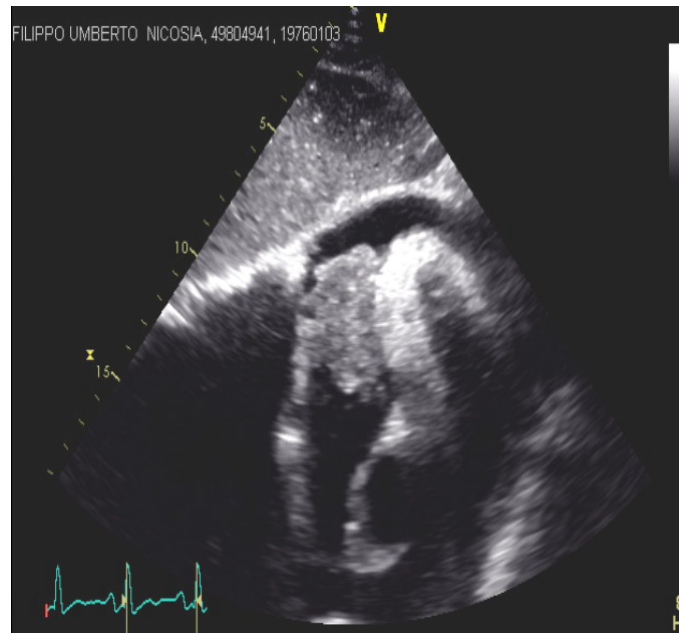
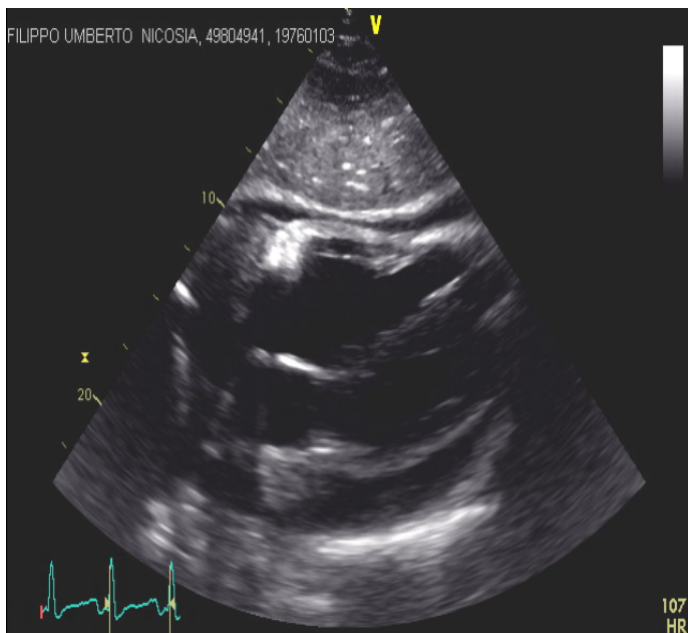
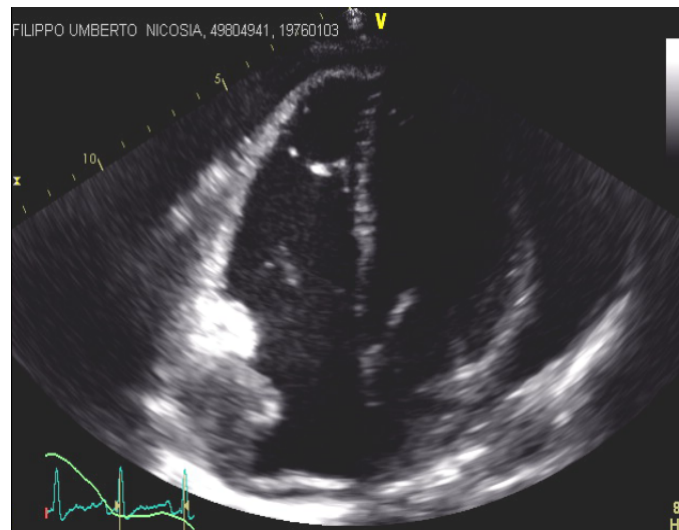


- MRI demonstrate large heterogenous right atrial mass with or without pericardial involvement (thickening, effusion, nodularity, frank disruption of fat planes); heterogenous T1- and T2-w signal intensity patterns that reflect tumor tissue, necrosis, and hemorrhage; arterial phase enhancement at first-pass perfusion owing to vascularity; and heterogenous enhancement at LGE imaging owing to peripheral fibrosis (surface hyperintensity) and focal hypointensity due to central necrosis.

Cardiac Mass	T1w*	T1w fat sat*	T2w*	LGE
Angiosarcoma	Heterogenous	Heterogenous	Heterogenous	Heterogeneous
Rhabdomyosarcoma	Isointense	Isointense	Hyperintense	Homogeneous
Undifferentiated sarcoma	Isointense	Isointense	Hyperintense	Heterogeneous/ Variable

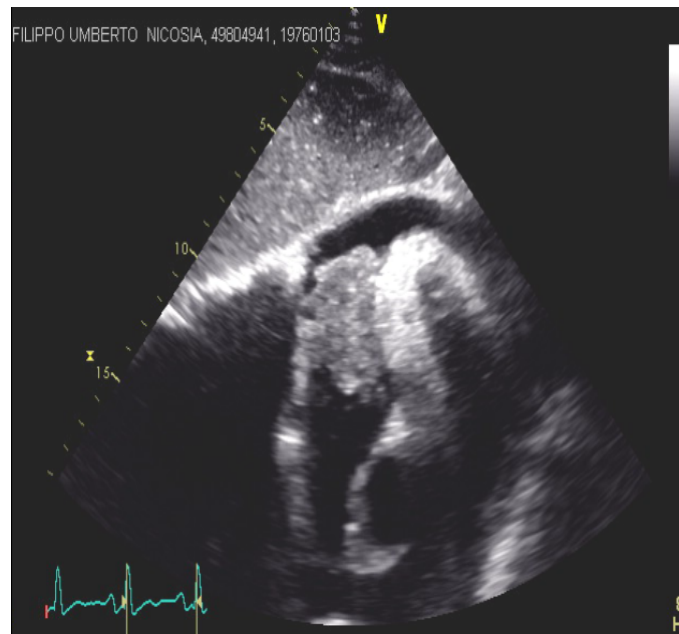
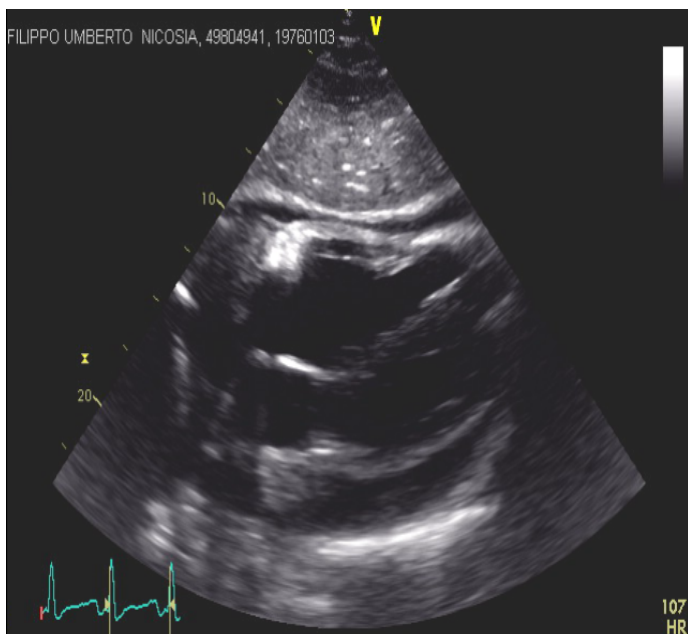
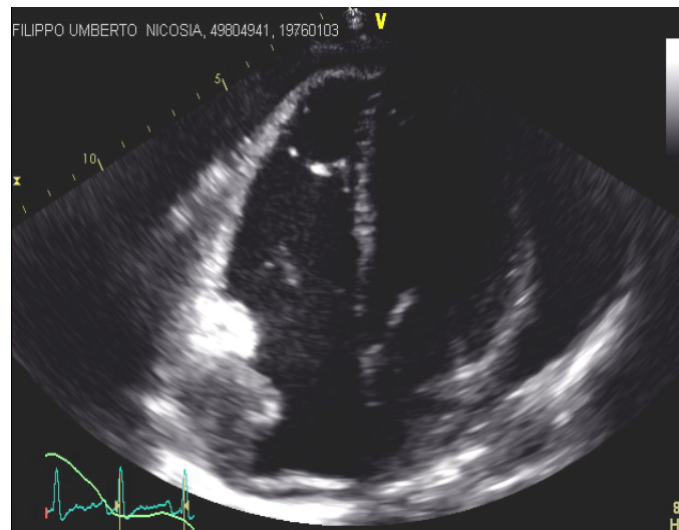
Clinical case: angiosarcoma

- Male, 44 years old
- Nel 2000 LH
- Dyspnoea and palpitation
- Fever



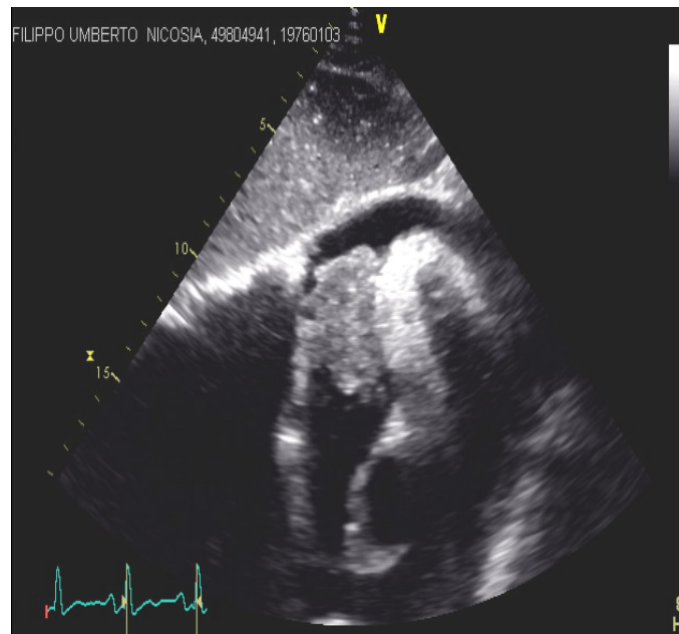
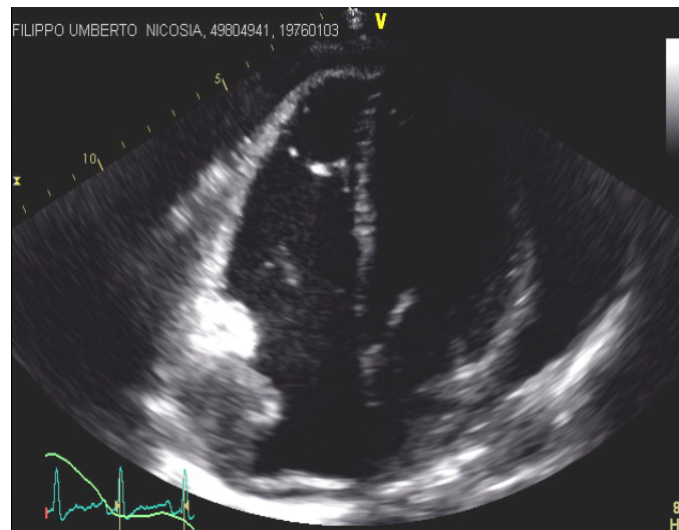
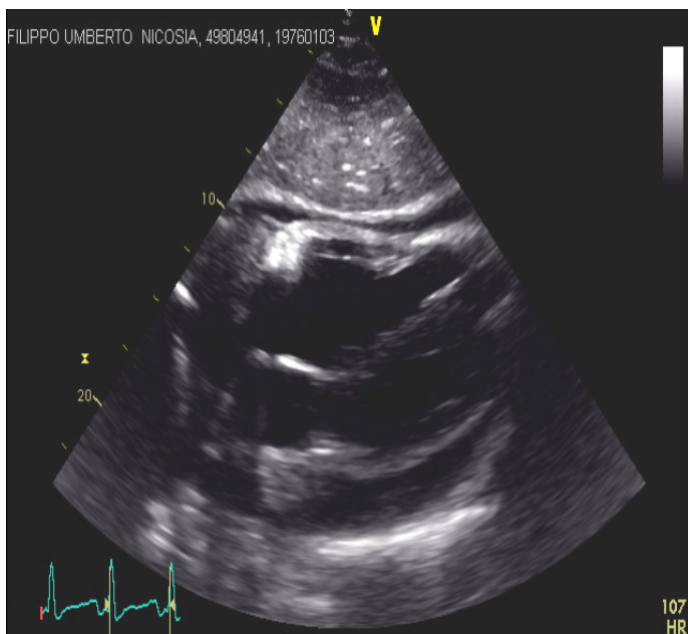
Clinical case: angiosarcoma

- Male, 44 years old
- Nel 2000 LH
- Dyspnoea and palpitation
- Fever



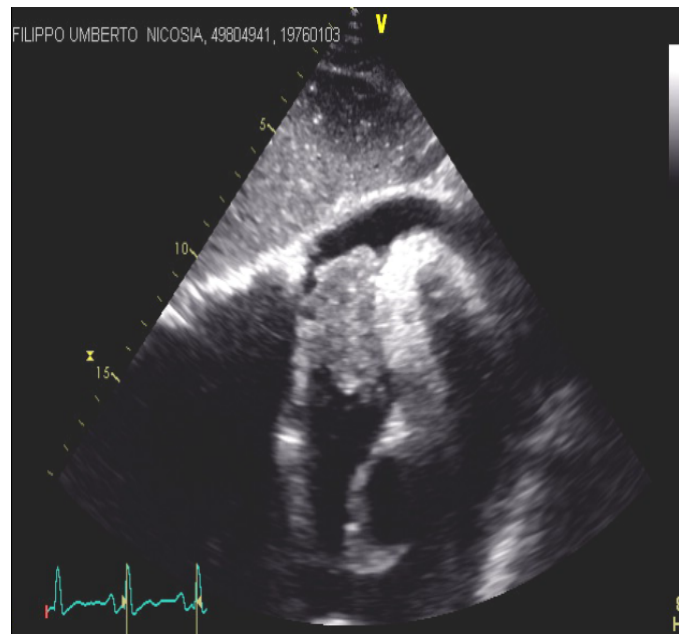
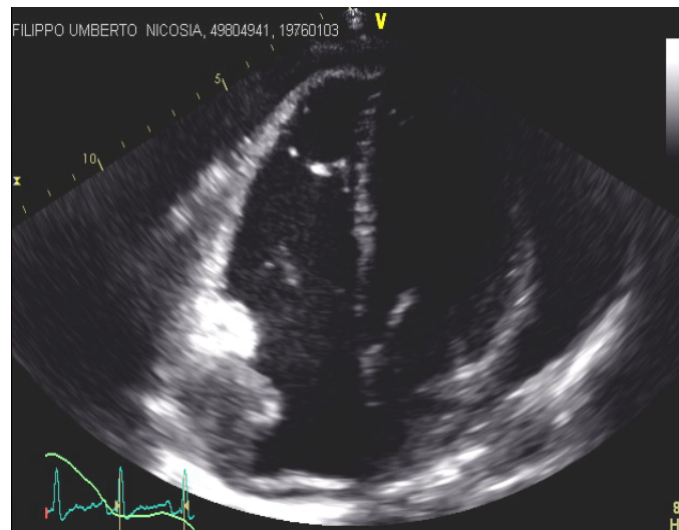
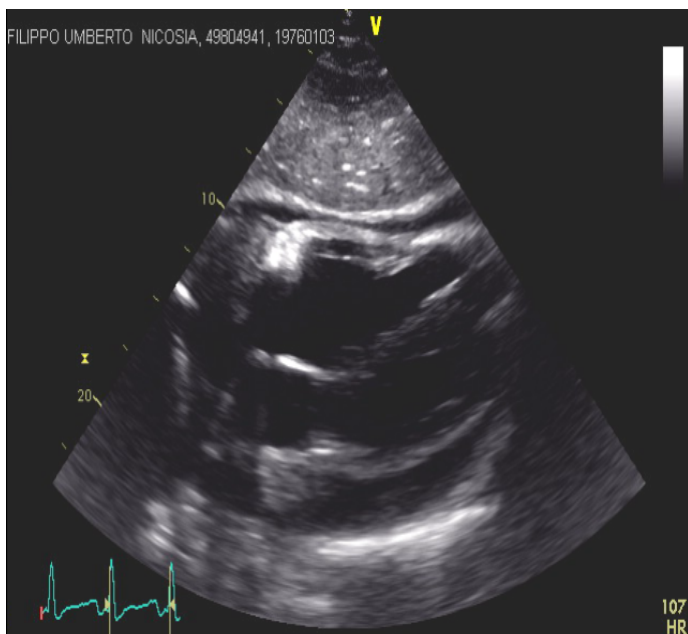
Clinical case: angiosarcoma

- Male, 44 years old
- Nel 2000 LH
- Dyspnoea and palpitation
- Fever



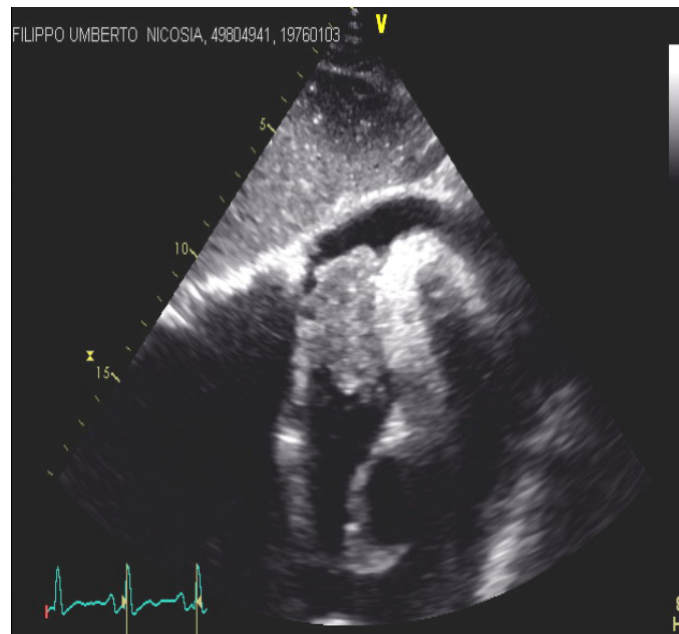
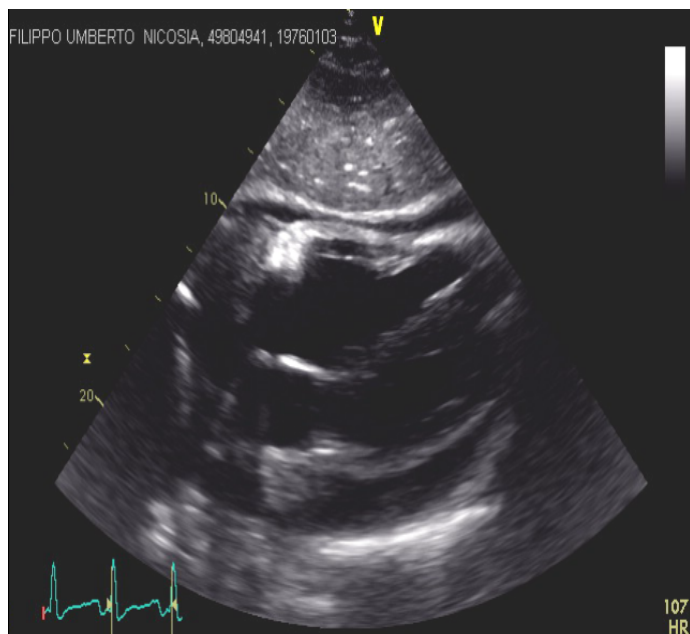
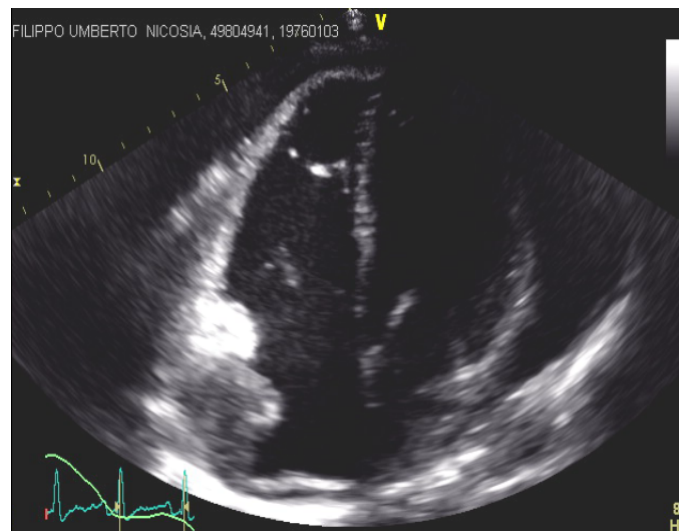
Clinical case: angiosarcoma

- Male, 44 years old
- Nel 2000 LH
- Dyspnoea and palpitation
- Fever

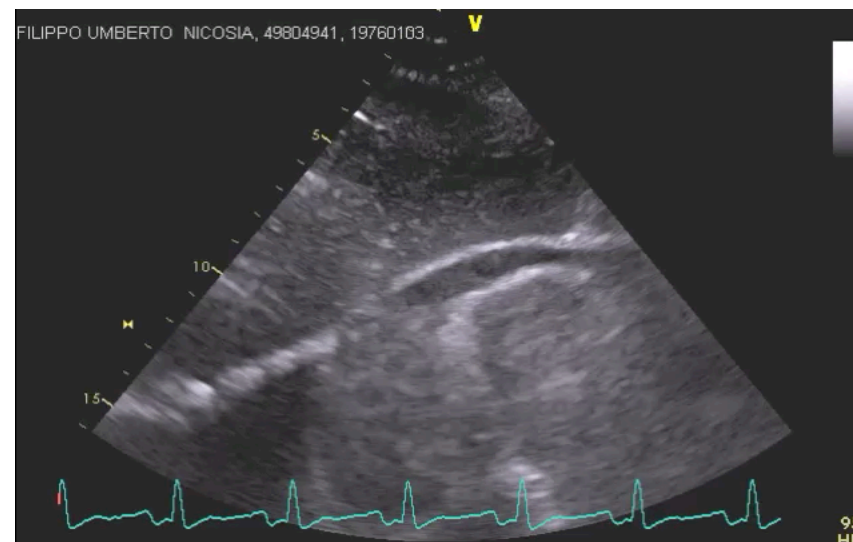
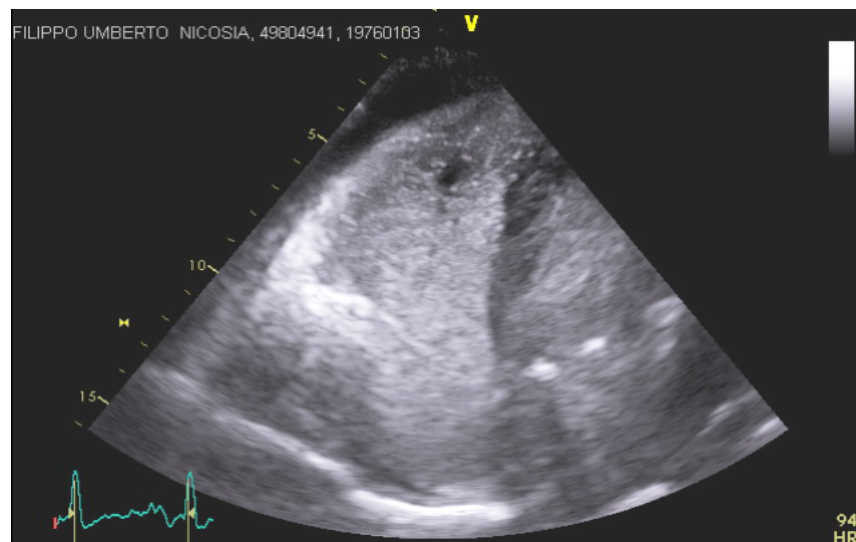


Clinical case: angiosarcoma

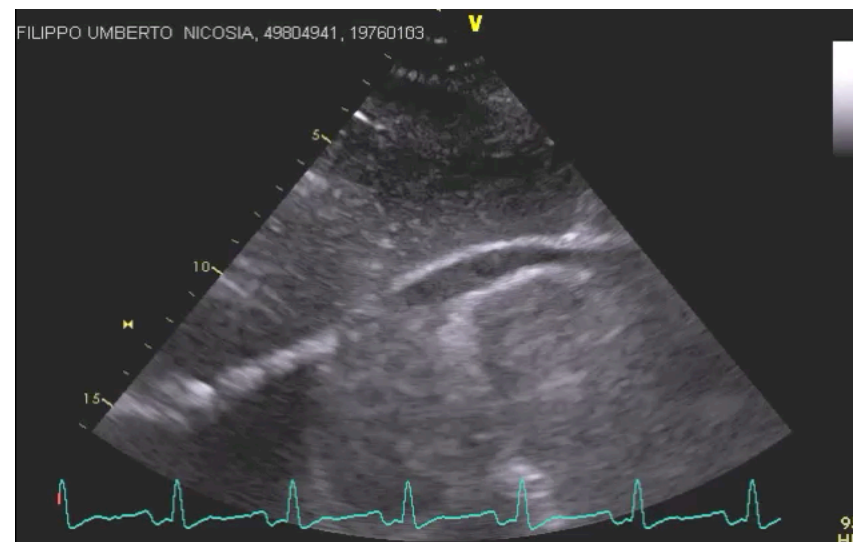
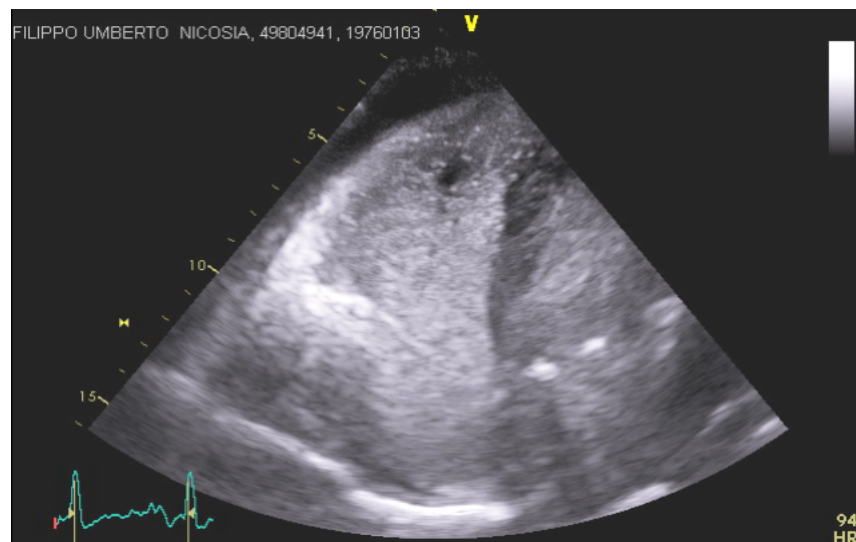
- Male, 44 years old
- Nel 2000 LH
- Dyspnoea and palpitation
- Fever



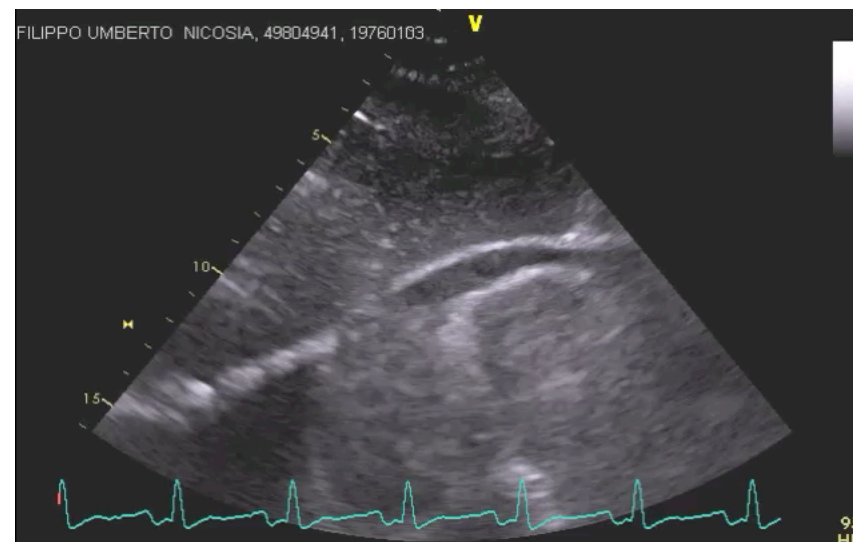
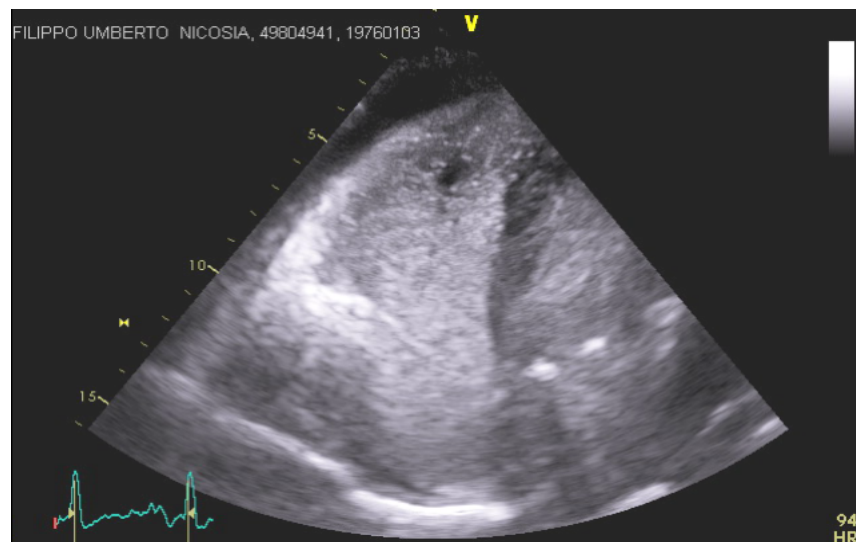
Clinical case: angiosarcoma



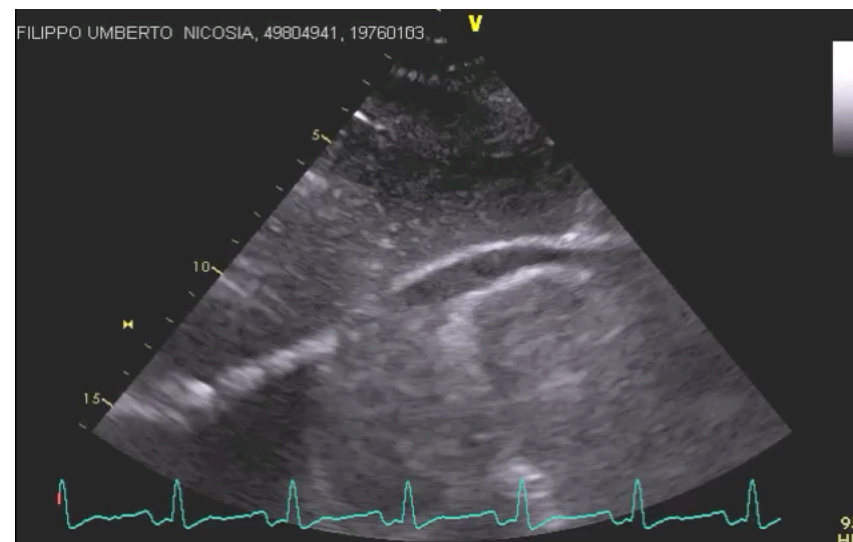
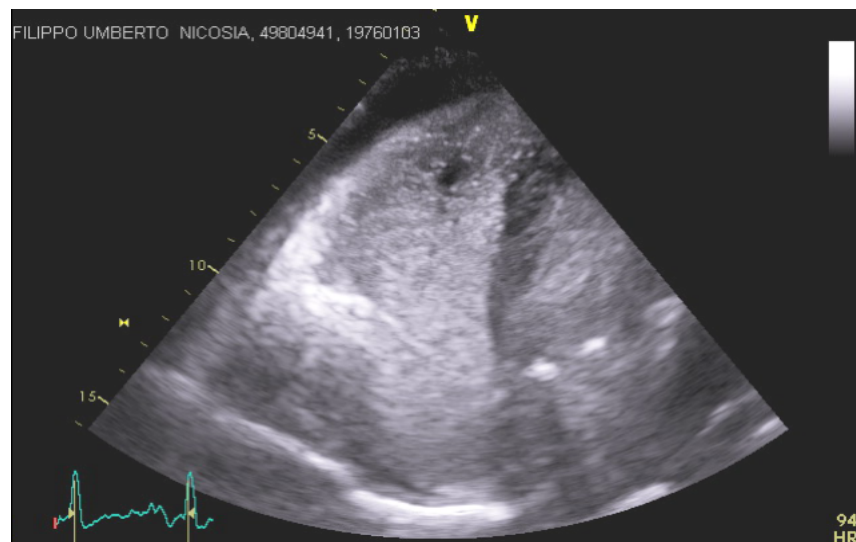
Clinical case: angiosarcoma



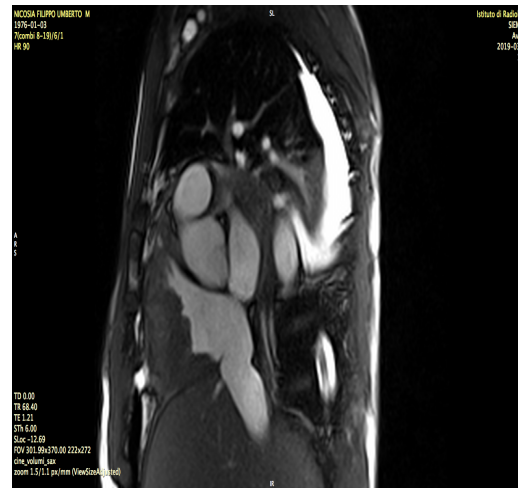
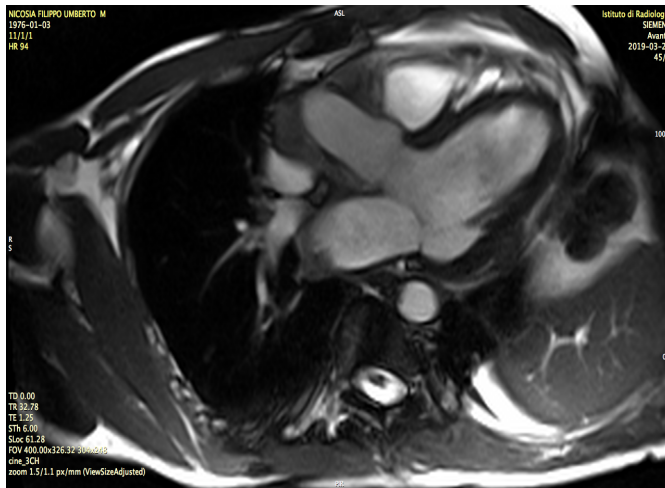
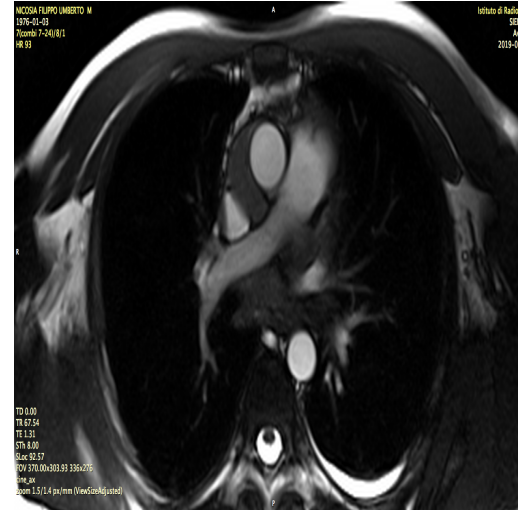
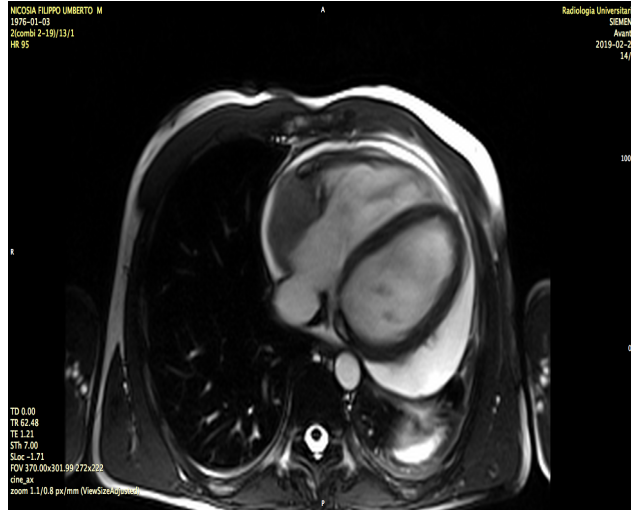
Clinical case: angiosarcoma



Clinical case: angiosarcoma

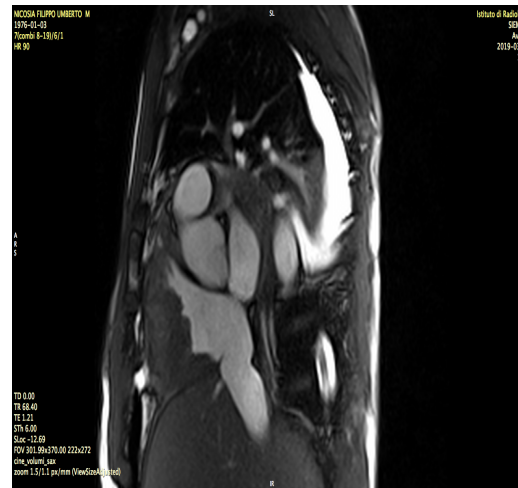
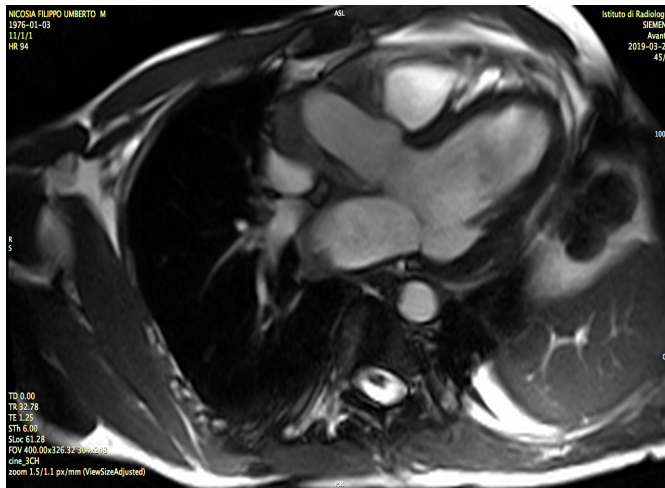
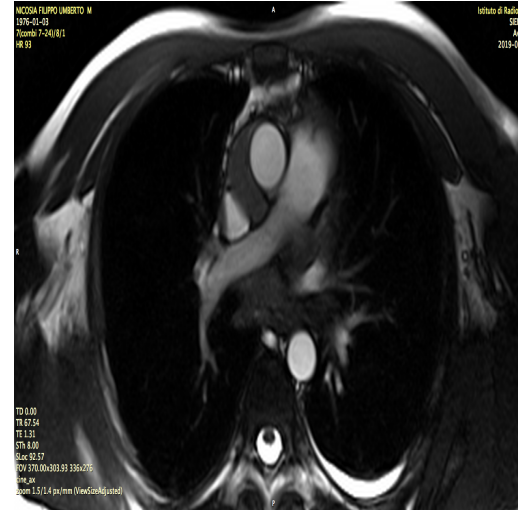
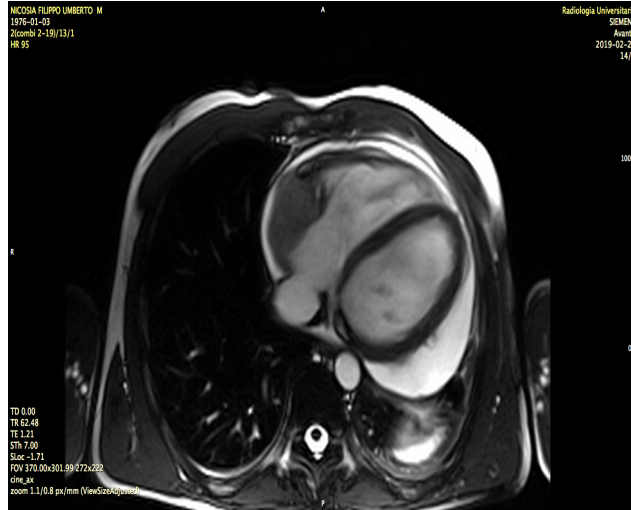


Clinical case: angiosarcoma



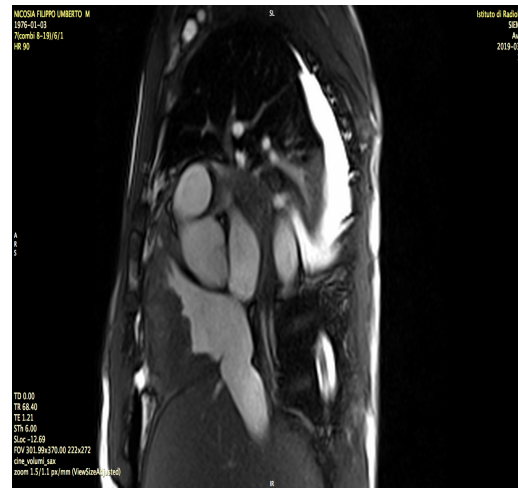
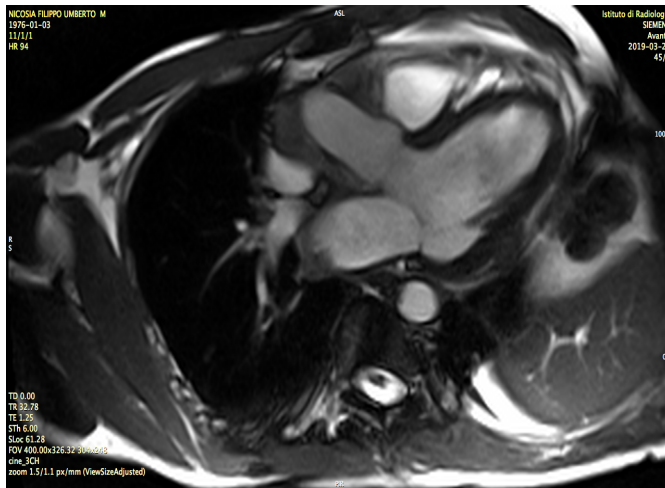
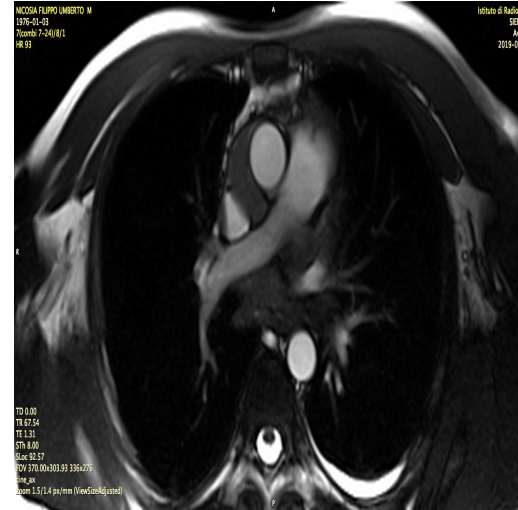
“Foglietti pericardici disomogeneamente ispessiti presentano grossolani noduli solidi in sede inter-aorto-cavale superiore, a ridosso del tetto atriale sinistro, in sede periostiale tra le vene polmonari di sinistra; altra massa di circa 55 x 35 mm, risulta adesa al pericardio viscerale ed infiltra le pareti superiore ed anteriore dell’ atrio destro con una componente aggettante in cavità . ”

Clinical case: angiosarcoma



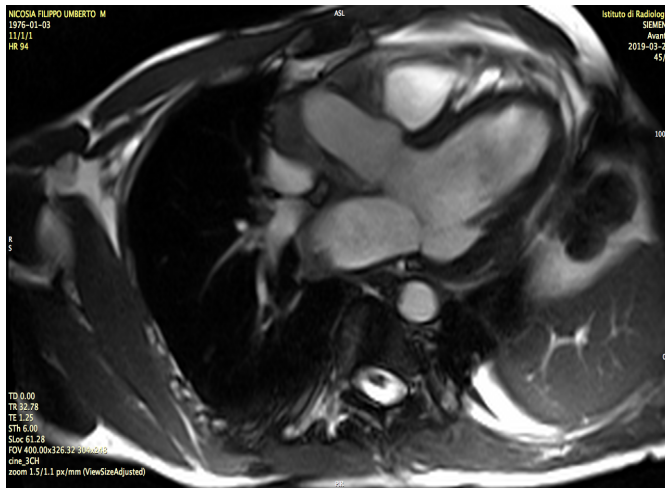
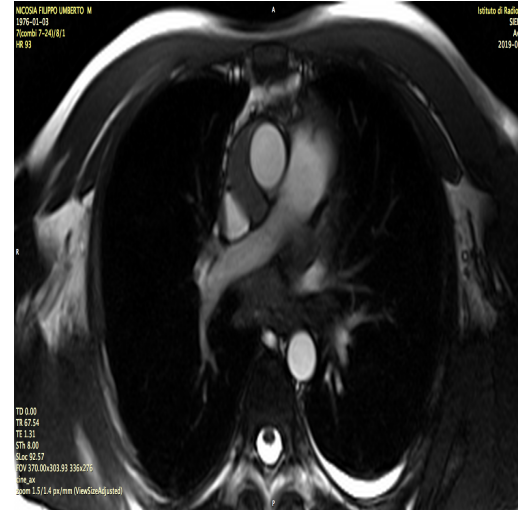
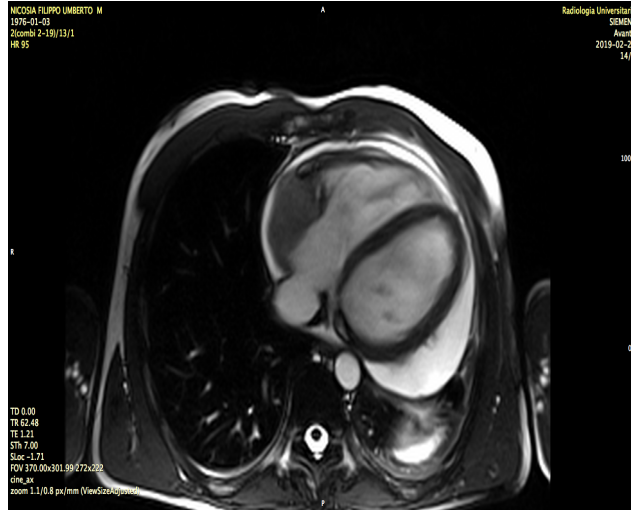
“Foglietti pericardici disomogeneamente ispessiti presentano grossolani noduli solidi in sede inter-aorto-cavale superiore, a ridosso del tetto atriale sinistro, in sede periostiale tra le vene polmonari di sinistra; altra massa di circa 55 x 35 mm, risulta adesa al pericardio viscerale ed infiltra le pareti superiore ed anteriore dell’ atrio destro con una componente aggettante in cavità . ”

Clinical case: angiosarcoma



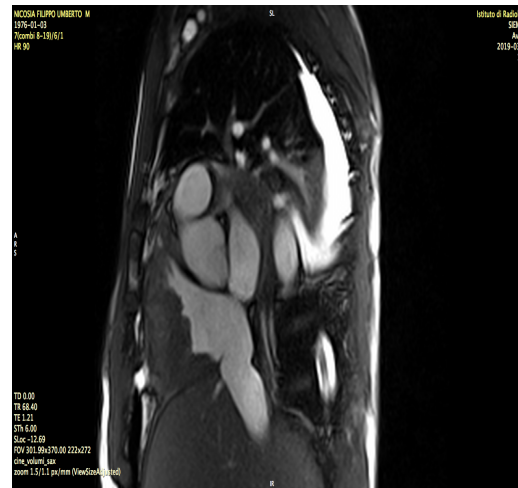
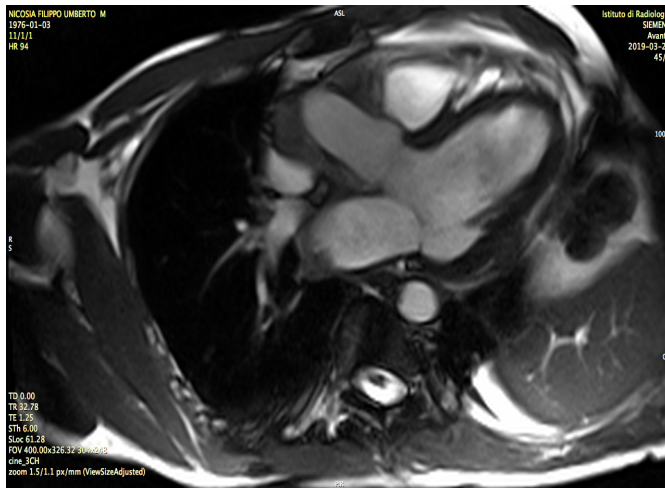
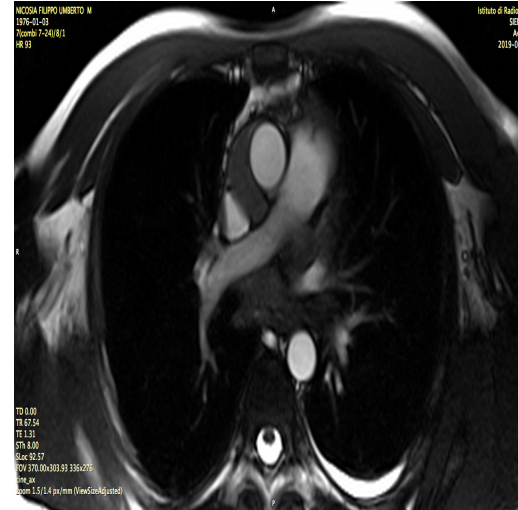
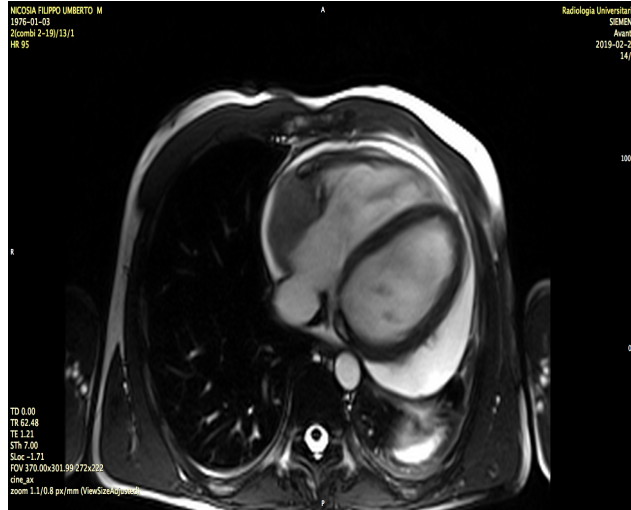
“Foglietti pericardici disomogeneamente ispessiti presentano grossolani noduli solidi in sede inter-aorto-cavale superiore, a ridosso del tetto atriale sinistro, in sede periostiale tra le vene polmonari di sinistra; altra massa di circa 55 x 35 mm, risulta adesa al pericardio viscerale ed infiltra le pareti superiore ed anteriore dell’ atrio destro con una componente aggettante in cavità . ”

Clinical case: angiosarcoma



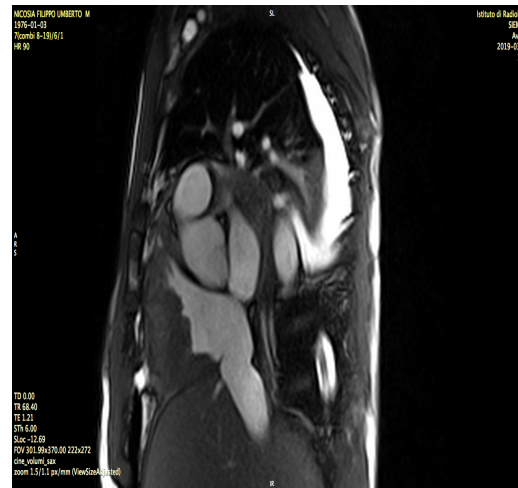
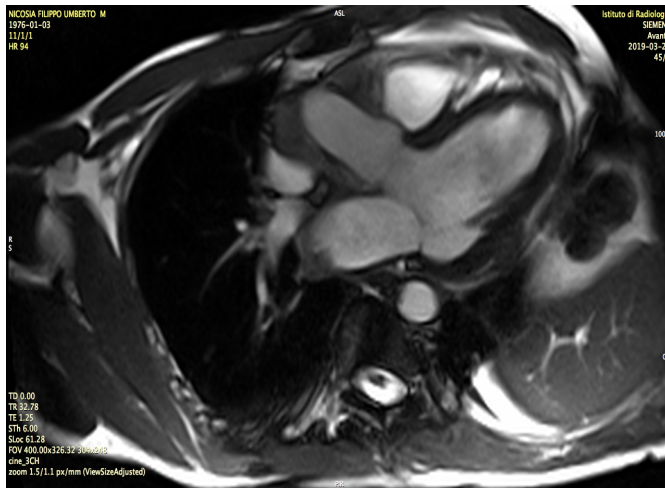
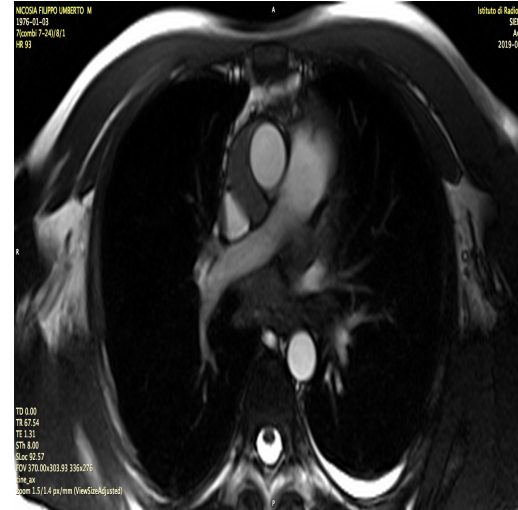
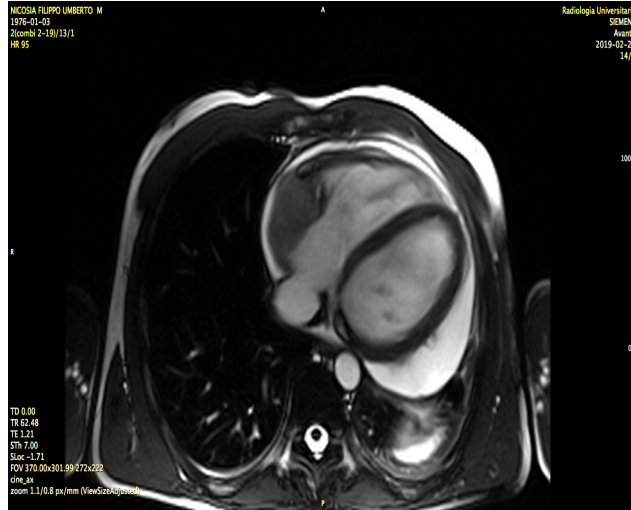
“Foglietti pericardici disomogeneamente ispessiti presentano grossolani noduli solidi in sede inter-aorto-cavale superiore, a ridosso del tetto atriale sinistro, in sede periostiale tra le vene polmonari di sinistra; altra massa di circa 55 x 35 mm, risulta adesa al pericardio viscerale ed infiltra le pareti superiore ed anteriore dell’ atrio destro con una componente aggettante in cavità . ”

Clinical case: angiosarcoma



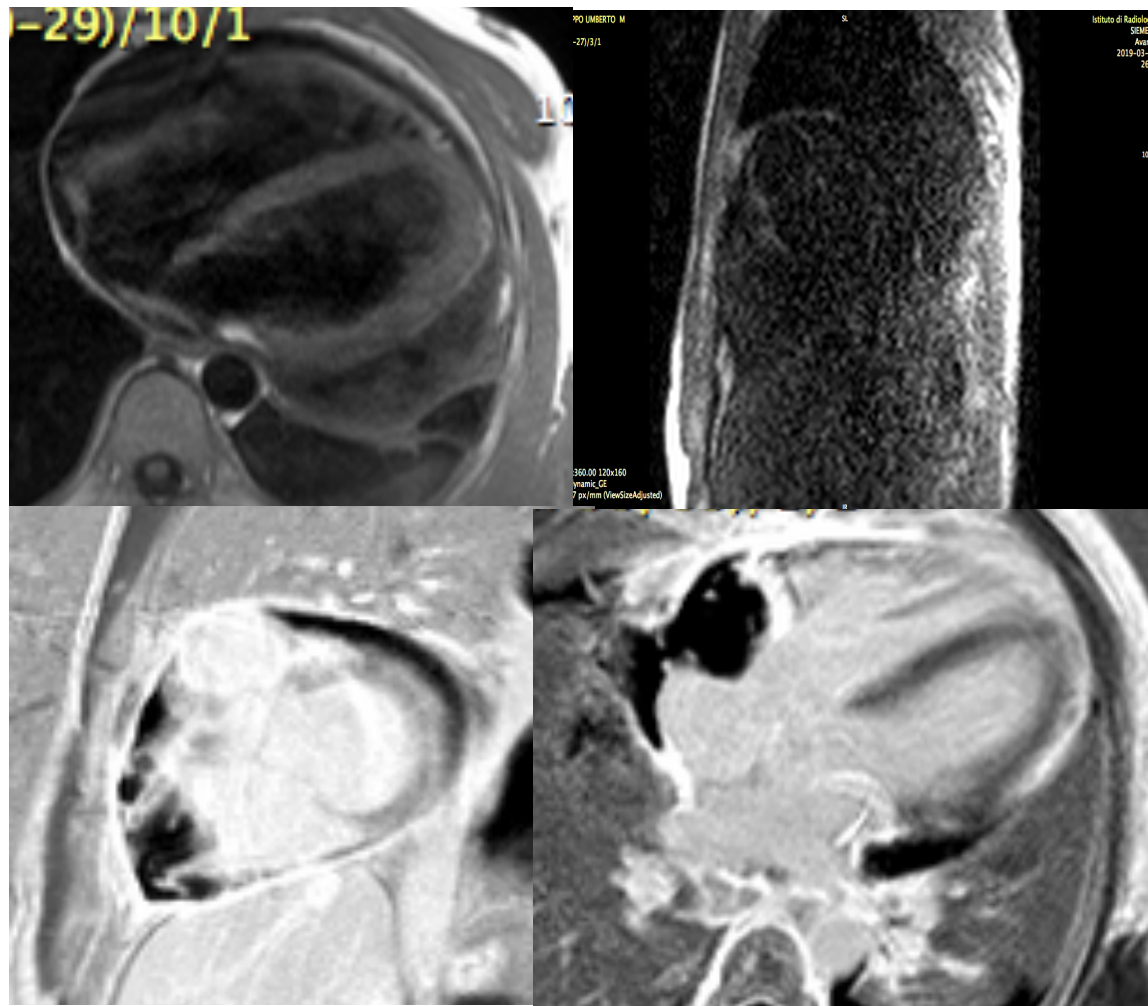
“Foglietti pericardici disomogeneamente ispessiti presentano grossolani noduli solidi in sede inter-aorto-cavale superiore, a ridosso del tetto atriale sinistro, in sede periostiale tra le vene polmonari di sinistra; altra massa di circa 55 x 35 mm, risulta adesa al pericardio viscerale ed infiltra le pareti superiore ed anteriore dell’ atrio destro con una componente aggettante in cavità . ”

Clinical case: angiosarcoma



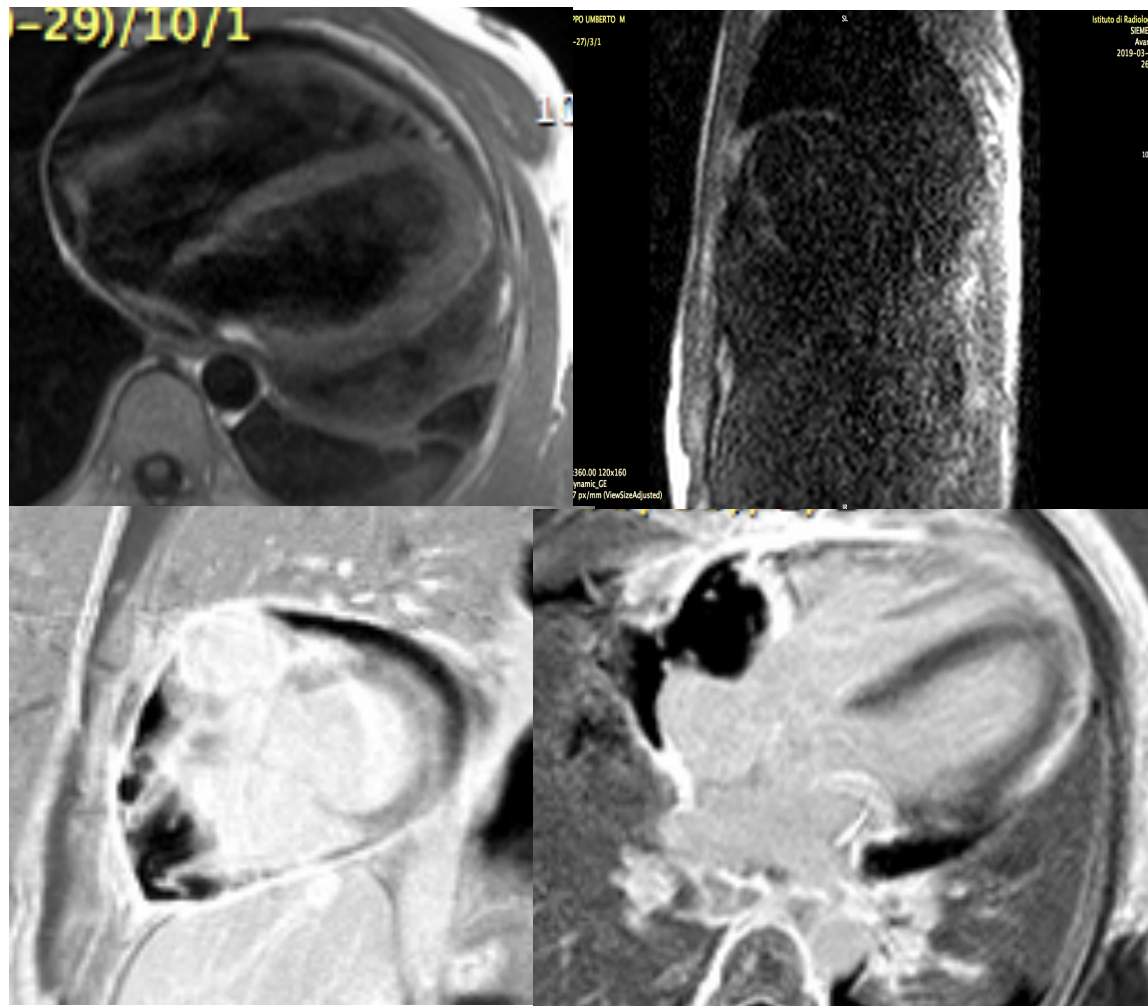
“Foglietti pericardici disomogeneamente ispessiti presentano grossolani noduli solidi in sede inter-aorto-cavale superiore, a ridosso del tetto atriale sinistro, in sede periostiale tra le vene polmonari di sinistra; altra massa di circa 55 x 35 mm, risulta adesa al pericardio viscerale ed infiltra le pareti superiore ed anteriore dell’ atrio destro con una componente aggettante in cavità . ”

Clinical case: angiosarcoma



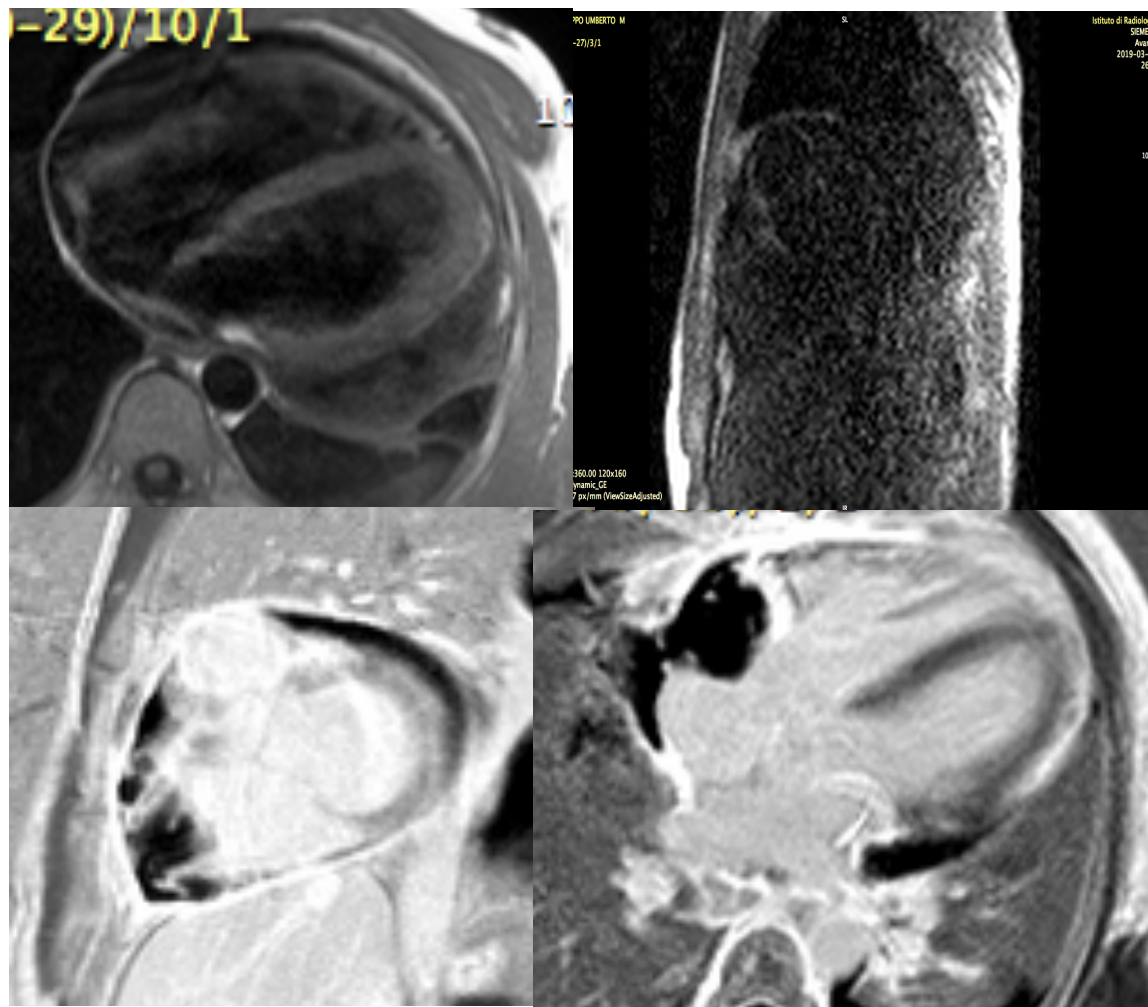
“Iperintensa nelle sequenze bilanciate; disomogeneamente iperintensa nelle sequenze T1w; dopo somministrazione di mdc nelle fasi precoci (first pass) enhancement periferico con componente ipointensa centrale; con T1 lungo ipointensa e attraversata da strutture vascolari di piccolo calibro; in fase tardiva non ulteriore enhancement centrale; enhancement post contrastografico dei foglietti pericardici. Conclusione: lesioni pericardiche a contenuto emorragico-necrotico, la maggiore con infiltrazione parietale dell’ atrio destro, in prima ipotesi di tipo ripetitivo.”

Clinical case: angiosarcoma



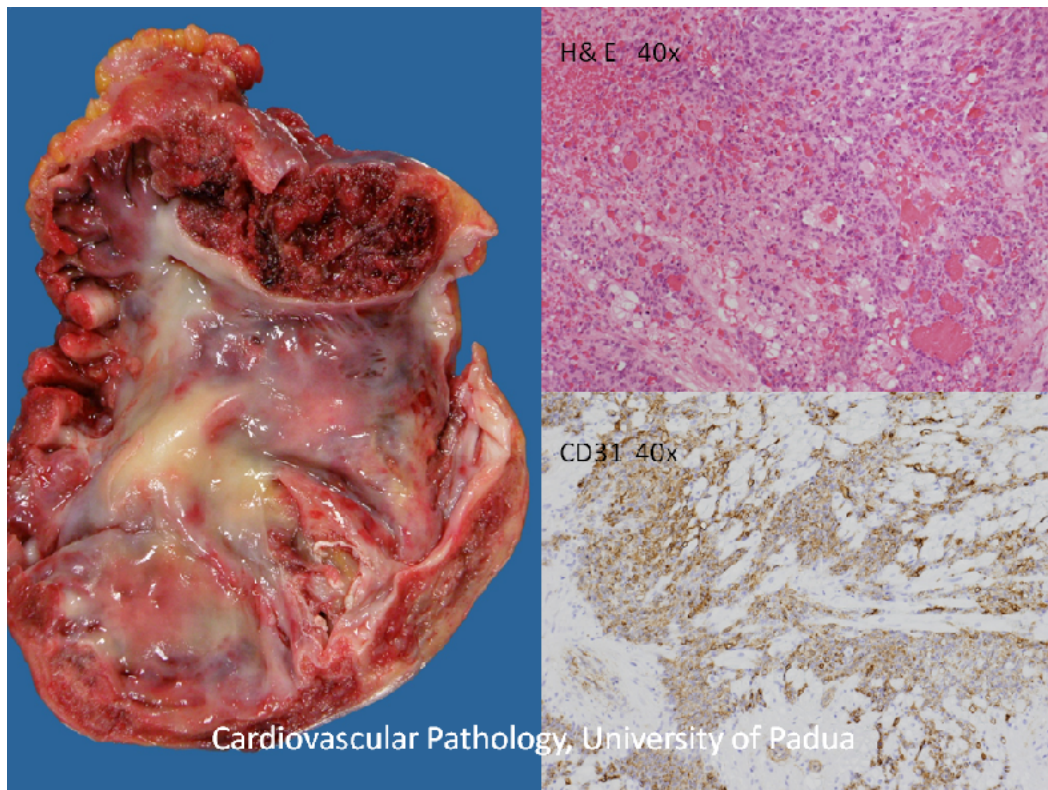
“Iperintensa nelle sequenze bilanciate; disomogeneamente iperintensa nelle sequenze T1w; dopo somministrazione di mdc nelle fasi precoci (first pass) enhancement periferico con componente ipointensa centrale; con T1 lungo ipointensa e attraversata da strutture vascolari di piccolo calibro; in fase tardiva non ulteriore enhancement centrale; enhancement post contrastografico dei foglietti pericardici. Conclusione: lesioni pericardiche a contenuto emorragico-necrotico, la maggiore con infiltrazione parietale dell’ atrio destro, in prima ipotesi di tipo ripetitivo.”

Clinical case: angiosarcoma



“Iperintensa nelle sequenze bilanciate; disomogeneamente iperintensa nelle sequenze T1w; dopo somministrazione di mdc nelle fasi precoci (first pass) enhancement periferico con componente ipointensa centrale; con T1 lungo ipointensa e attraversata da strutture vascolari di piccolo calibro; in fase tardiva non ulteriore enhancement centrale; enhancement post contrastografico dei foglietti pericardici. Conclusione: lesioni pericardiche a contenuto emorragico-necrotico, la maggiore con infiltrazione parietale dell’ atrio destro, in prima ipotesi di tipo ripetitivo.”

Clinical case: angiosarcoma



“Biopsia: neoplasia maligna scarsamente differenziata a prevalente pattern solido con occasionale presenza di spazi pseudovascolari ed ampi focolai di necrosi... angiosarcoma di alto grado... “



Key Points

1. **Cardiac metastatic lesions are up to 1000 times more common than primary tumours**
2. **Common sources of metastatic lesions**
 - Melanoma, thyroid cancer, breast cancer, renal carcinoma, soft tissue carcinoma, lung cancer, esophageal cancer, hepatocellular carcinoma
3. **Common benign primary tumours (70%)**
 - Myxoma, lipoma, fibroelastoma, fibroma, rhabdomyoma, hemangioma
4. **Common malignant primary tumours (30%)**
 - Angiosarcoma, rhabdomyosarcoma, mesothelioma, fibrosarcoma, lymphoma
5. **Typical tumour locations*:**
 - **Any chamber:** Lipoma (intramural / intracavitary), Hemangioma (intracavitary), Rhabdomyosarcoma (intramural, metastases).
 - **Ventricles:** Fibroma (intramural), Rhybdomyoma (intramural).
 - **Valvular:** Fibroelastoma, Vegetations.
 - **Left Atrium:** Thrombus, Myxoma, Fibrosarcoma, Osteosarcoma, Leiomyosarcoma (posterior wall), undifferentiated sarcoma.
 - **Right Atrium:** Angiosarcoma, Lymphoma.
 - **Pericardium:** Pericardial cyst, metastases.
6. Consider **pseudo tumours:**
 - Normal heart structures, thrombus, cyst or vegetation

* Note, that the location of the various conditions can vary and many cardiac tumours can occur in any chamber



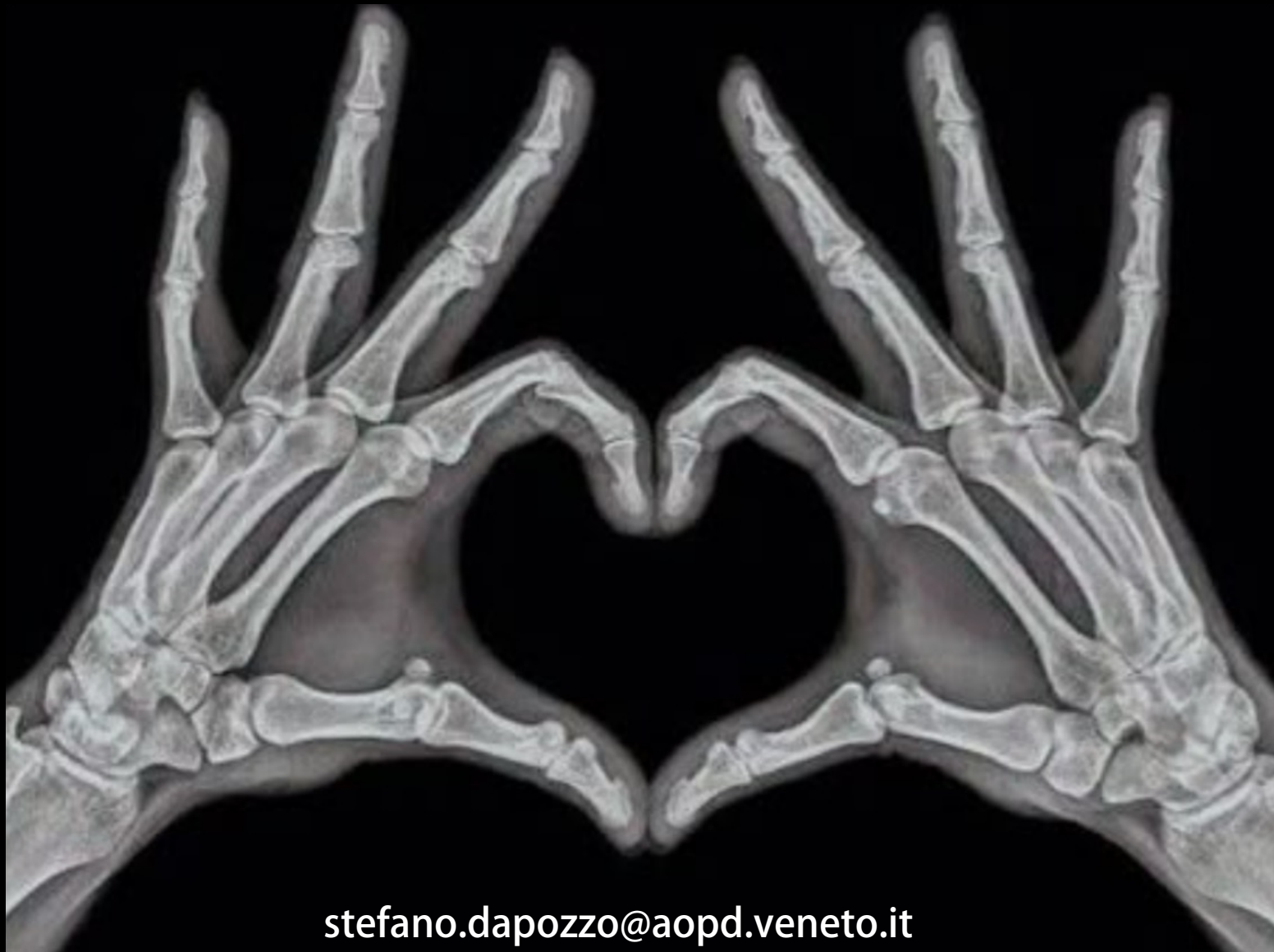Table 6 Indications for CMR of cardiac masses

Indication	Class
1. Suspected cardiac mass	I
2. Differentiation between benign, malignant and non-tumourous masses	I
3. Guide surgery and/or biopsy if this is deemed appropriate	I
4. Follow-up of benign cardiac tumours that do not require urgent intervention for changes over time	I
5. Evaluation of tumour resection/debulking, monitoring recurrence after surgery and regression or progression after chemotherapy or radiotherapy	I
6. Extra-cardiac extension of cardiac tumours or cardiac extension of tumours originating from surrounding structures	I
7. Impact of cardiac masses on hemodynamics	I



- ✓ Tissue characterization and mass localization
- ✓ Non classical anatomical planes of study
- ✓ Benign vs Malignant
- ✓ What information should I write in a report?

GRAZIE PER L'ATTENZIONE



stefano.dapozzo@aopd.veneto.it