UNIVERSITÀ
DEGLI STUDI
DI PADOVA

1222 · 2022
800 ANNI

UNIVERSITÀ DEGLI STUDI DI PADOVA

Acquisizione delle sequenze in risonanza magnetica cardiaca
Parte 2

Anna Baritussio, MD, PhD, FEACVI

A “one stop shop” technique

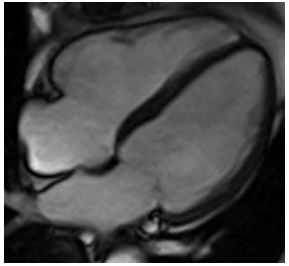

BIVENTRICULAR
VOLUMES AND FUNCTION

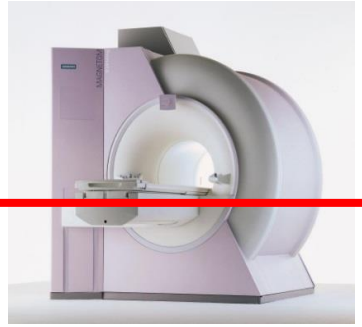

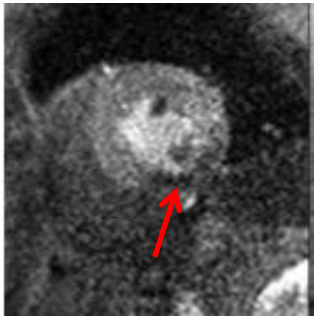

INDUCIBLE ISCHEMIA

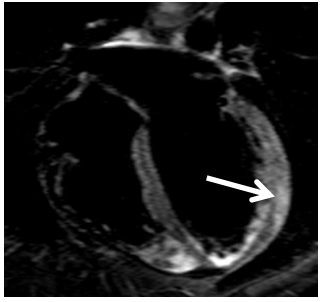

MYOCARDIAL OEDEMA

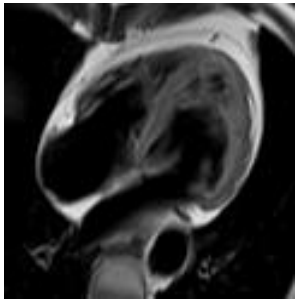

T1-WEIGHTING

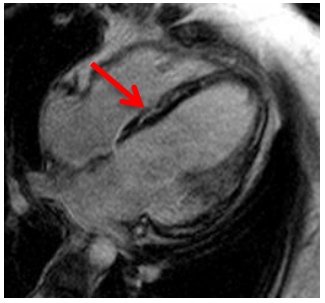

LATE ENHANCEMENT

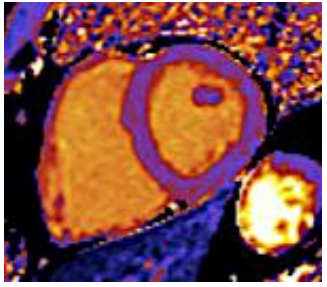

T1/T2 MAPPING

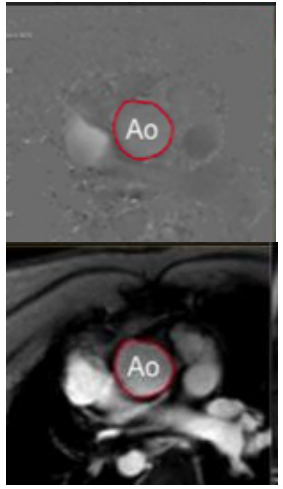

VALVE ASSESSMENT

TISSUE CHARACTERIZATION

Università degli Studi di Padova

Kramer *et al. Journal of Cardiovascular Magnetic Resonance* (2020) 22:17
https://doi.org/10.1186/s12968-020-00607-1

Journal of Cardiovascular Magnetic Resonance

RESEARCH Open Access

Standardized cardiovascular magnetic resonance imaging (CMR) protocols: 2020 update

Christopher M. Kramer[1*], Jörg Barkhausen[2], Chiara Bucciarelli-Ducci[3], Scott D. Flamm[4], Raymond J. Kim[5] and Eike Nagel[6]

Schulz-Menger *et al. Journal of Cardiovascular Magnetic Resonance* (2020) 22:19
https://doi.org/10.1186/s12968-020-00610-6

POSITION STATEMENT Open Access

Standardized image interpretation and post-processing in cardiovascular magnetic resonance - 2020 update

Society for Cardiovascular Magnetic Resonance (SCMR): Board of Trustees Task Force on Standardized Post-Processing

Jeanette Schulz-Menger[1*], David A. Bluemke[2], Jens Bremerich[3], Scott D. Flamm[4], Mark A. Fogel[5], Matthias G. Friedrich[6], Raymond J. Kim[7], Florian von Knobelsdorff-Brenkenhoff[8], Christopher M. Kramer[9], Dudley J. Pennell[10], Sven Plein[11] and Eike Nagel[12]

Imaging Oedema

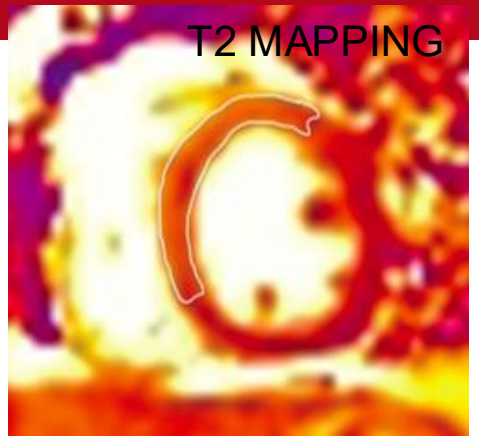

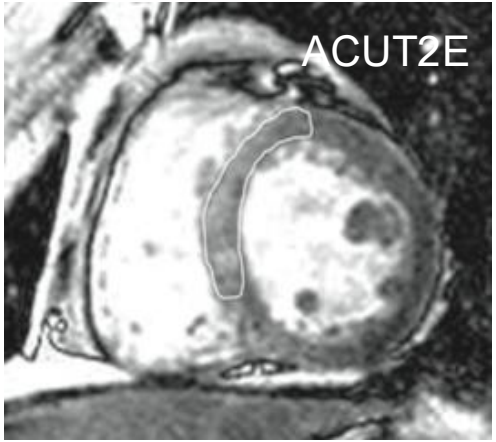

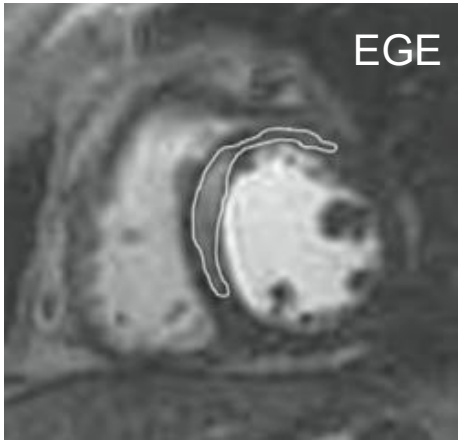

McAlindon EJ et al. Radiology 2015; 271: 61-70

T2-weighted Images

- Before contrast administration
- To assess presence of myocardial and pericardial edema
- Dark blood T2w TSE
- Slice ≥10 mm for the best SNR

EDEMA = HYPER-INTENSE

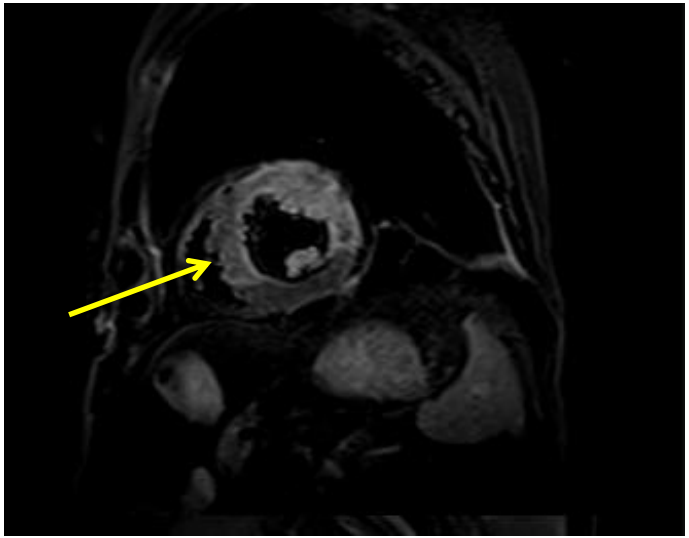

T2-weighted Images

ISCHEMIC PATTERN

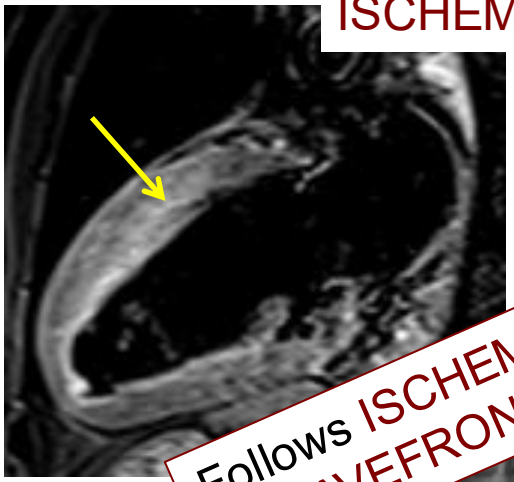

Follows ISCHEMIC WAVEFRONT

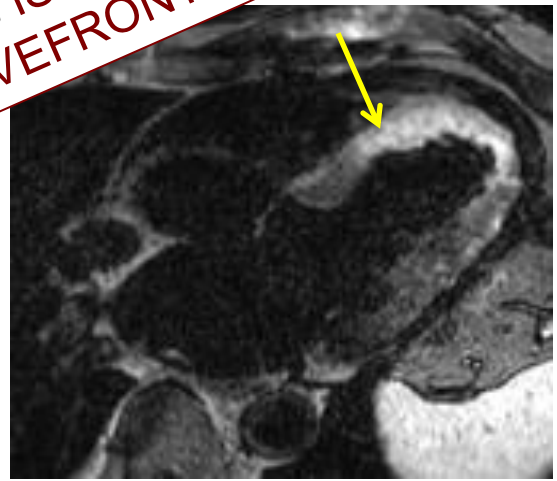

NON ISCHEMIC PATTERN

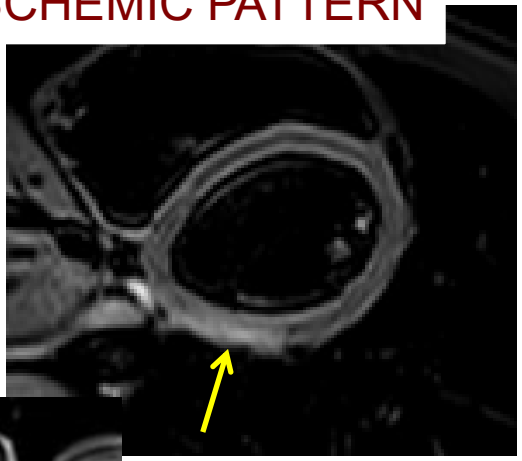

T2-weighted Images

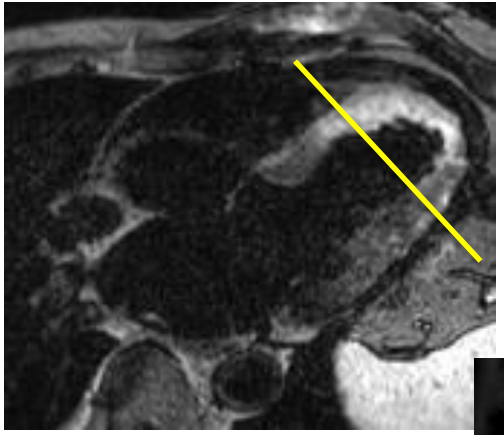

High SI
Two orthogonal views

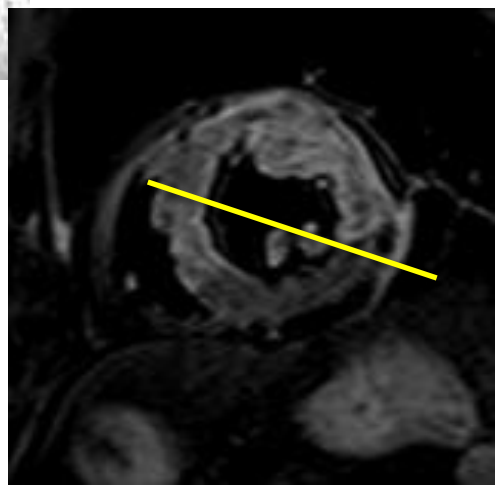

PITFALLS

- Low SI artefacts
  - arrhythmia/through-plane motion → false low SI
- High SI artefacts
  - slow flowing blood, insufficient flow suppression

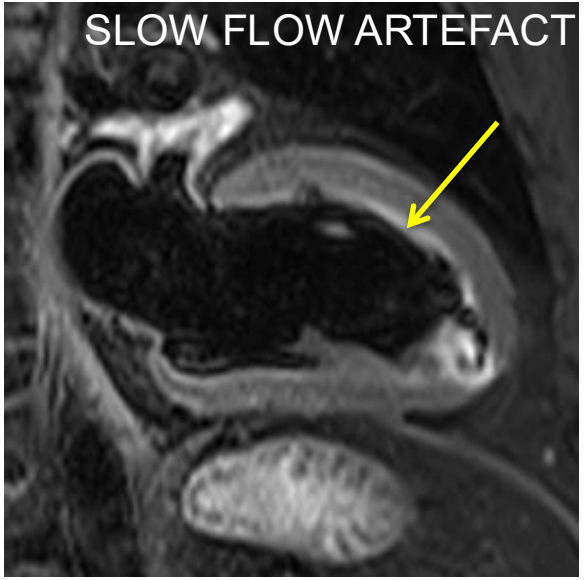

T2-weighted Images

SI Ratio Myocardium/Skeletal Muscle ≥2

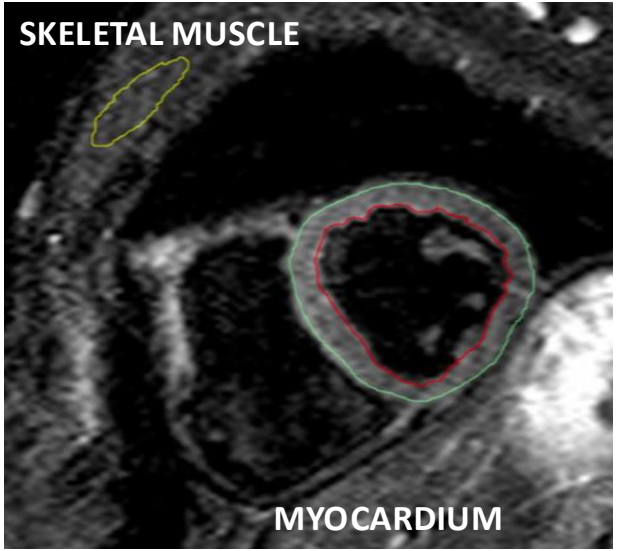

While a cut-off of 1.9 can be used for dark blood triple-inversion recovery spin echo [67], a locally established value is recommended, because SI and ratio values may vary between sequence settings (especially echo time (TE)) and CMR scanner models. For these images, a

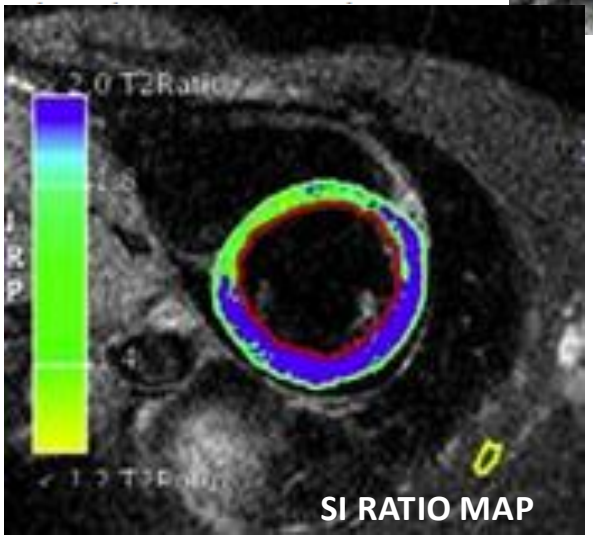

Schulz-Menger J et al. JCMR 2020; 22: 19

T2-weighted Images

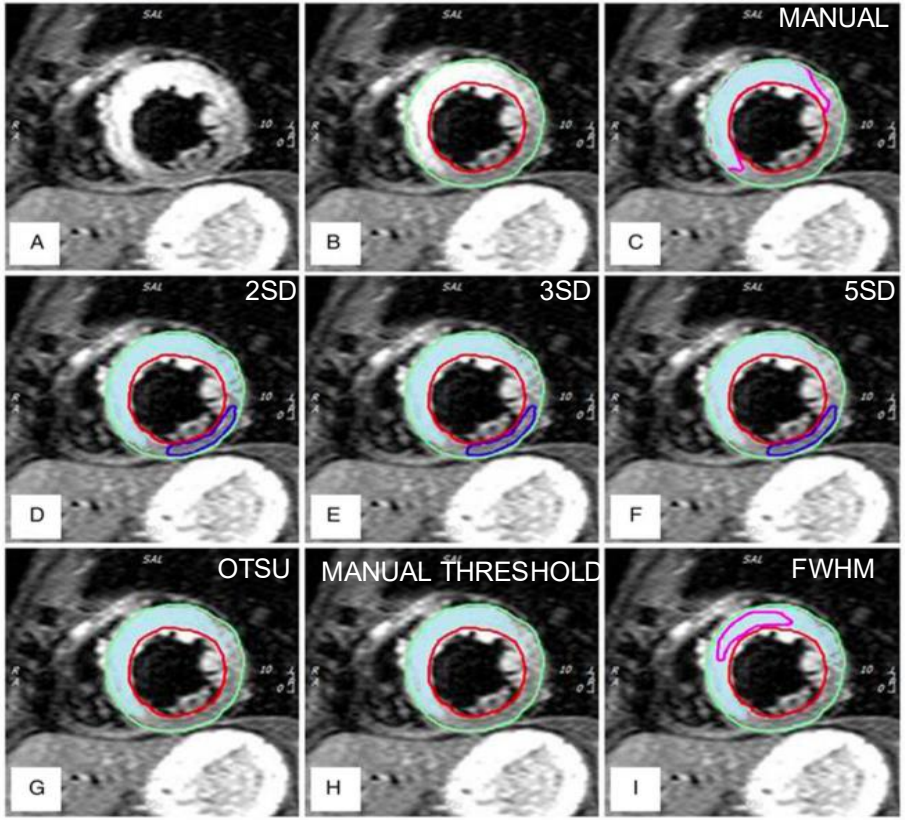

McAlindon EJ et al. EHJ Cardiovascular Imaging 2015; 16: 738–746

T2-weighted Images

PERICARDIAL OEDEMA

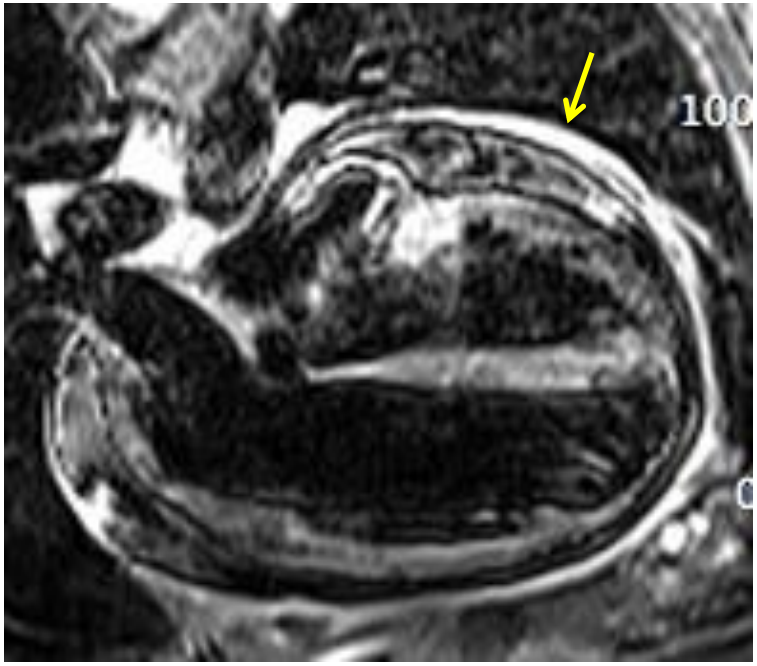

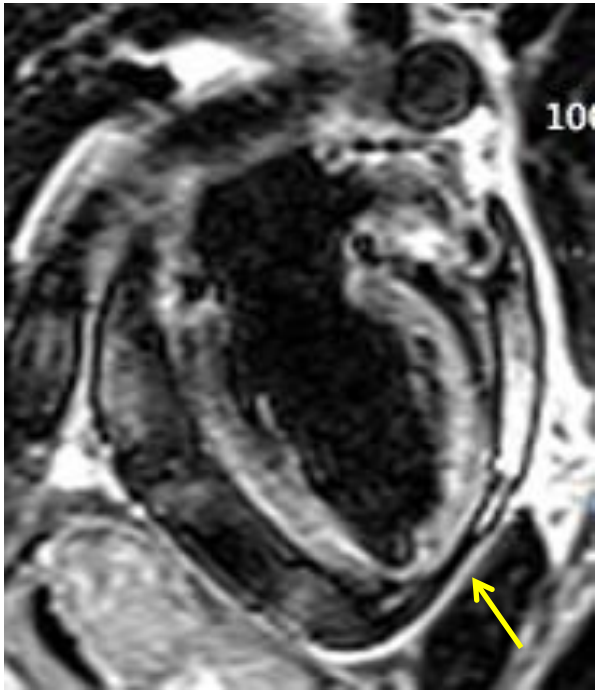

T2*-weighted Images

"Black blood" Gradient Echo (GRE), multi-echo
Mid-ventricular slice → ROI on interventricular septum
Transaxial slice on liver → avoid vessels when measuring

✓ Heart and liver iron overload

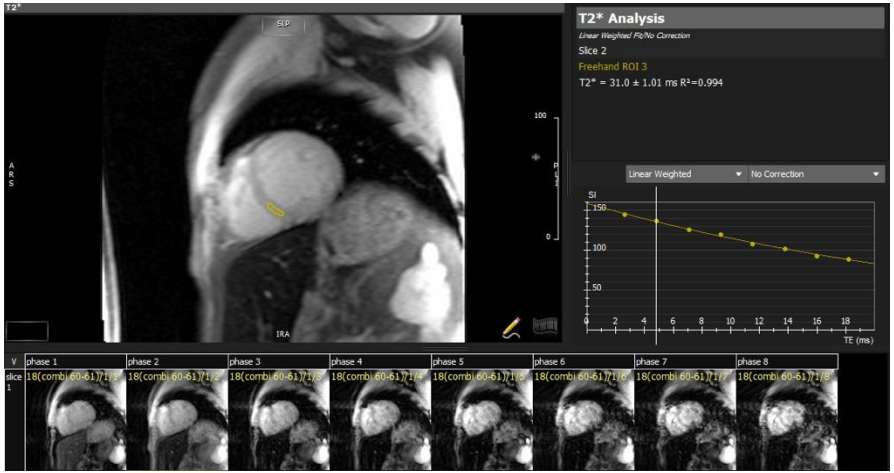

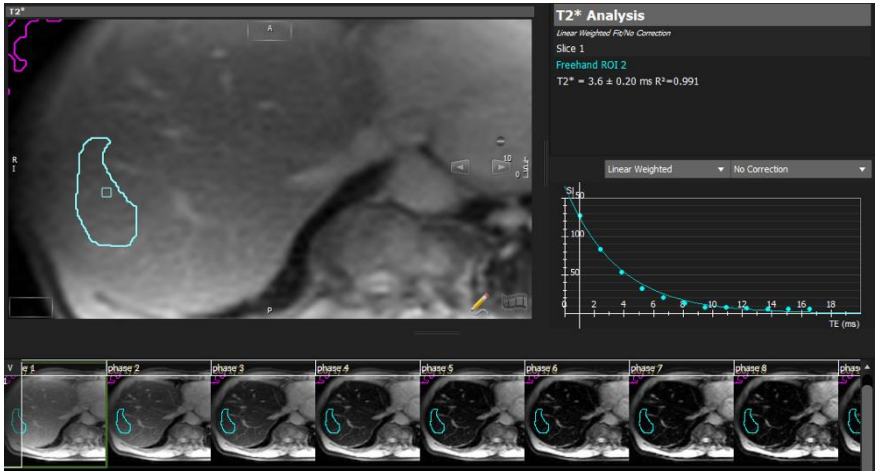

T2*-weighted Images

Myocardial T2*(ms)	Myocardial R2* (Hz)	Dry weight (MIC) (mg/g)	Hepatic T2* (ms)	Hepatic R2* (Hz)	Dry weight (LIC) (mg/g)	Classification
≥20	≤ 50	≤ 1.16	≥15.4	≤ 65	≤ 2	**None**
14-20	50 – 71	1.16 – 1.8	4.5-15.4	65 - 224	2-7	**Mild**
10-14	71 – 100	1.8 – 2.7	2.1 – 4.5	224 - 475	7-15	**Moderate**
≤10	≥ 100	≥ 2.7	≤2.1	≥ 475	≥ 15	**Severe**

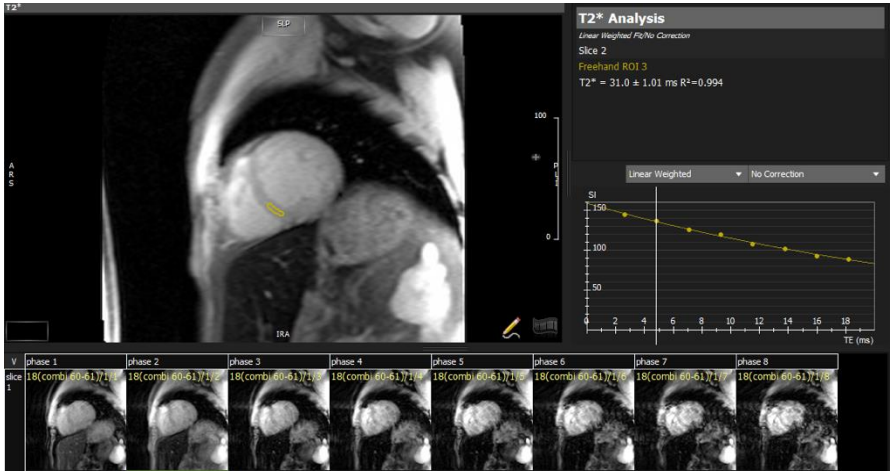

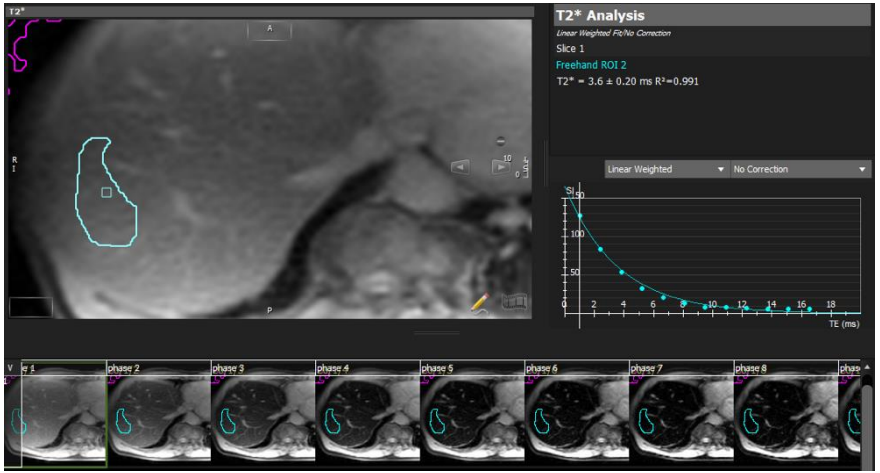

T1-weighted Images

Turbo Spin Echo (TSE) with/without fat saturation

✓ Anatomy

N.B. low signal of adjacent lung and paucity of surrounding fat, may hamper the pericardial visualization over the LV free wall

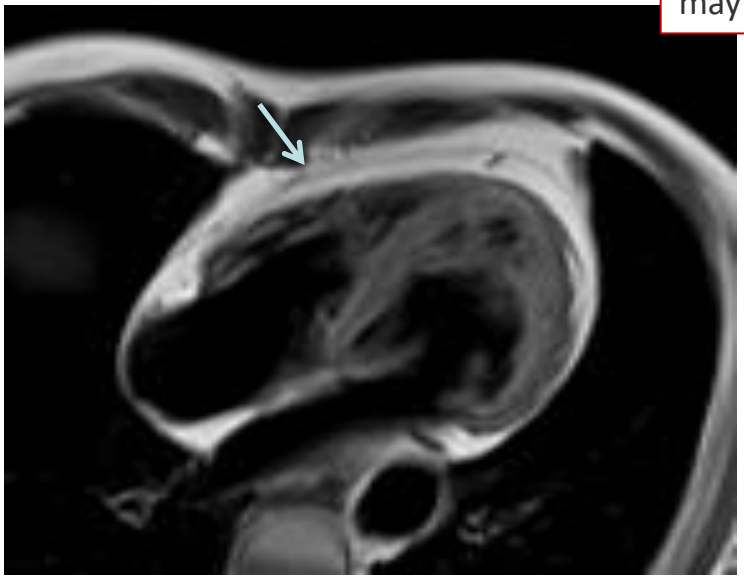

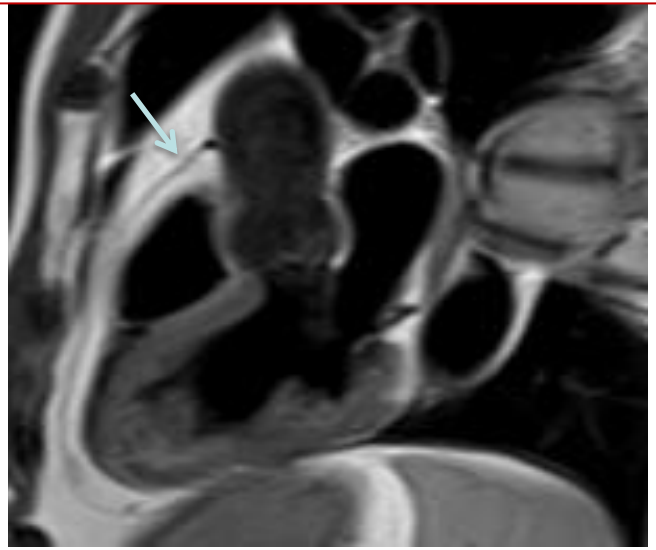

NORMAL PERICARDIUM

T1-weighted Images

Turbo Spin Echo (TSE) with/without fat saturation

✓ Anatomy

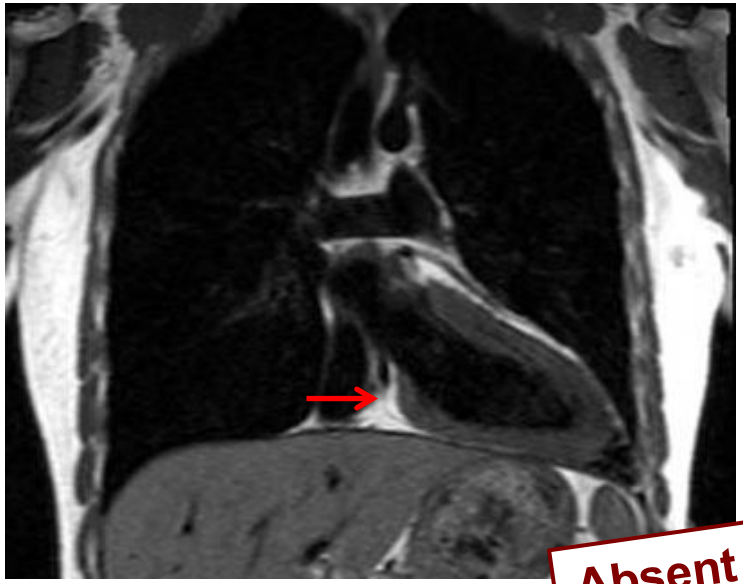

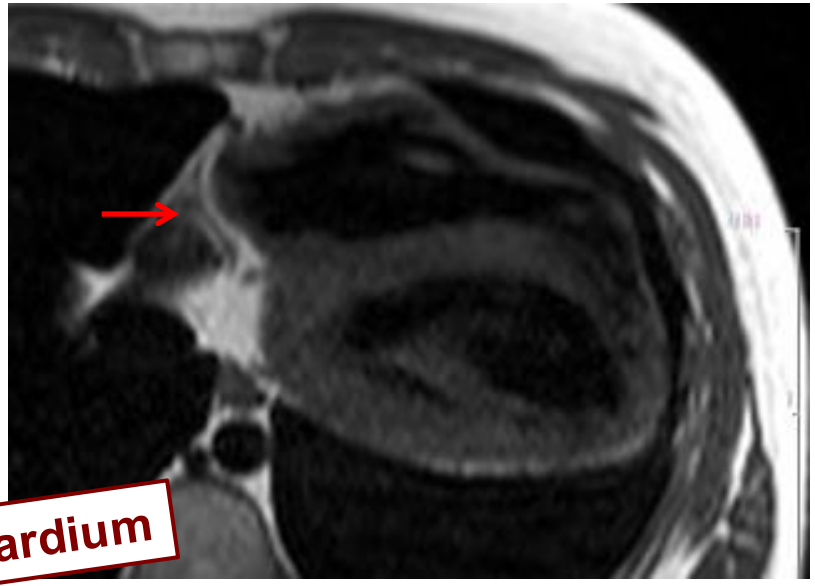

Absent pericardium

T1-weighted Images

Turbo Spin Echo (TSE) with/without fat saturation

- ✓ Anatomy
- ✓ Fat infiltration

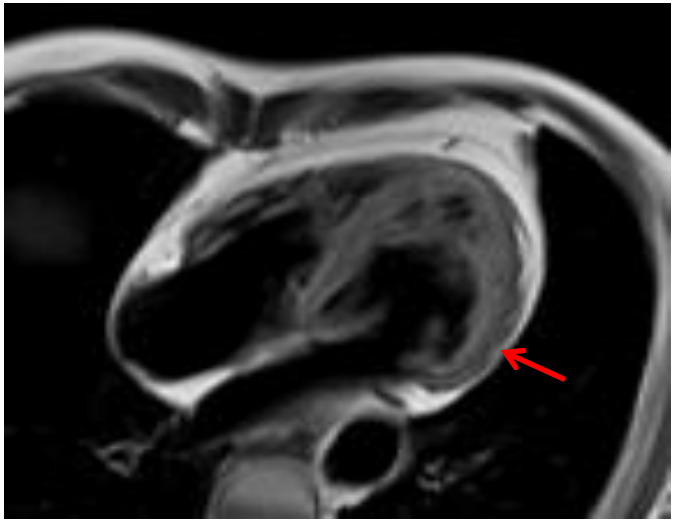

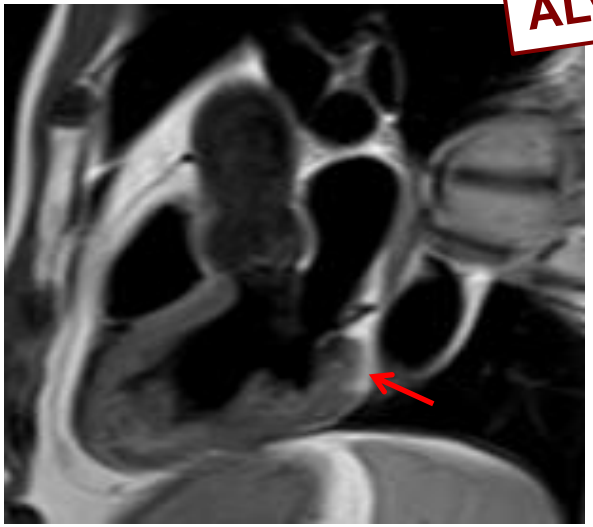

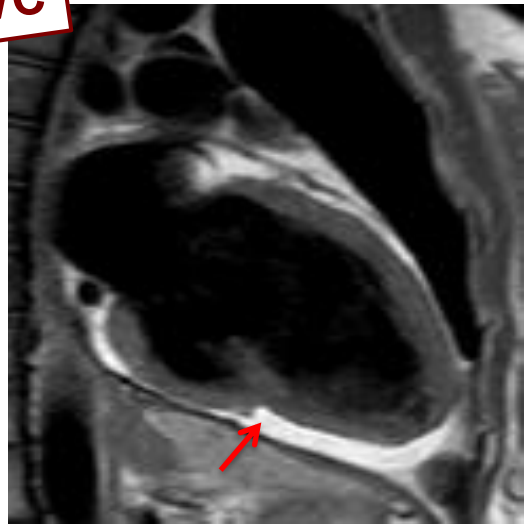

Perfusion

Saturation recovery GRE
Three short-axis slices, >40 heart beats
Contrast (0.05-0.1 mmol/Kg) followed by 30 ml saline bolus

✓ At rest or following pharmacologic stress → myocardial perfusion defect

Perfusion

Perfusion

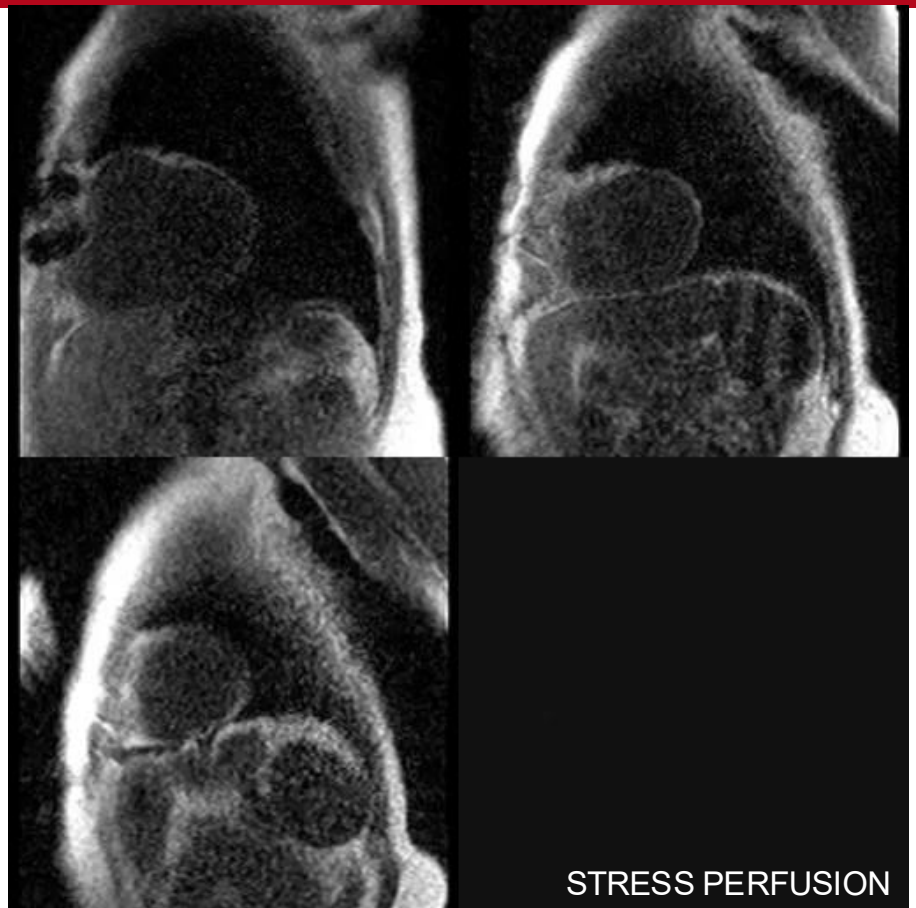

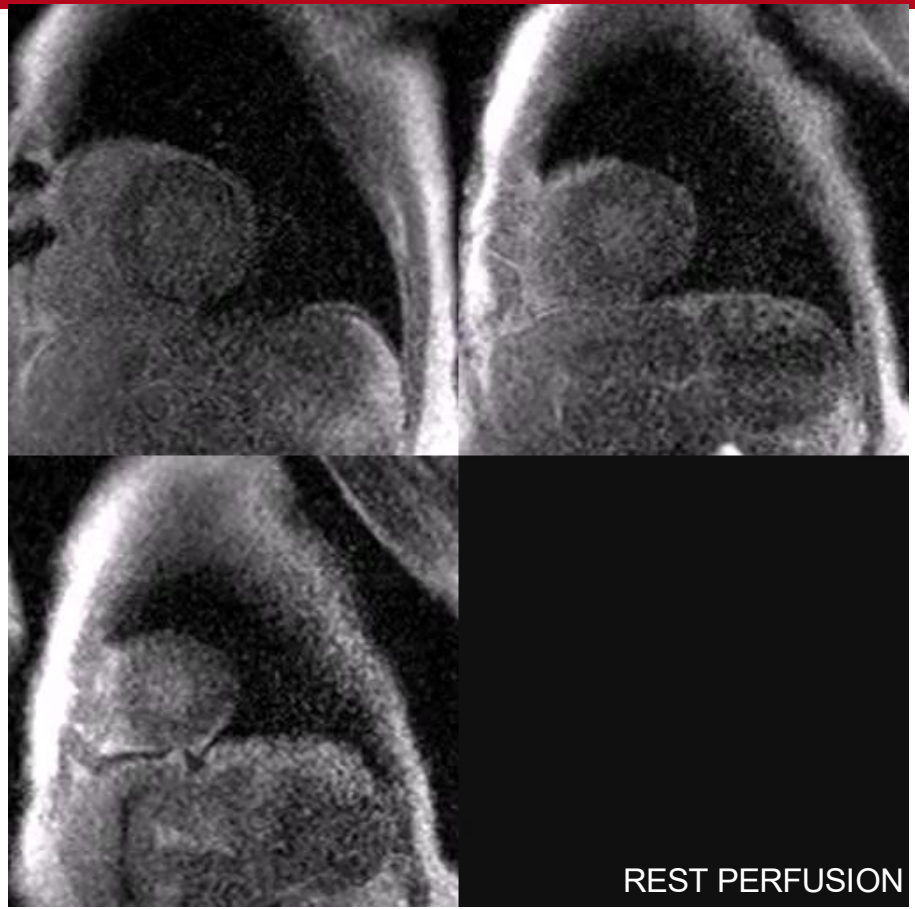

Perfusion

MBF in every territory >1.5 ml/g/min → no occlusive CAD

Quantification of myocardial blood flow requires knowledge of the amount of contrast agent In the myocardial tissue and the arterial input function (AIF)

driving the delivery of this contrast agent

“DUAL”-SEQUENCE FOR MULTI-SLICE 2D SATURATION RECOVERY

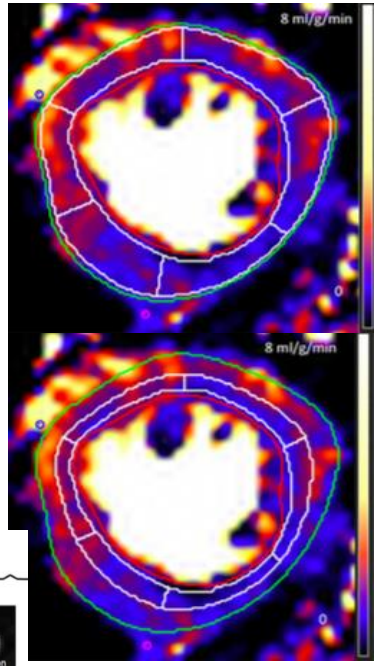

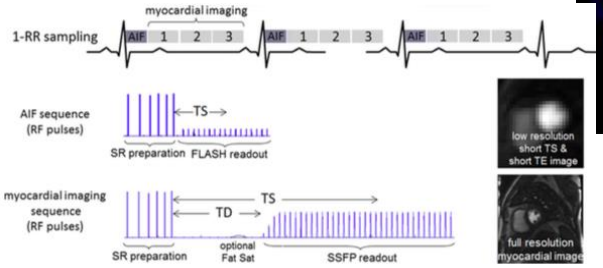

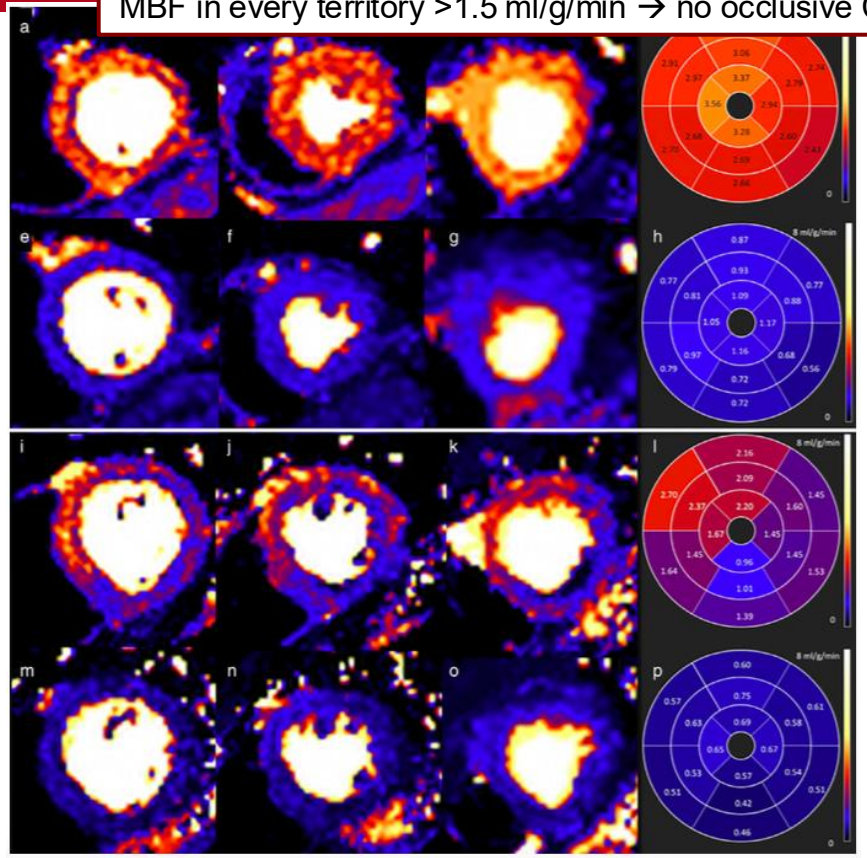

Kellman et al, JCMR 2017; 19:43

Knott et al, JCMR 2019; 50:756-62

Gadolinium Contrast Agents

Gadolinium

- Administered intravenously
- Extra-cellular distribution

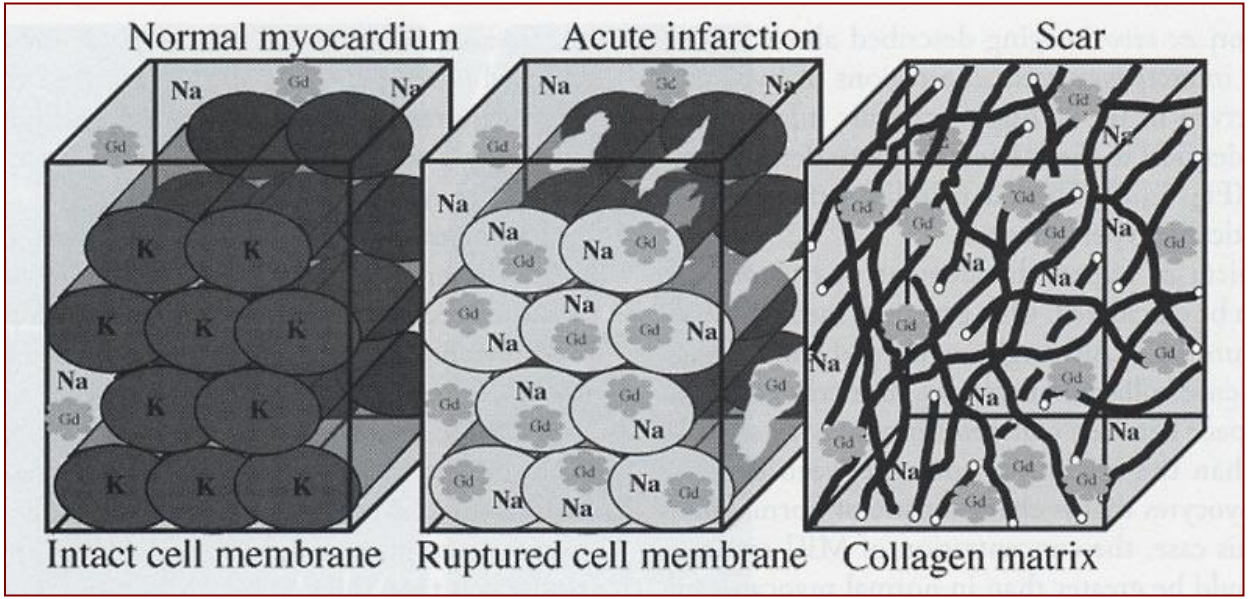

Kim RJ, Cardiovascular MRI and MRA, Higgins and de Roos ed. LWW 2003

Early Gadolinium Enhancement

Inversion recovery GRE
Acquired in mid-end diastole
1-3 min after Gad administration →"Early Enhancement"

- ✓ Hyperemia
- ✓ Thrombus (TI >400 msec)
- ✓ Infiltrative disease (amyloidosis)

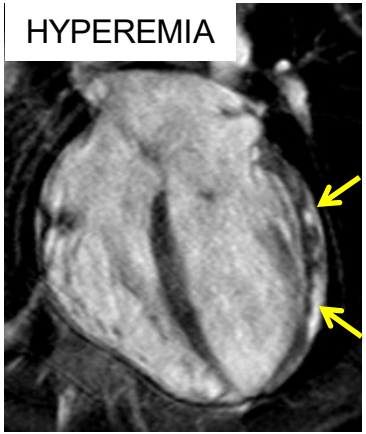

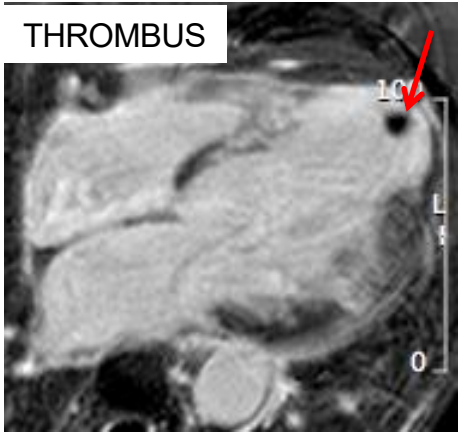

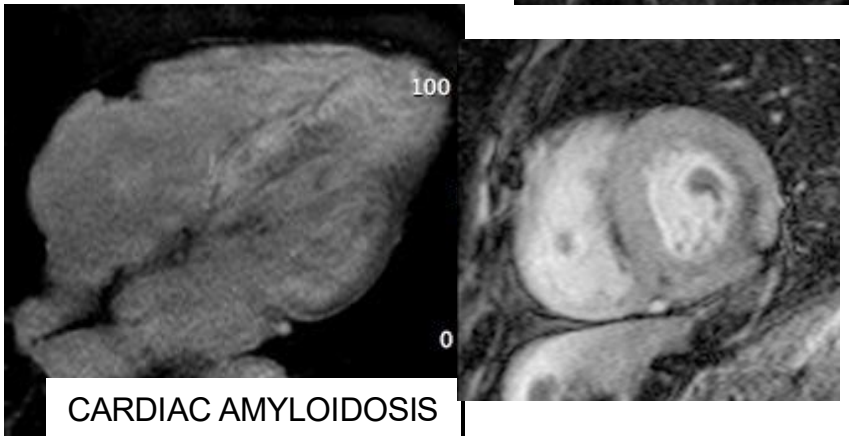

Late Gadolinium Enhancement

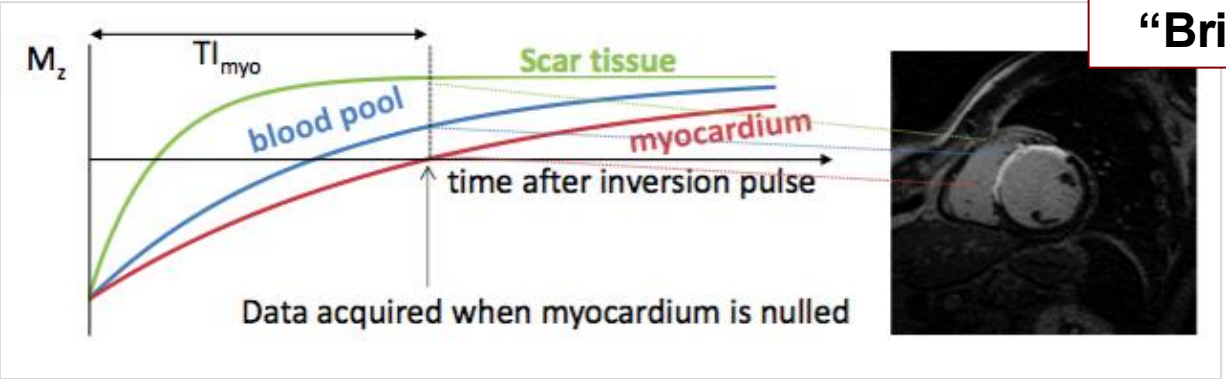

"Bright is bad"

10-15 min after Gad administration→ "Late Enhancement"
TI Scout/Look Locker
Increase TI by 10-15 ms every 2-3 min
TI difficile da identificare → amiloidosi?
Phase Swap – Cut through

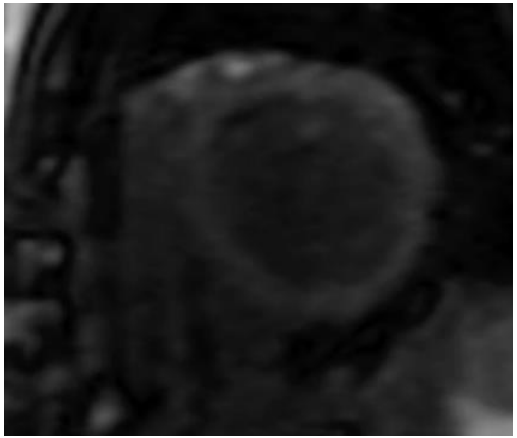

Broadbent D et al. ESC CMR Physics for Clinicians Pocket Guide v1.0.2015

Late Gadolinium Enhancement

BRIGHT IS BAD!!

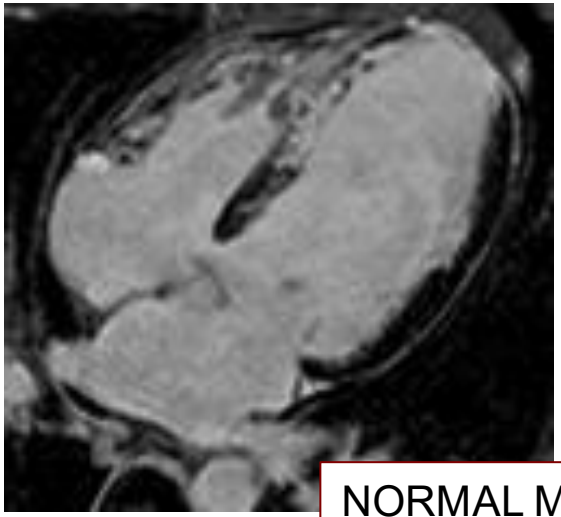

4C

NORMAL MYOCARDIUM IS BLACK

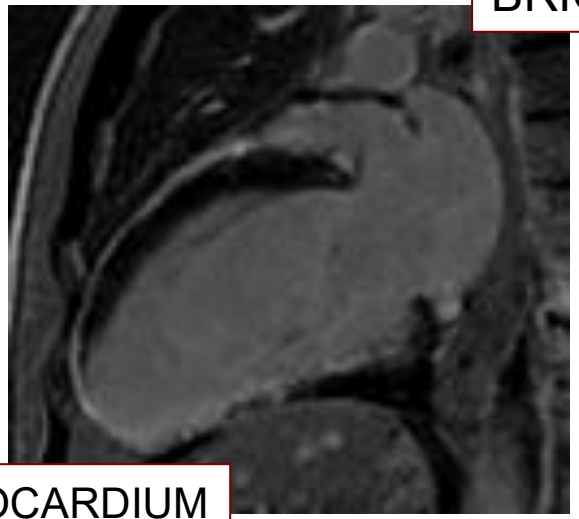

2C

3C

Late Gadolinium Enhancement

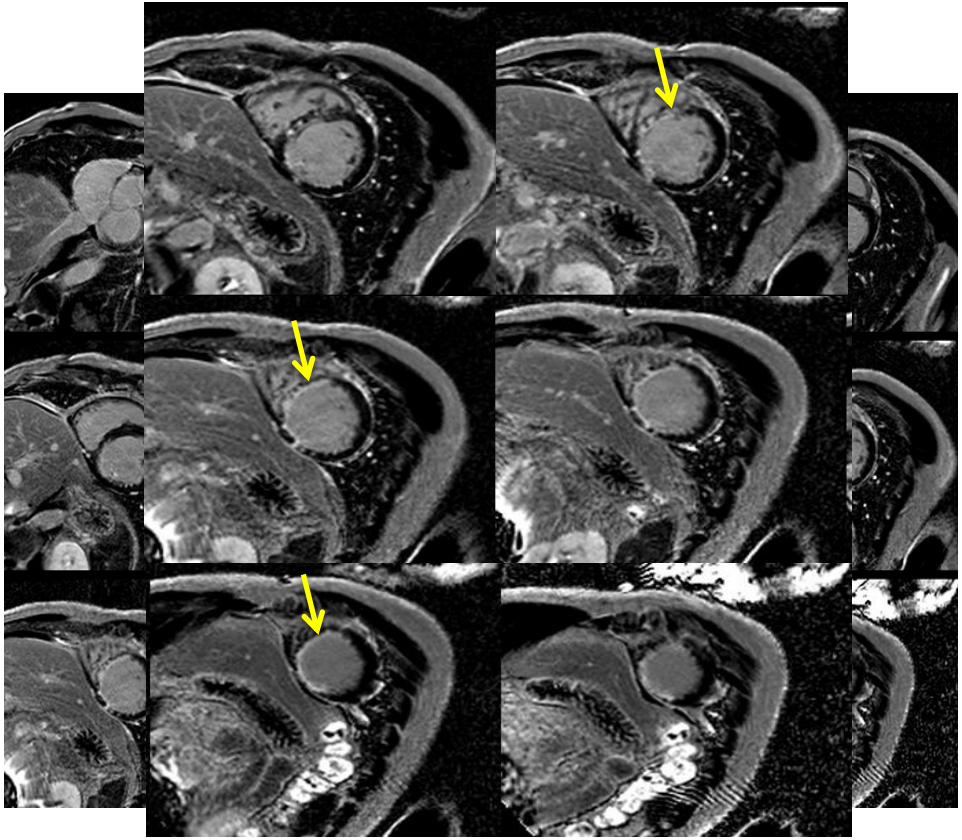

Late Gadolinium Enhancement

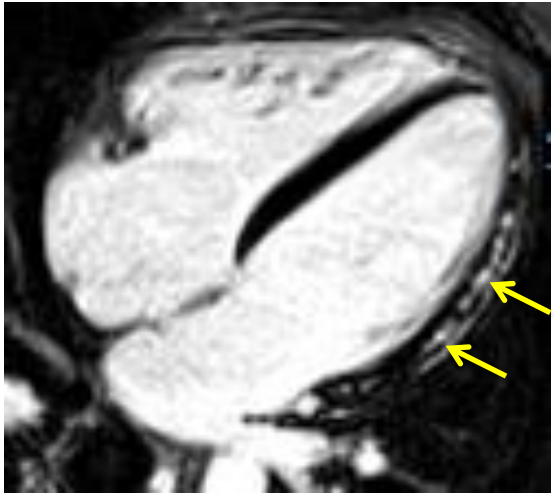

4C

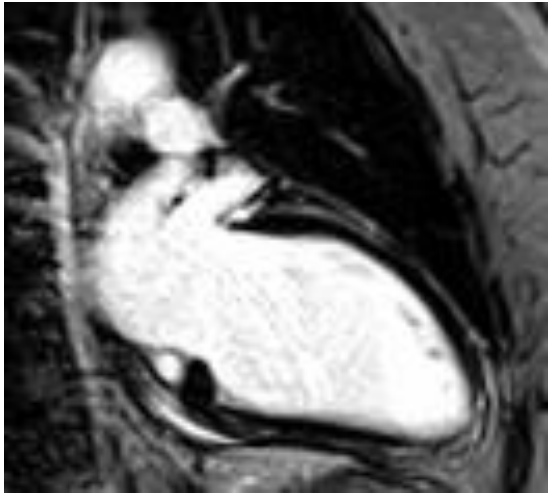

2C

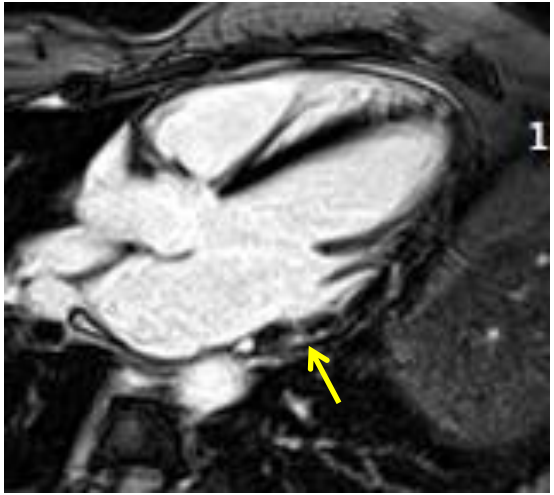

3C

Late Gadolinium Enhancement

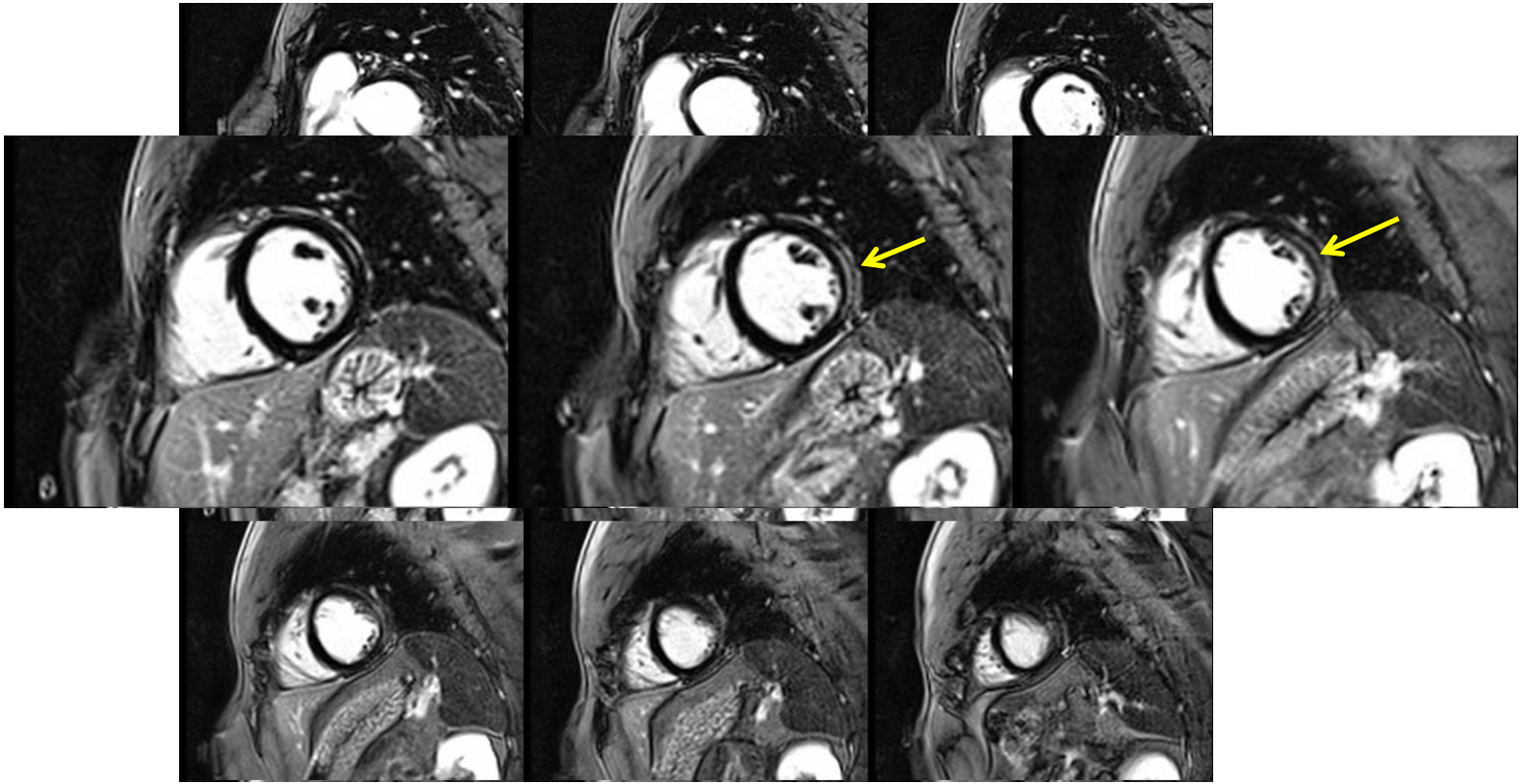

Late Gadolinium Enhancement

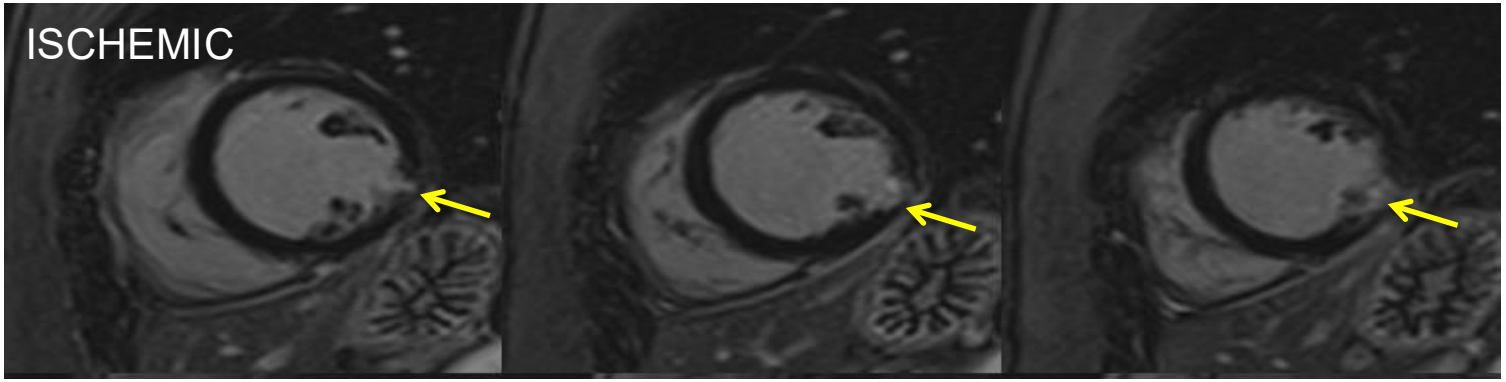

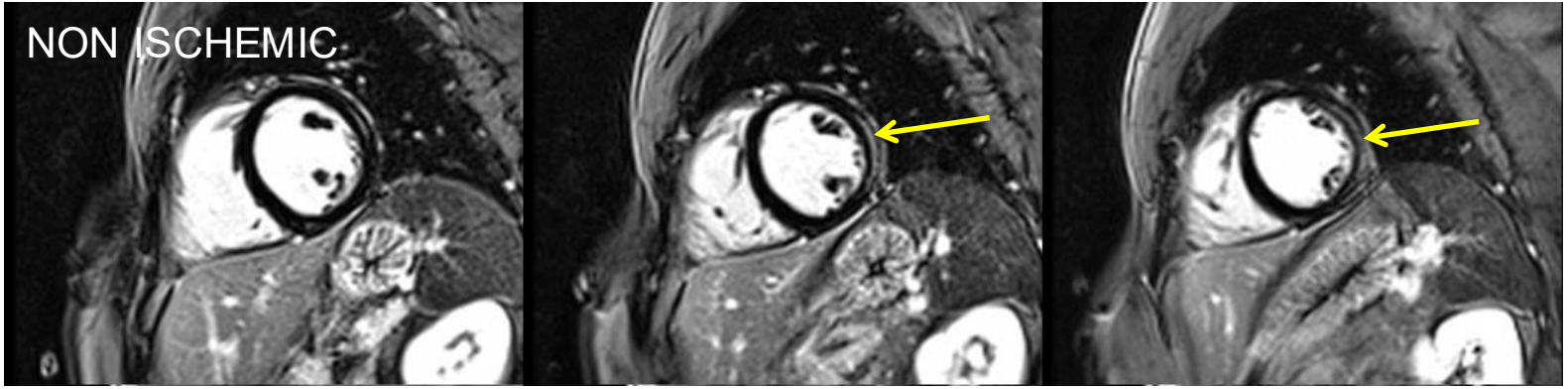

Late Gadolinium Enhancement

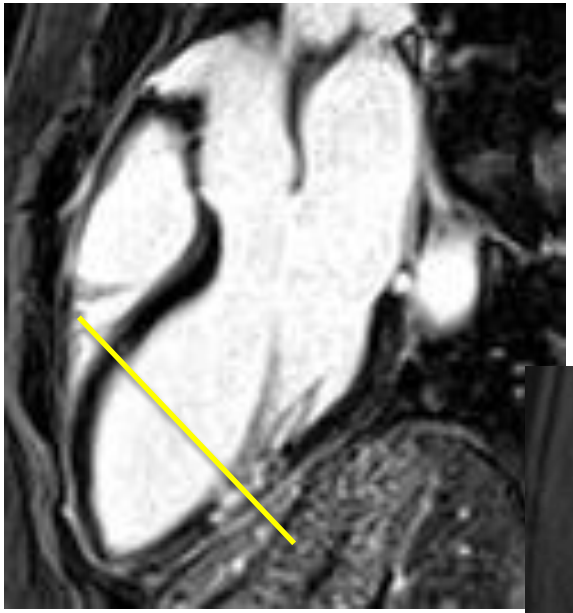

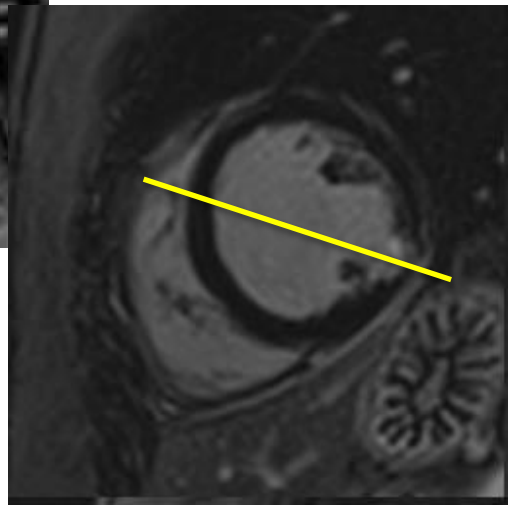

High SI
Two orthogonal views

PITFALLS

- Bright ghosting artefacts
  - poor ECG gating
  - poor breath-holding
  - long T1 species in the imaging plane (effusion)

Late Gadolinium Enhancement

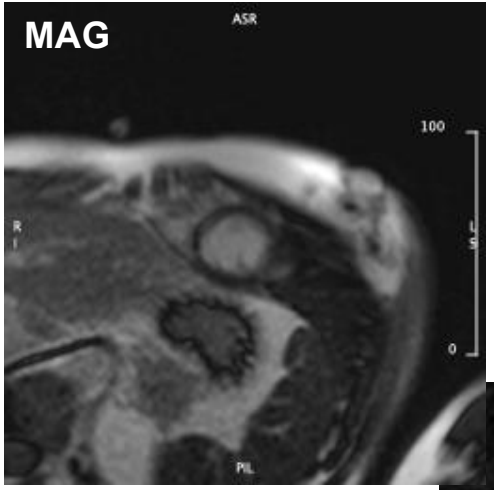

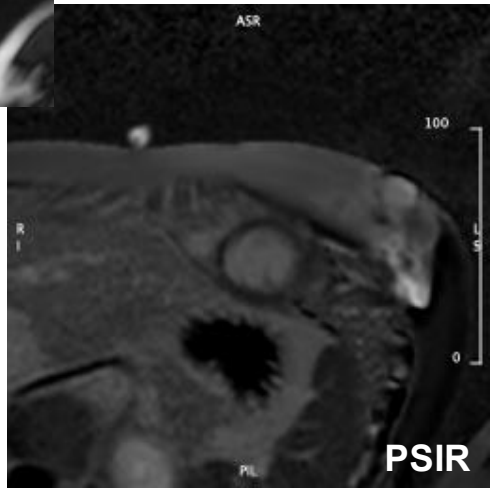

Late Gadolinium Enhancement

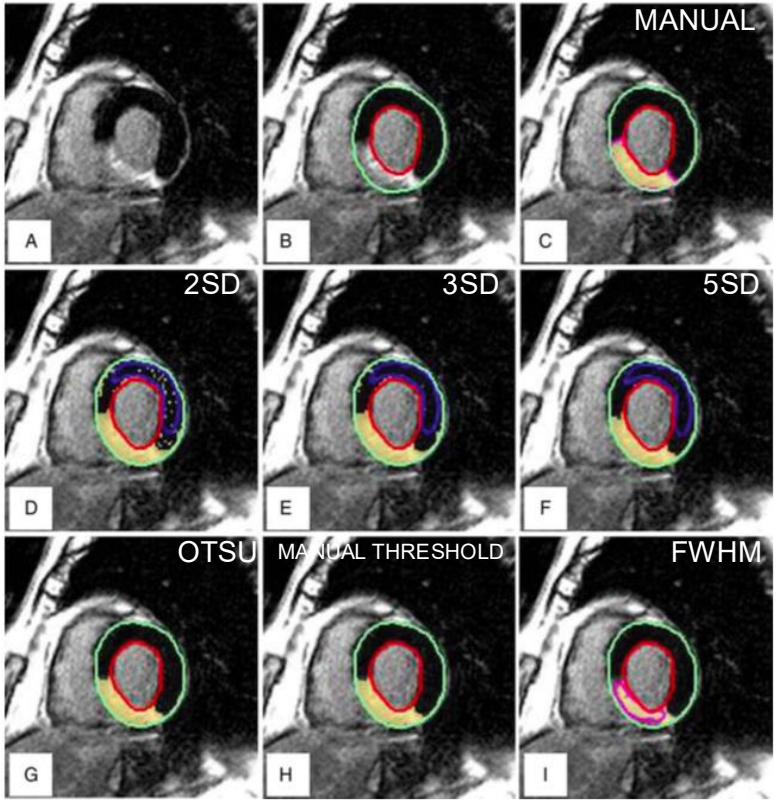

McAlindon EJ et al. EHJ Cardiovascular Imaging 2015; 16: 738–746

LGE – One size does not fit all

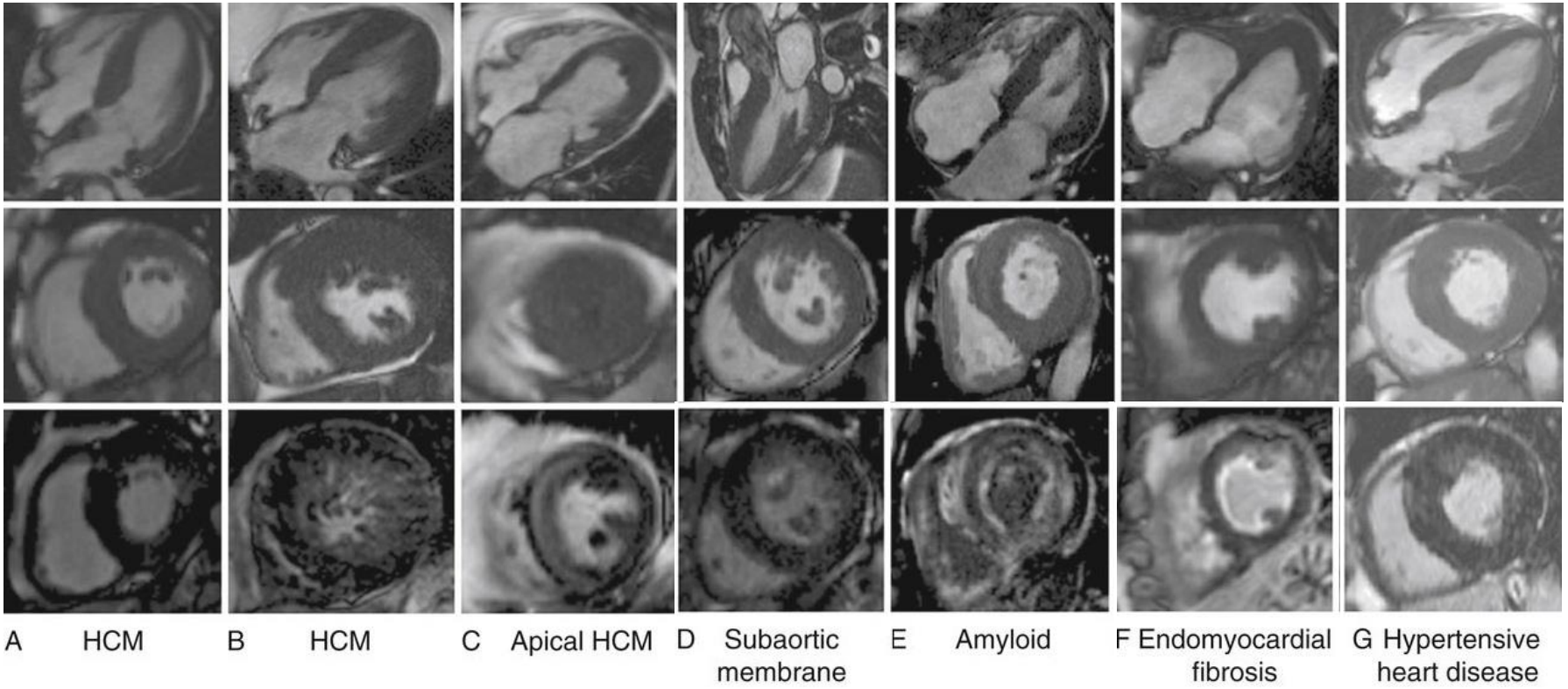

Gati S et al, JACC Imaging 2018; 11: 247-259

Parametric Mapping

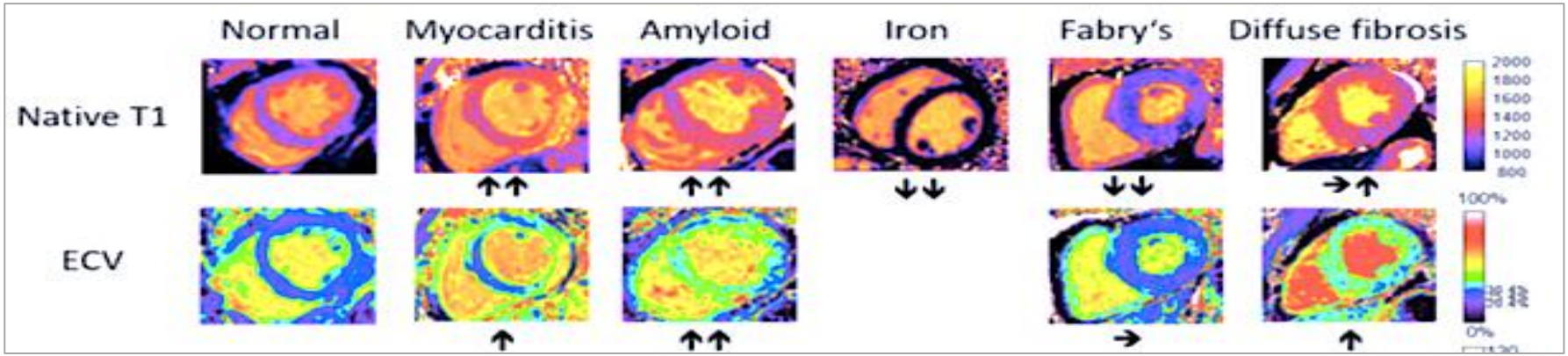

Herzog BA et al. EACVI ESC CMR Pocket Guide v2.0.2017

Parametric Mapping

1. T1 mapping
   a. Native T1 mapping is performed in the absence of contrast agents.
   b. Look Locker imaging (modified Look Locker Inversion recovery (MOLLI) or shortened MOLLI (ShMOLLI) or equivalent) should be used.
   c. Diastolic acquisition is best with the exception of atrial fibrillation in which systolic acquisition may be preferred. In patients with higher heart rates, specific sequences designed for these heart rates should be used.
   d. Source images should be checked for motion/ artifact and imaging repeated if this occurs.
   e. Slice thickness: 6–8 mm, in-plane resolution ~ 1.6–2.0 mm
   f. The number and orientation of slices obtained will depend upon the indication. At least one short-axis map should always be obtained.
   g. For extracellular volume measurements, T1 mapping should be performed prior to contrast and at least 1 time point between 10 and 30 min post contrast bolus
   h. The hematocrit should be measured, ideally within 24 h of imaging, for the most accurate extracellular volume fraction (ECV) measurement.

T2 mapping and T2-weighted (T2w) imaging
   a. Mapping - if quantitation is desired and sequence is available
      i. Multiple alternatives exist, such as T2-prepared single-shot bSSFP sequence acquired with different T2 prep time, gradient and spin echo (GraSE) or FSE-based pulse sequences.
      ii. Motion correction as needed
      iii. Slice thickness: 6-8 mm, in plane-resolution ~ 1.6–2.0 mm
      iv. The number and orientation of slices obtained will depend upon the indication. Short-axis maps should always be obtained.
   b. T2w Imaging
      i. Black blood T2w short Tau inversion recovery (STIR)
         1. Potential pitfalls – bright signal in areas of low flow, signal dropout due to motion, and low signal in regions with intramyocardial hemorrhage.
      ii. Bright blood T2w sequences
         1. T2-prepared single-shot bSSFP sequence
         2. FSE-bSSFP hybrid is an alternative
         3. Potential pitfall – bright signal may obscure endocardial border

Kramer C et al. JCMR 2020; 22: 17

Parametric Mapping

Description

1. **Scout imaging** as per LV function
2. Appropriate **vendor recommended** optimum T1-mapping sequence (e.g. MOLLI/ShMOLLI/SASHA etc.)
3. SA images - single mid-ventricular slice or 3 slices planned using **"3 of 5" technique**
4. **Gadolinium injection** (0.1 – 0.2mmol/kg)
5. Wait **at least 15 min** post contrast injection to acquire **post-contrast T1**
6. Take full blood count for haematocrit to calculate **extracellular volume (ECV)**

4. **FOV and voxel size should not be changed** between pre/post contrast T1 acquisition to allow generation of ECV maps

Tips & Tricks

1. Acquire **one slice per breath hold**
2. Native T1 values are reproducible but **they vary by magnet strength** (with 3T resulting in longer native T1 times)**, vendor platforms and the mapping sequence**
3. Check scanner generated native T1 map for **breathing artefact.** Consider changing voxel size, fold-over or adding SENSE to reduce breath-hold
4. **FOV and voxel size should not be changed** between pre/post contrast T1 acquisition to allow generation of ECV maps

Parametric Mapping

Native T_1 ↑	Native T_1 ↓
• *Oedema* e.g. tissue water↑ in AMI, inflammation, pericardial effusion	• *Fat/Lipid overload* e.g. lipomatous metaplasia in chronic MI, Anderson-Fabry, lipoma
• *Increase of interstitial space* (replacement) fibrosis, scar, cardiomyopathy, amyloid deposition	• *Iron overload*

T_2 ↑	T_2 ↓
• *Oedema* e.g. tissue water↑ in AMI, inflammation, pericardial effusion (T_2 more sensitive than native T_1 for oedema detection)	• *Fat/Lipid overload* • *Iron overload* (T_2*↓)

Herzog BA et al. EACVI ESC CMR Pocket Guide v2.0.2017

Parametric Mapping

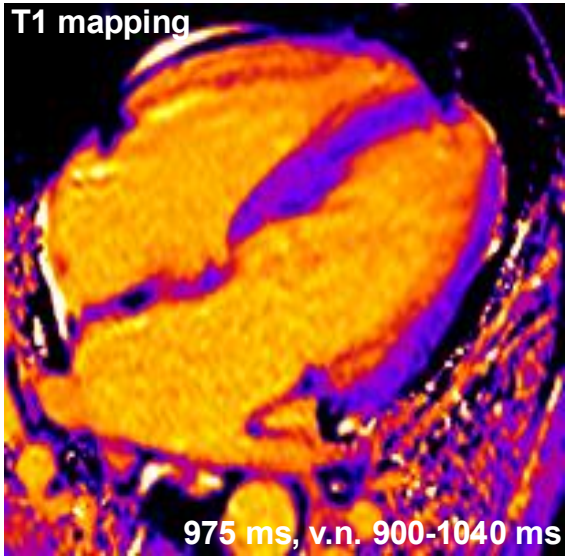



NORMAL

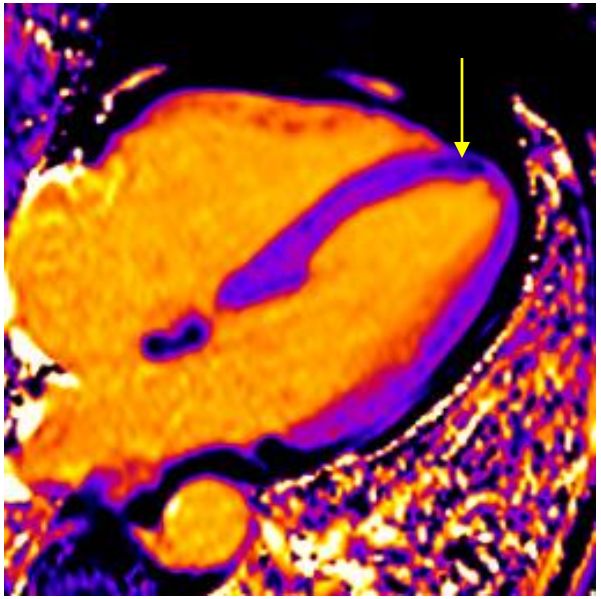

FAT METAPLASIA

Parametric Mapping

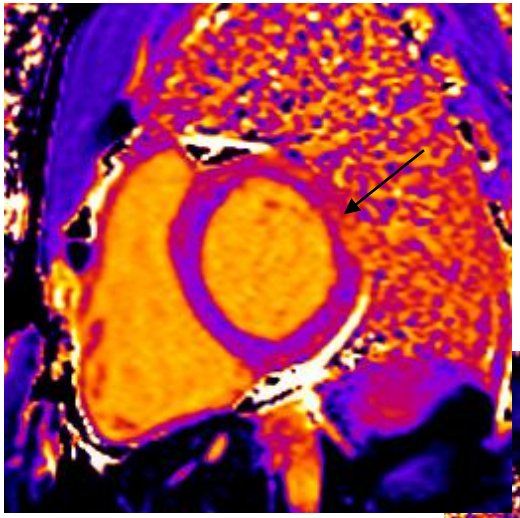

T1 MAPPING

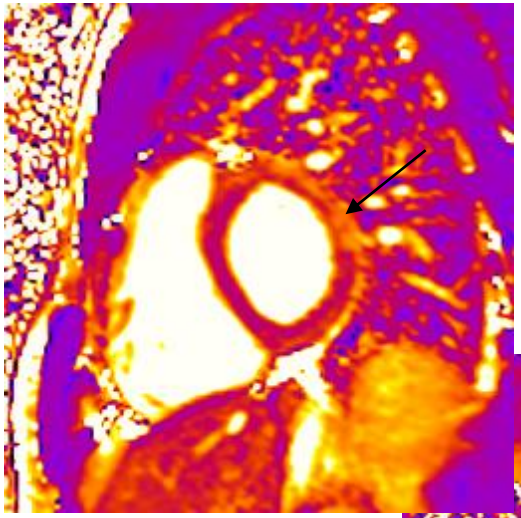

T2 MAPPING

ACUTE MYOCARDITIS

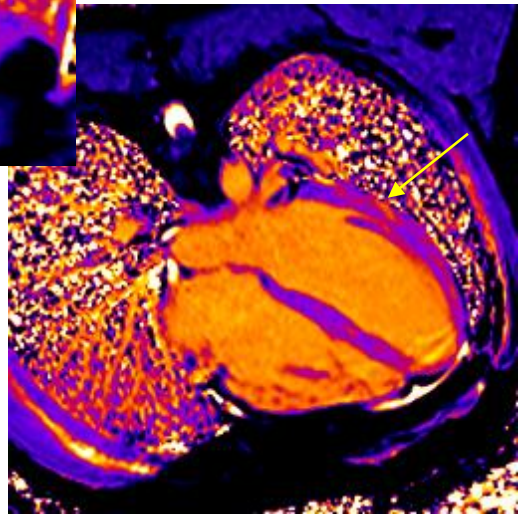

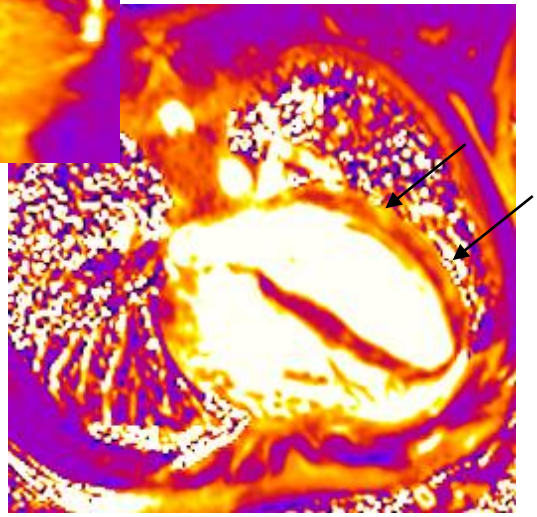

Study Protocols

ISCHEMIC HEART DISEASE

- Localisers

Study Protocols

ISCHEMIC HEART DISEASE

- Localisers
- Cine sequences (bSSFP)

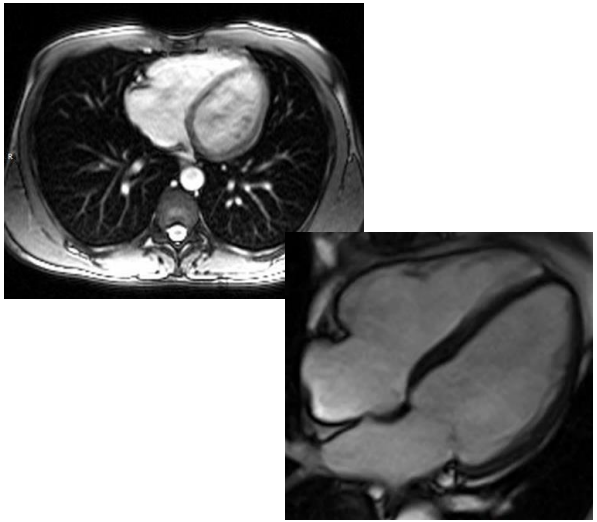

Study Protocols

ISCHEMIC HEART DISEASE

- Localisers
- Cine sequences (bSSFP)
- T2-weighted images
- Parametric mapping
- Rest/stress perfusion

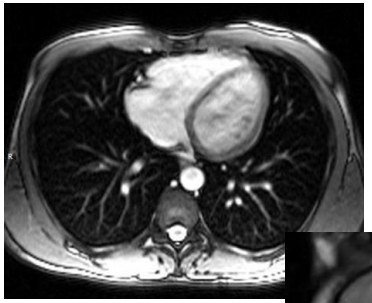

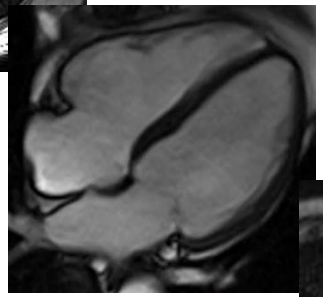

ACUTE MI - ACS

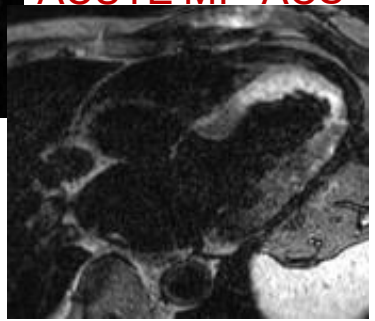

Study Protocols

ISCHEMIC HEART DISEASE

- Localisers
- Cine sequences (bSSFP)
- T2-weighted images
- Parametric mapping
- Rest/stress perfusion
- LGE

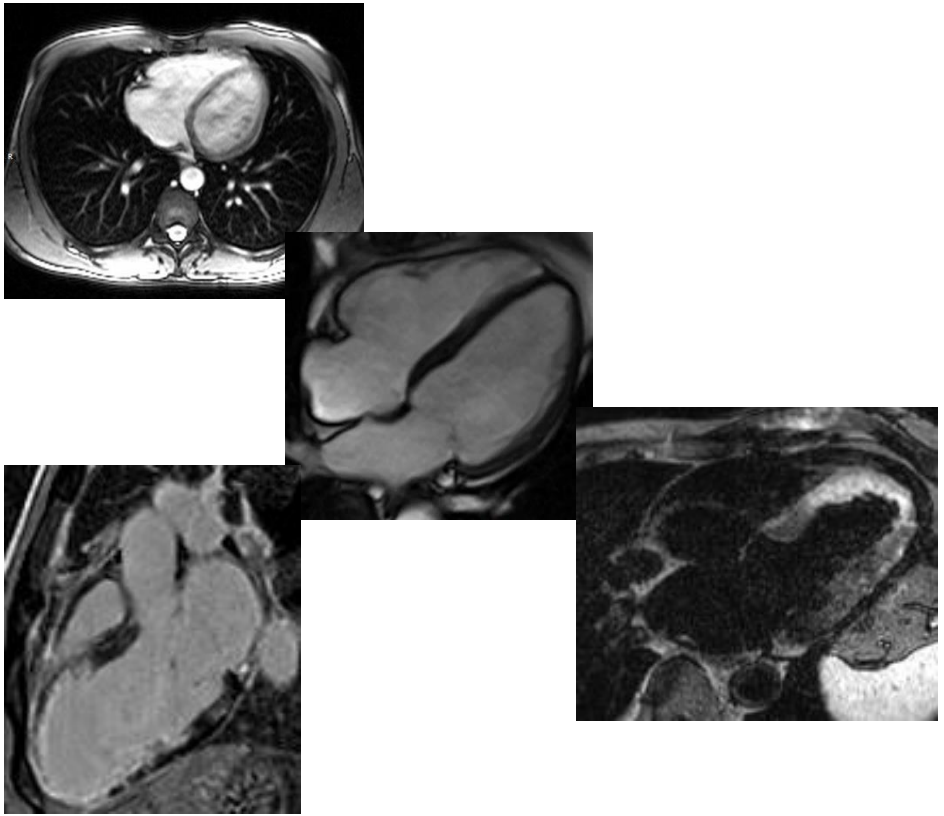

Study Protocols

NON-ISCHEMIC HEART DISEASE

- Localisers

Study Protocols

NON-ISCHEMIC HEART DISEASE

- Localisers
- Cine sequences (bSSFP)

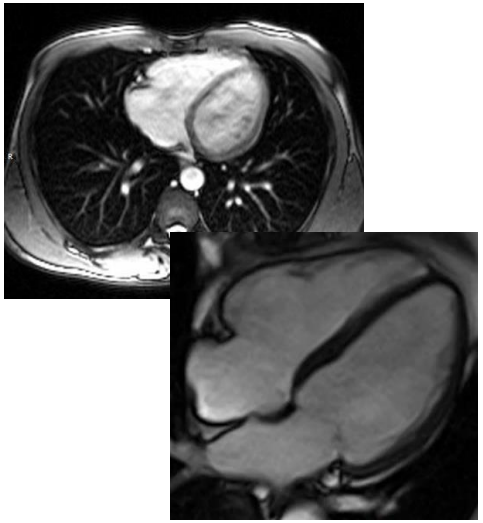

Study Protocols

NON-ISCHEMIC HEART DISEASE

- Localisers
- Cine sequences (bSSFP)
- (Advanced) tissue characterization

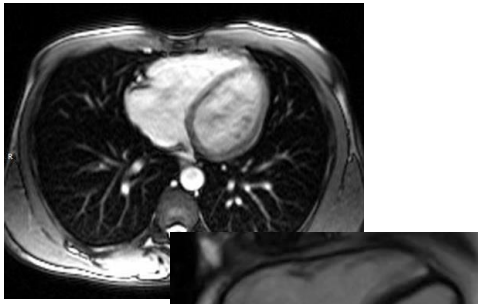

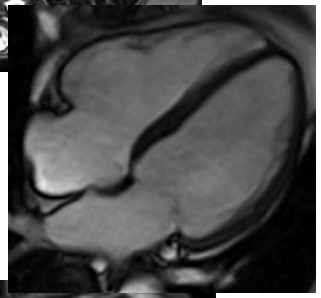

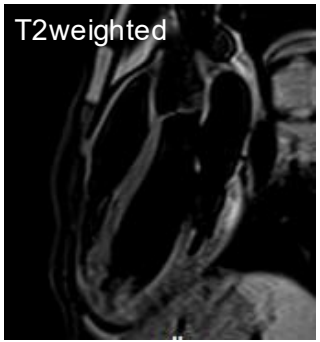

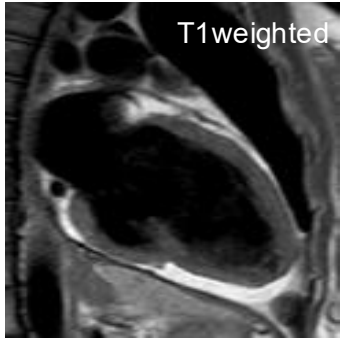

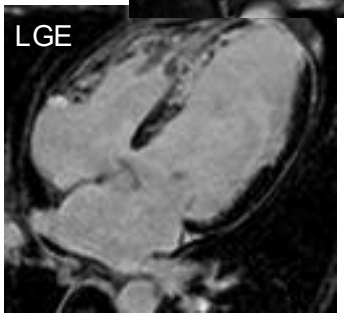

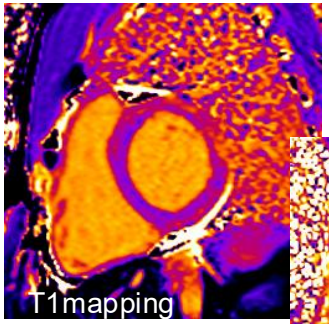

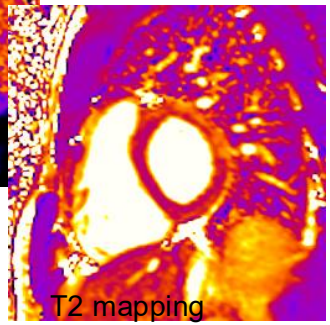

Study Protocols

NON-ISCHEMIC HEART DISEASE

- Localisers
- Cine sequences (bSSFP)
- (Advanced) tissue characterization
- Rest perfusion

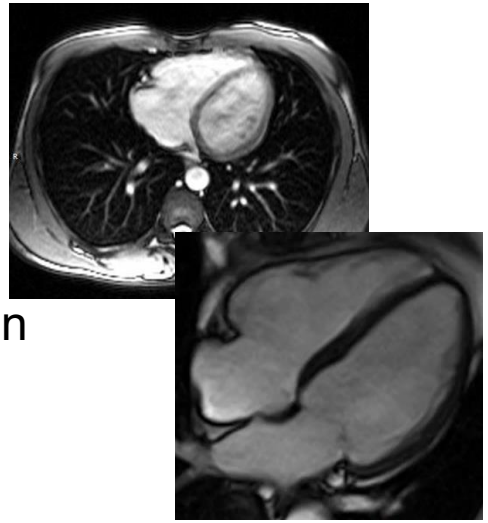

Study Protocols

NON-ISCHEMIC HEART DISEASE

- Localisers
- Cine sequences (bSSFP)
- (Advanced) tissue characterization
- Rest perfusion
- Velocity encoded imaging

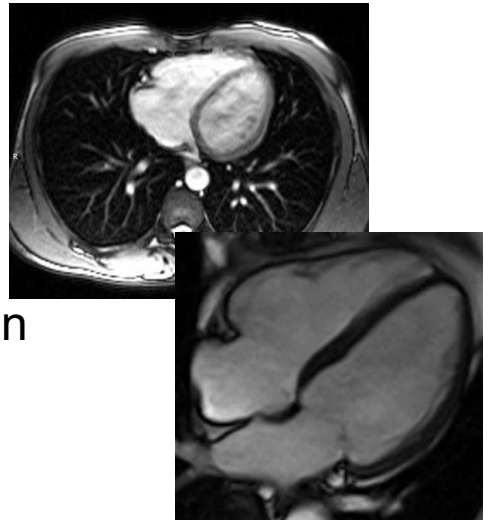



Conclusions

- Multi-planar and multi-parametric assessment
- Anatomical, morphological and functional characterization
- Tailored sequences and protocols

UNIVERSITÀ
DEGLI STUDI
DI PADOVA